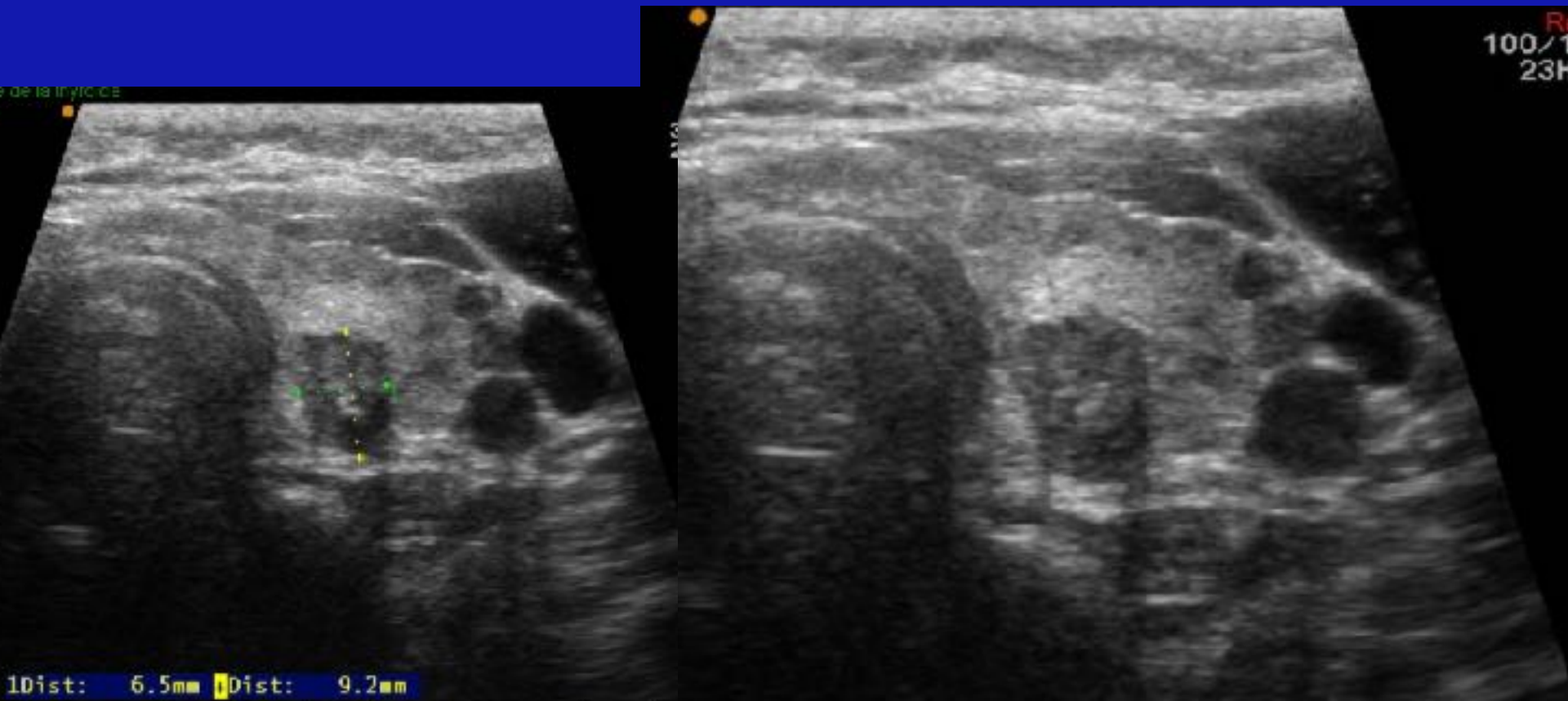


ECHOGRAPHIE SYSTEMATIQUE DANS LE CADRE DE BILAN DON DE REIN

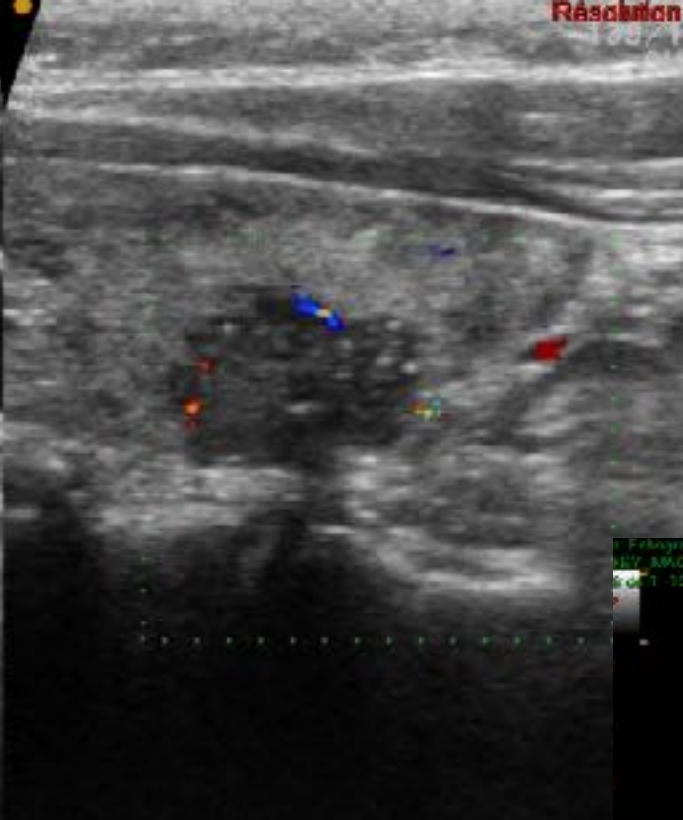
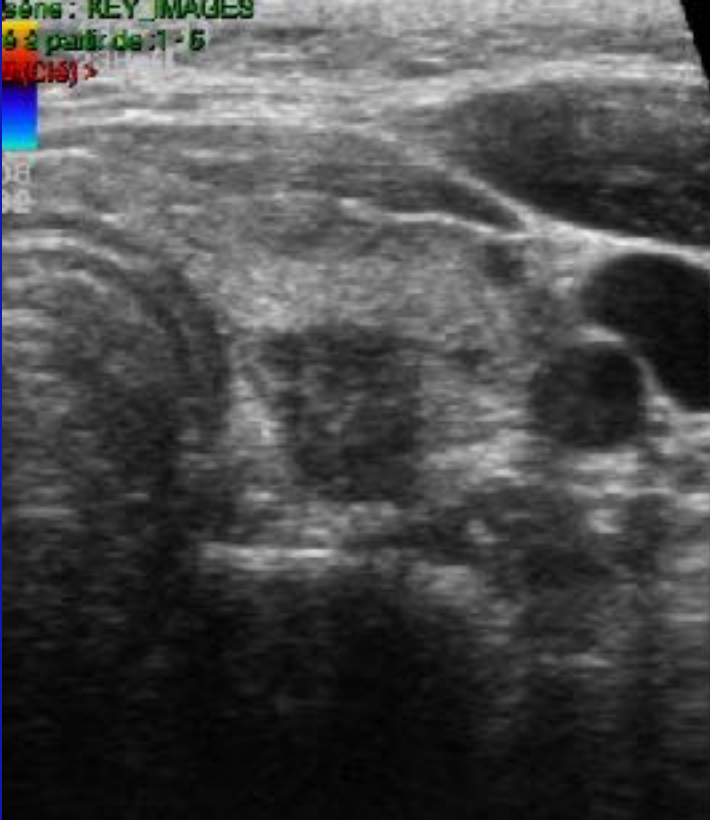
Nodule infra cm GAUCHE : Cytoponction (?) = papillaire

Adressé pour Avis : Quelle attitude ?

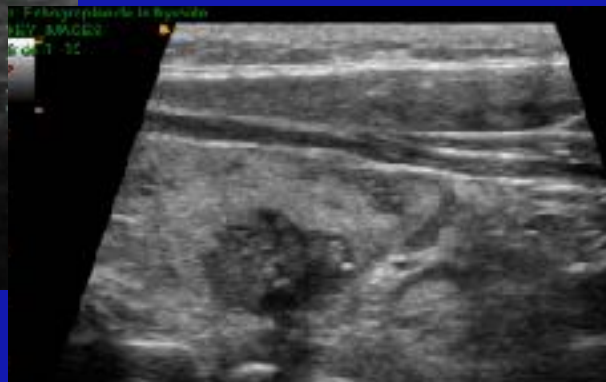
- DON de REIN Puis Prise en charge du CANCER de la Thyroïde
- Prise en charge du CANCER de la thyroïde puis DON de REIN



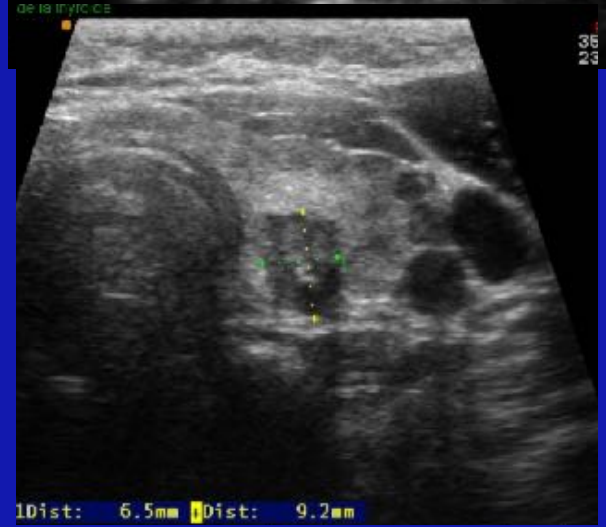sons: KEY_IMAGES
à 3 partir de: 1 - 5
(CIS) >



Résolution



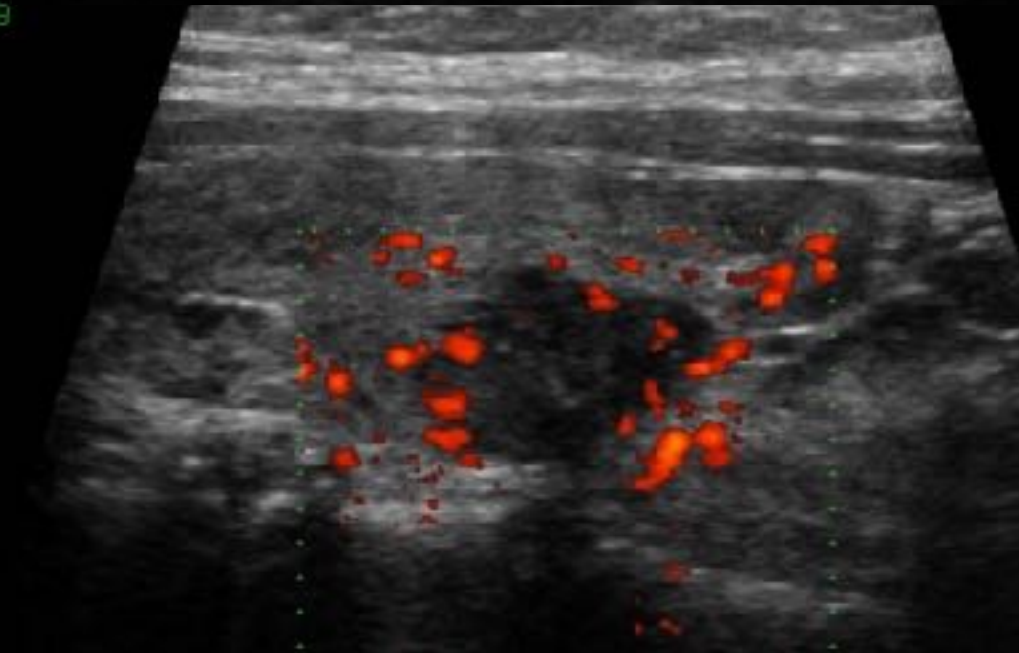
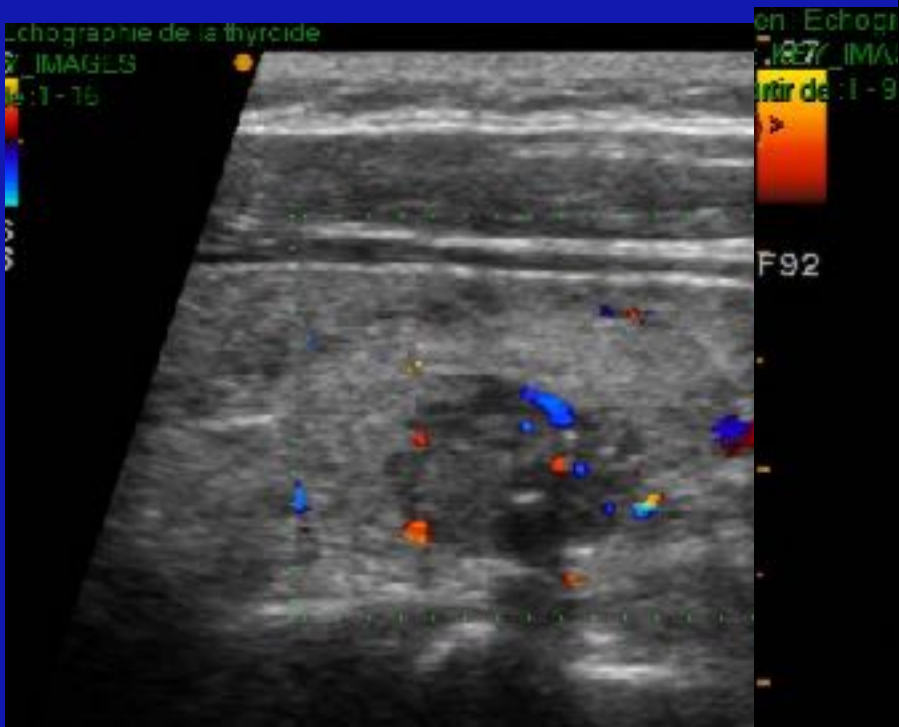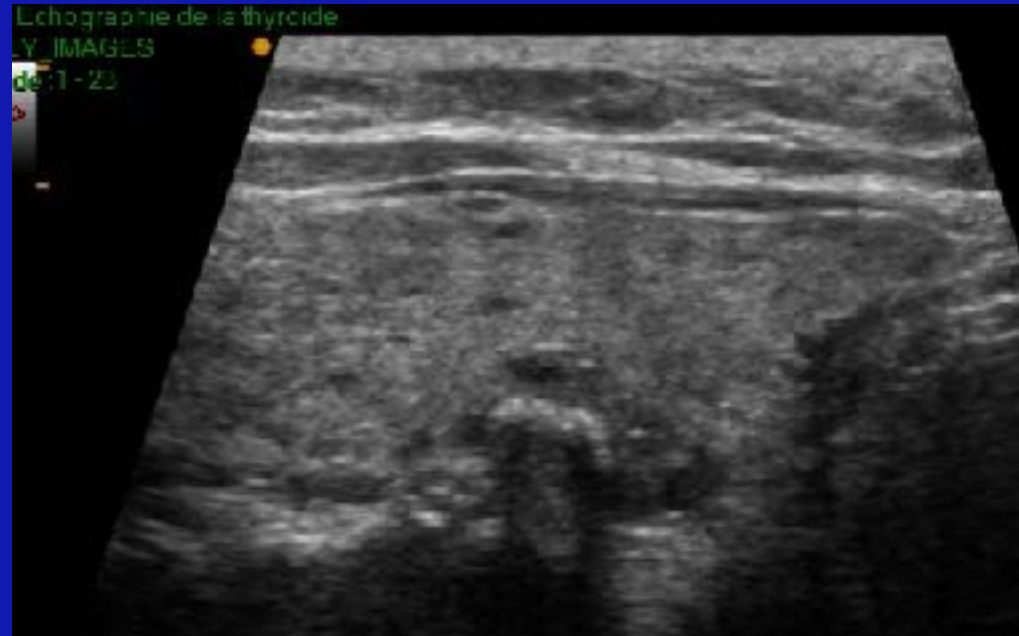
Félicitations à l'équipe
KEY_IMAGES
2021-12



10Dist: 6.5mm Dist: 9.2mm

VASCULARISATION/ MACROCALCIFICATION CENTRALE

ELASTOGRAPHIE



Examen : Echographie de la thyroïde

100%

Clé : KEY_IMAGES

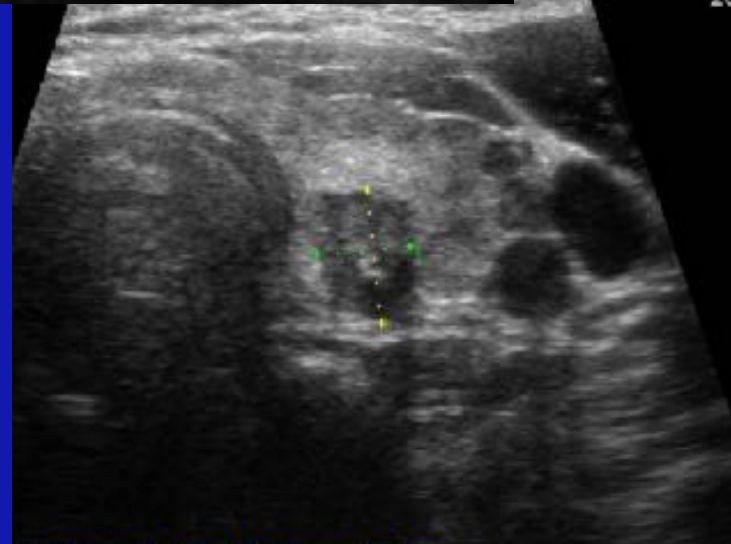
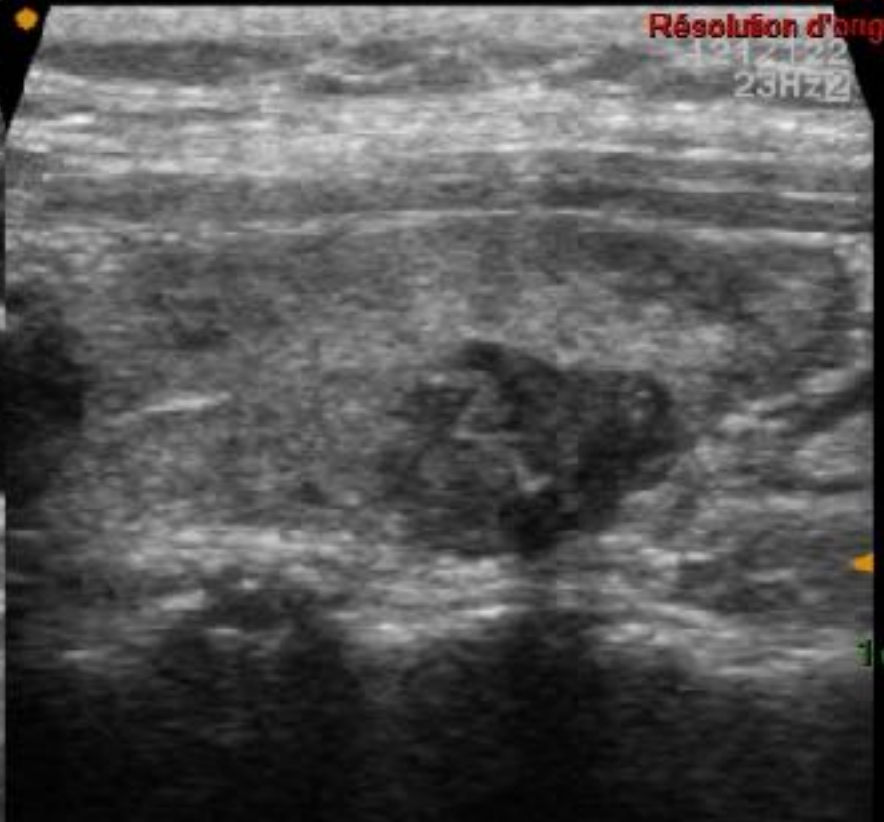
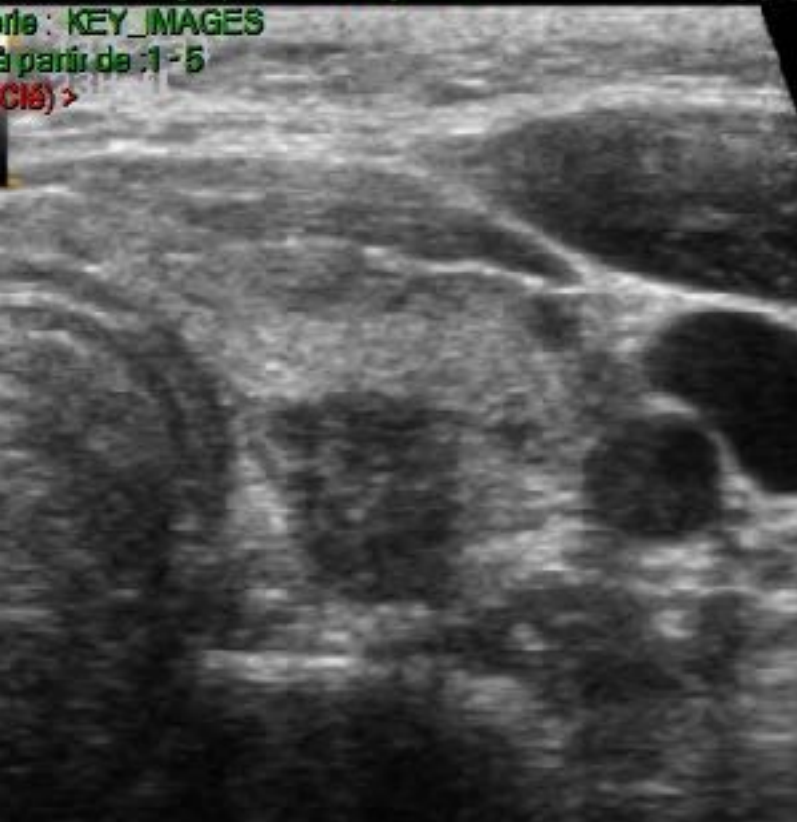
à partir de : 1-5

(C18) >

Résolution d'angle

121-122

23HZ2



Dist: 6.5mm Dist: 9.2mm

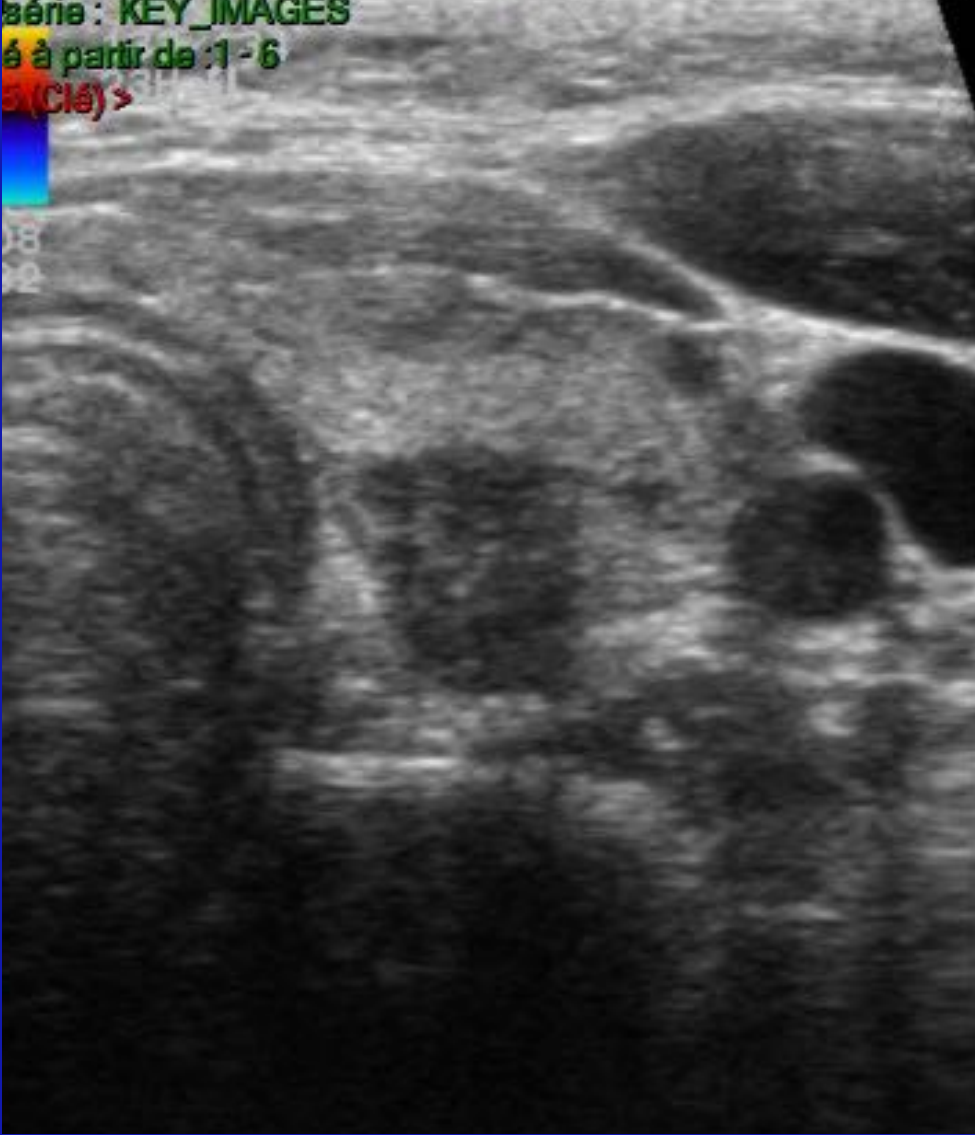
Séance : KEY_IMAGES

à partir de : 1 - 6

5 (Clé) >



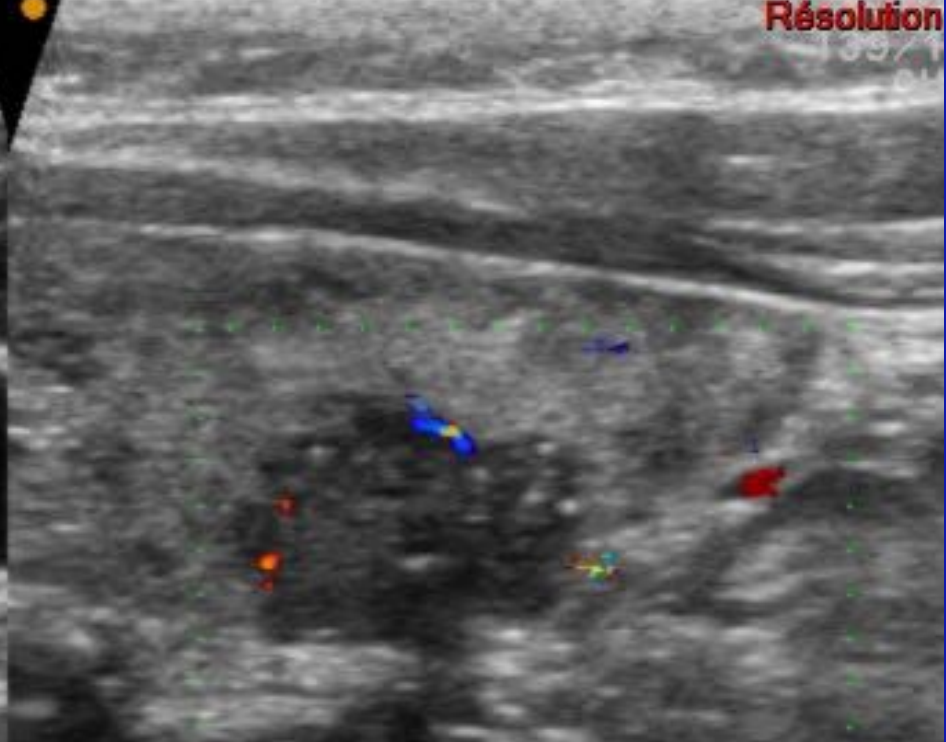
18
12



Résolution

139/1

01

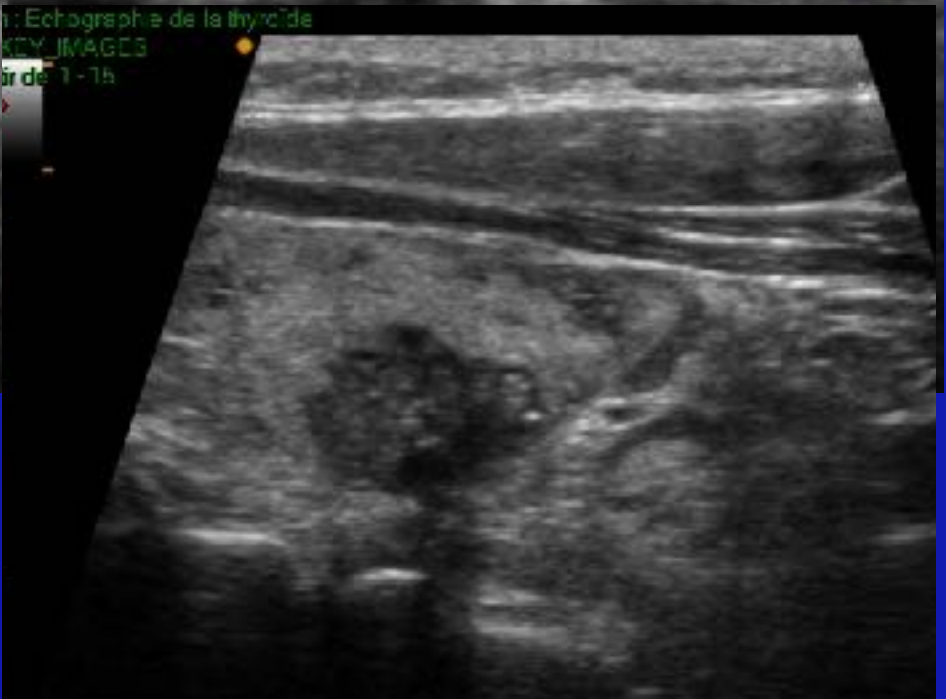


1 : Echographie de la thyroïde

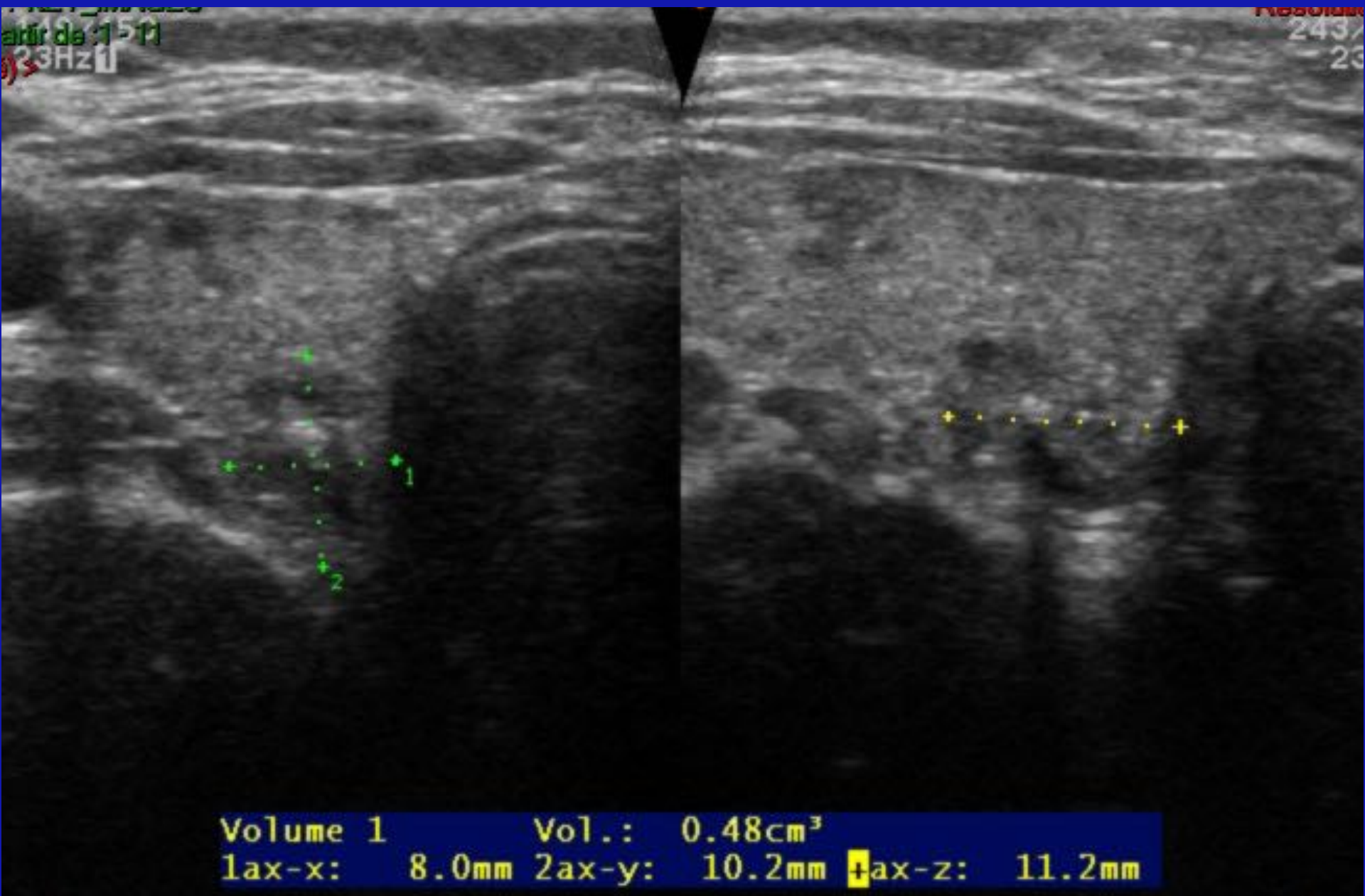
KEY_IMAGES

à partir de : 1 - 15

>

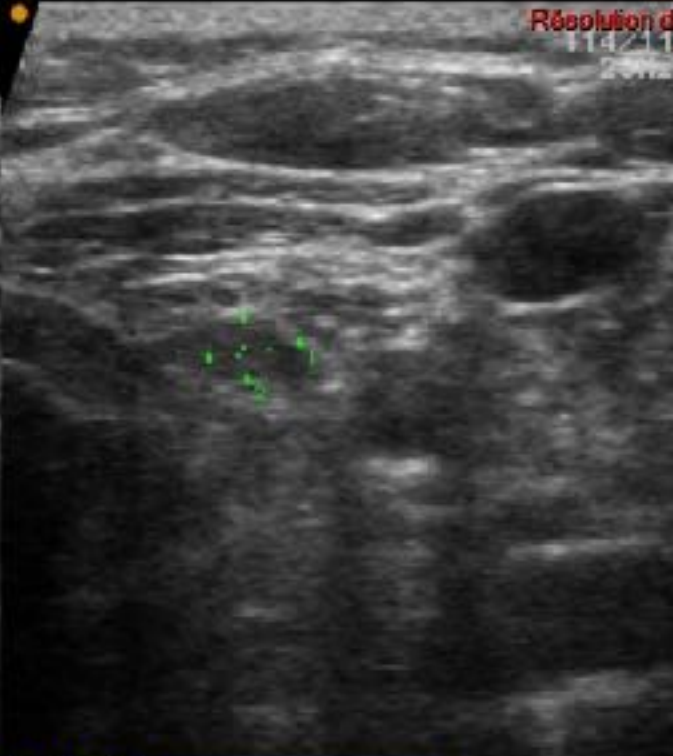
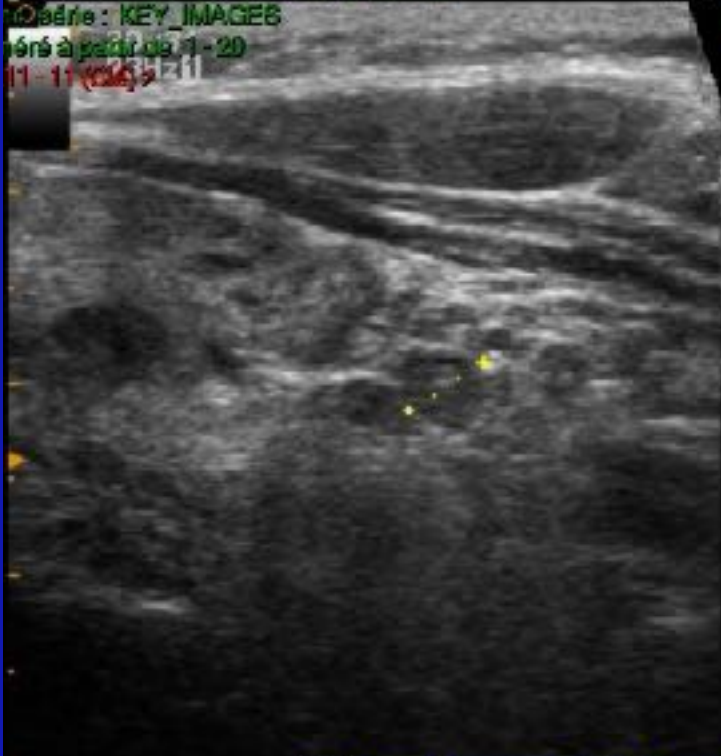


DROITE: bilatéral ?



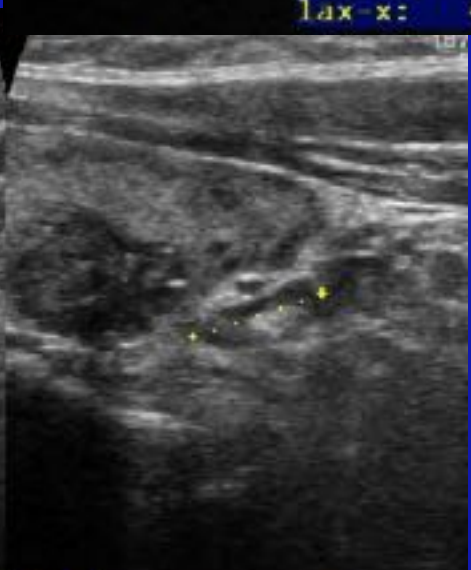
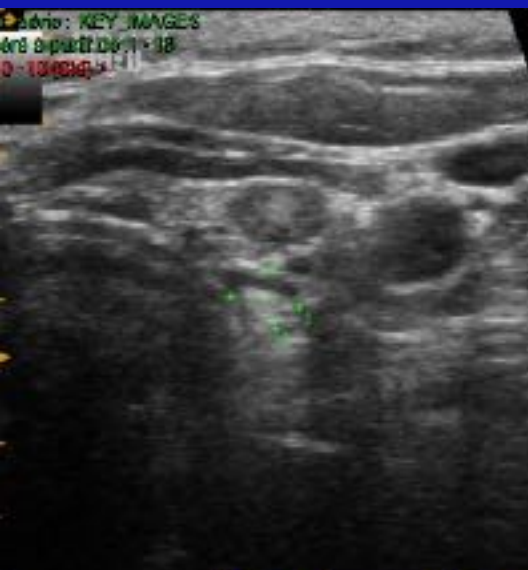
Quadrante : KEY_IMAGES
rés à partir de 1-20
11-11 (2015)

Résolution d
114214
2015



Volume 1 Vol.: 0.04cm³
1ax-x: 4.8mm 2ax-y: 3.2mm 3ax-z: 4.7mm

Quadrante : KEY_IMAGES
rés à partir de 1-18
0-10 (2015)



Volume 1 Vol.: 0.09cm³
1ax-x: 4.8mm 2ax-y: 4.0mm 3ax-z: 9.4mm

Classification T/N(M) THYROÏDE ?

TIRADS ?

Fallait-il ponctionner ce nodule ?

Quel bilan ?