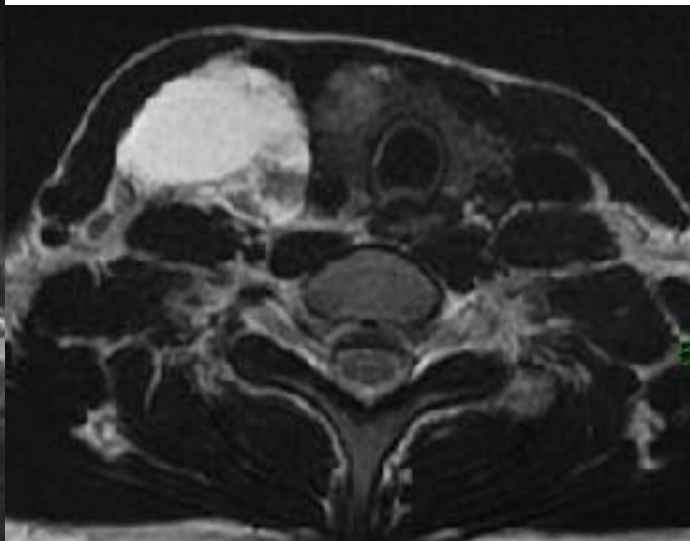
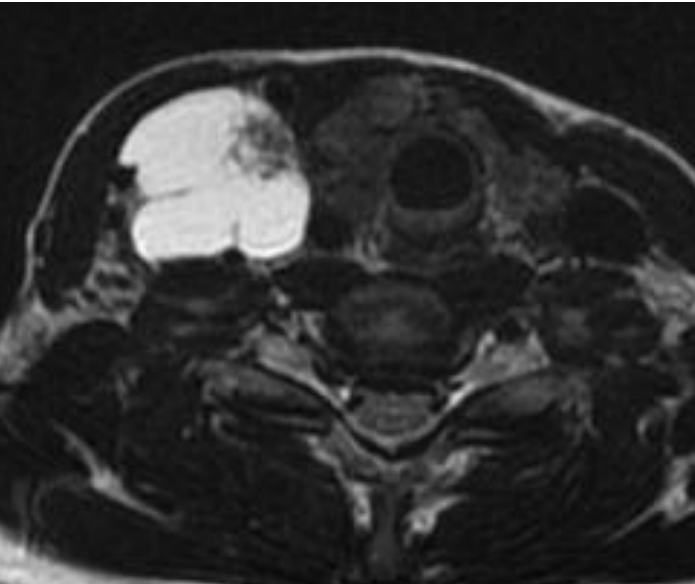
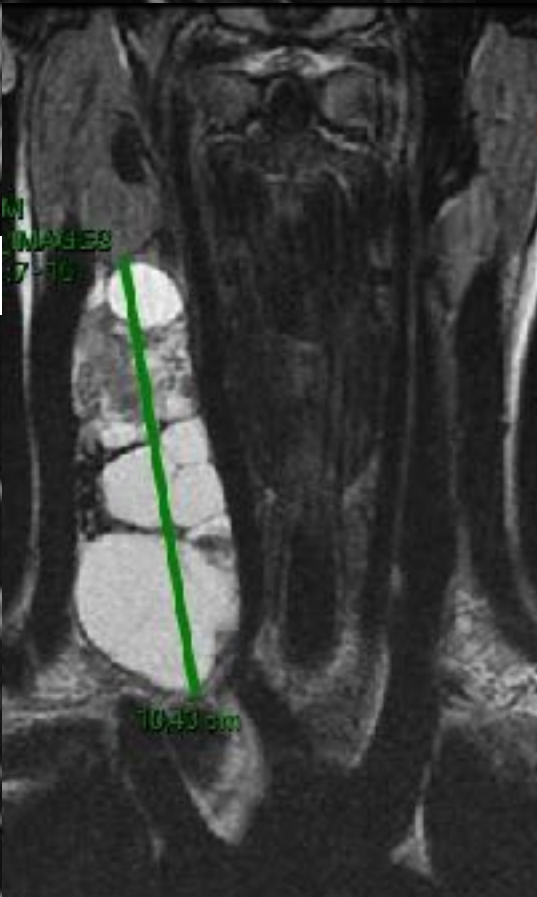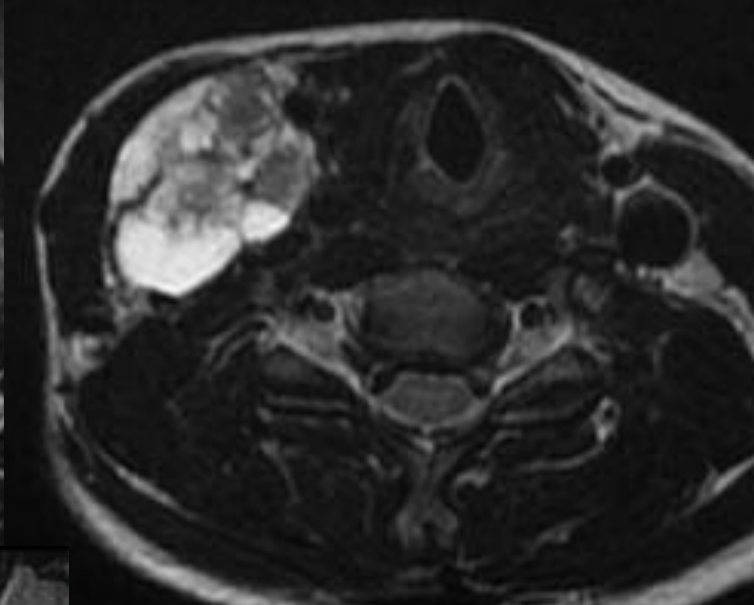
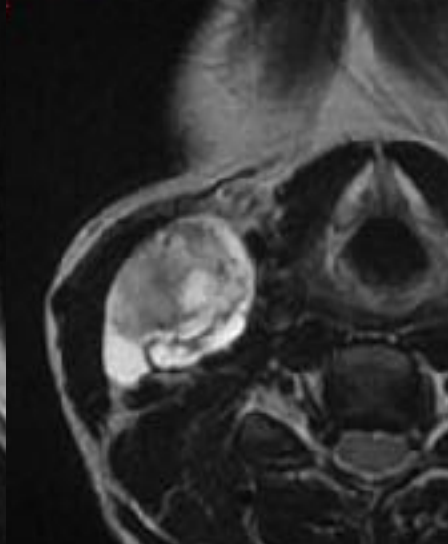
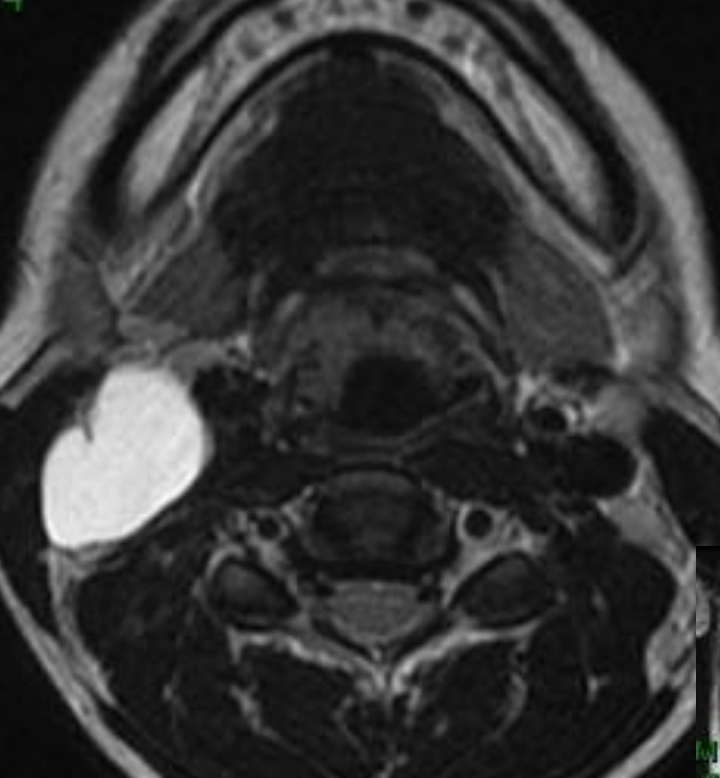
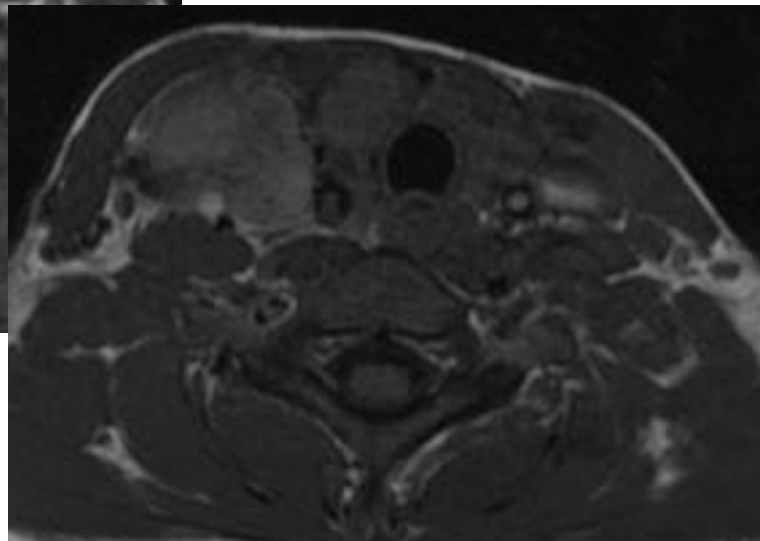
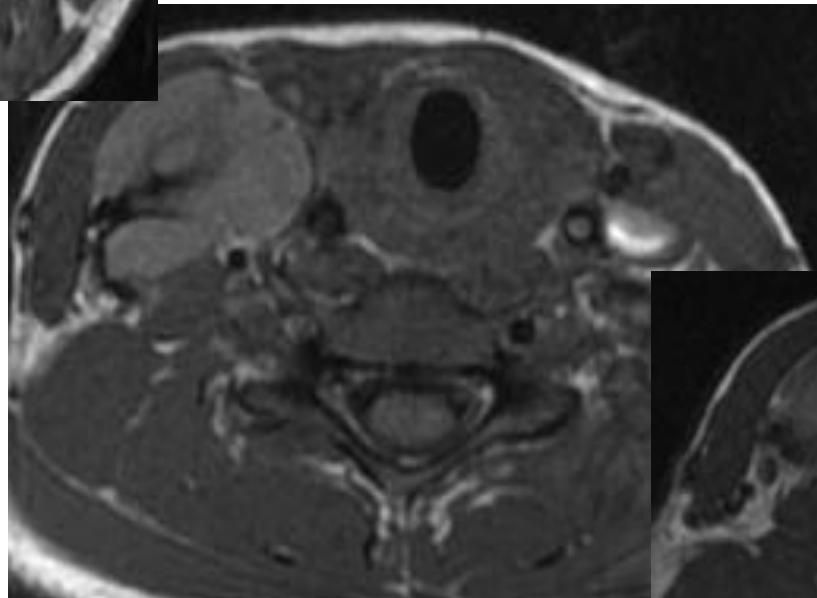
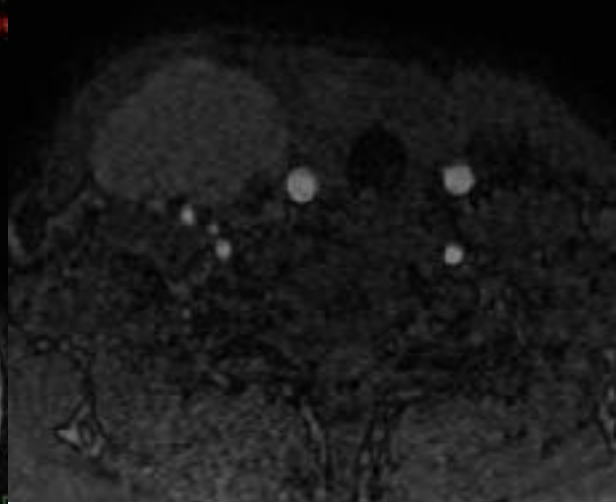
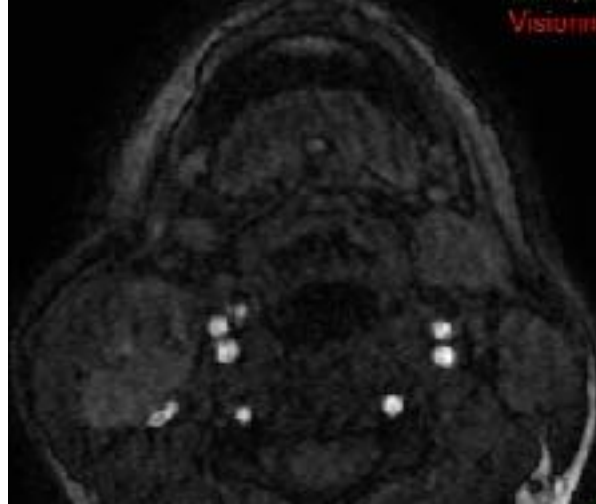
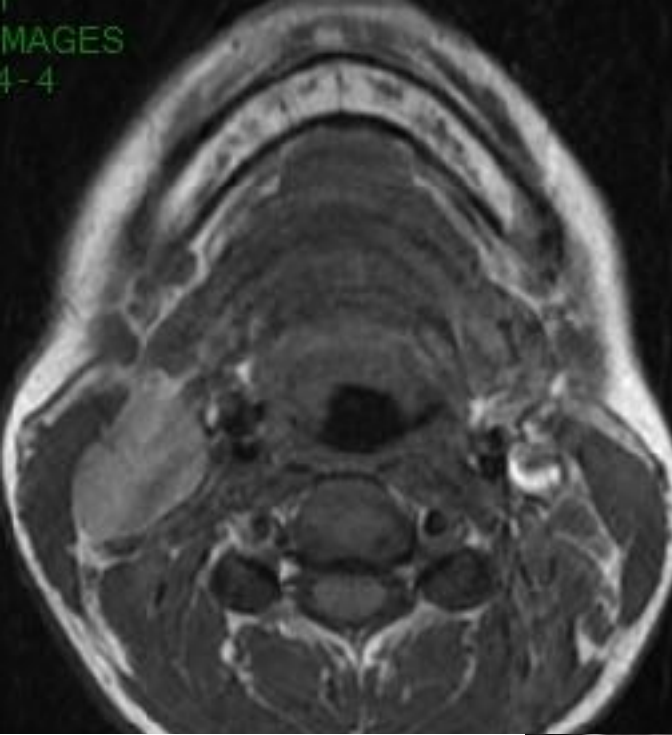
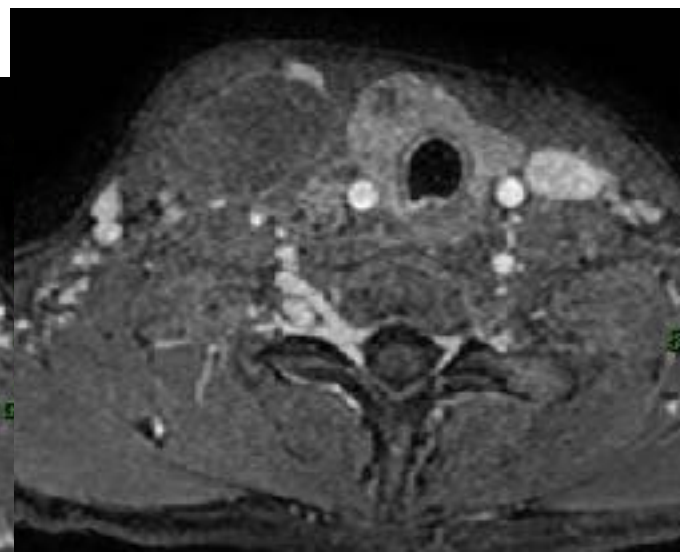
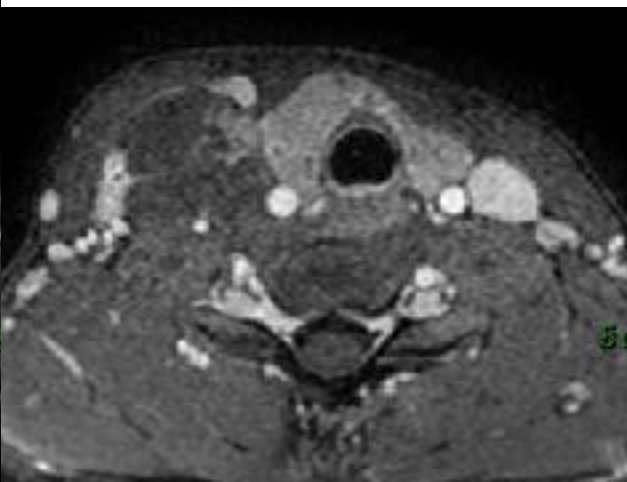
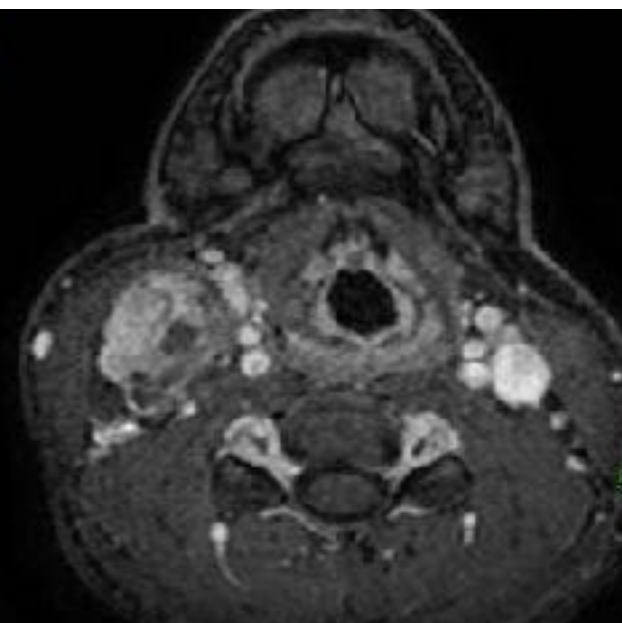
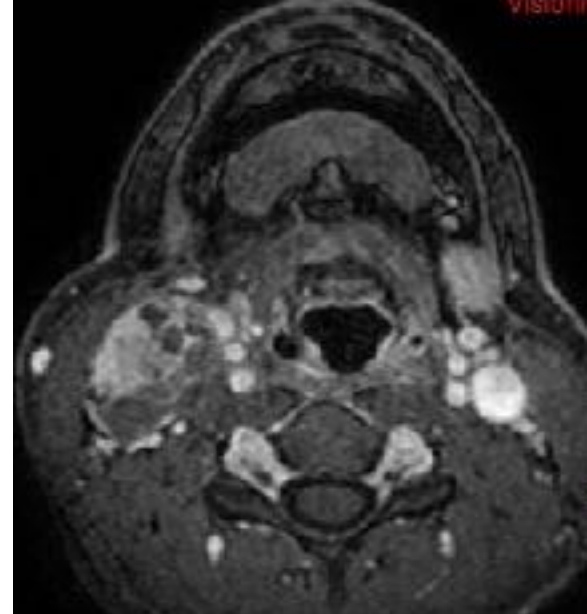
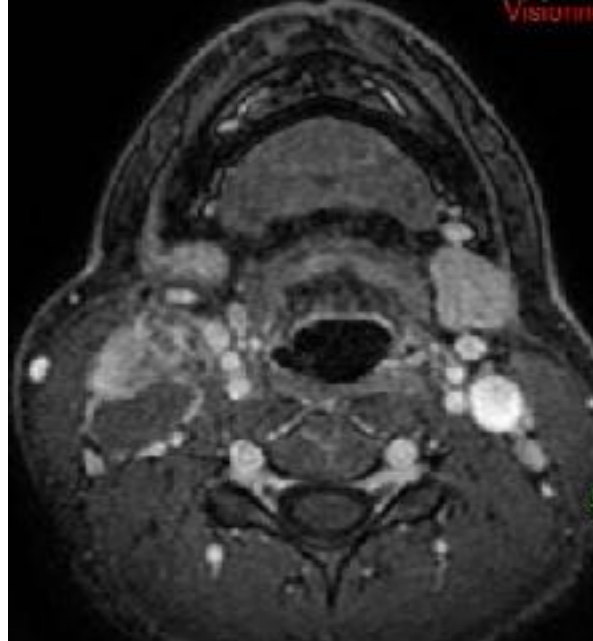
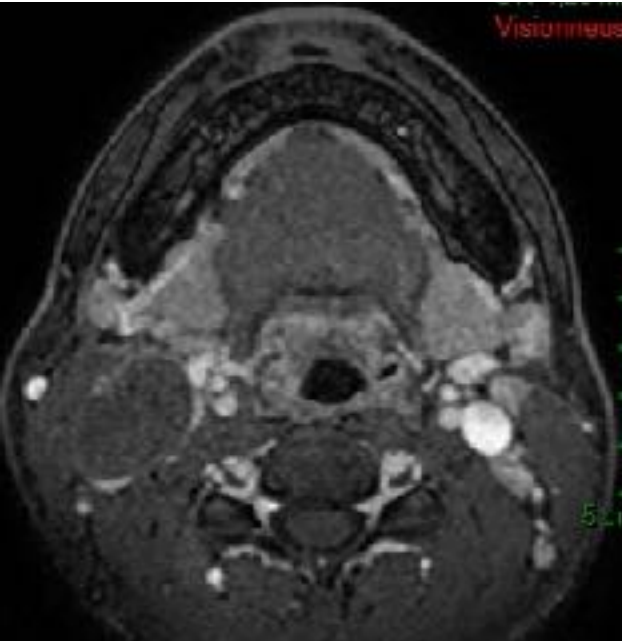


Patiente adressée pour bilan après TDM:

**Masse vascularisée en TDM avec portions kystiques:
Lymphangiome kystique/ malformation veineuse ?**







Hypothèse ?

Que proposez vous ?