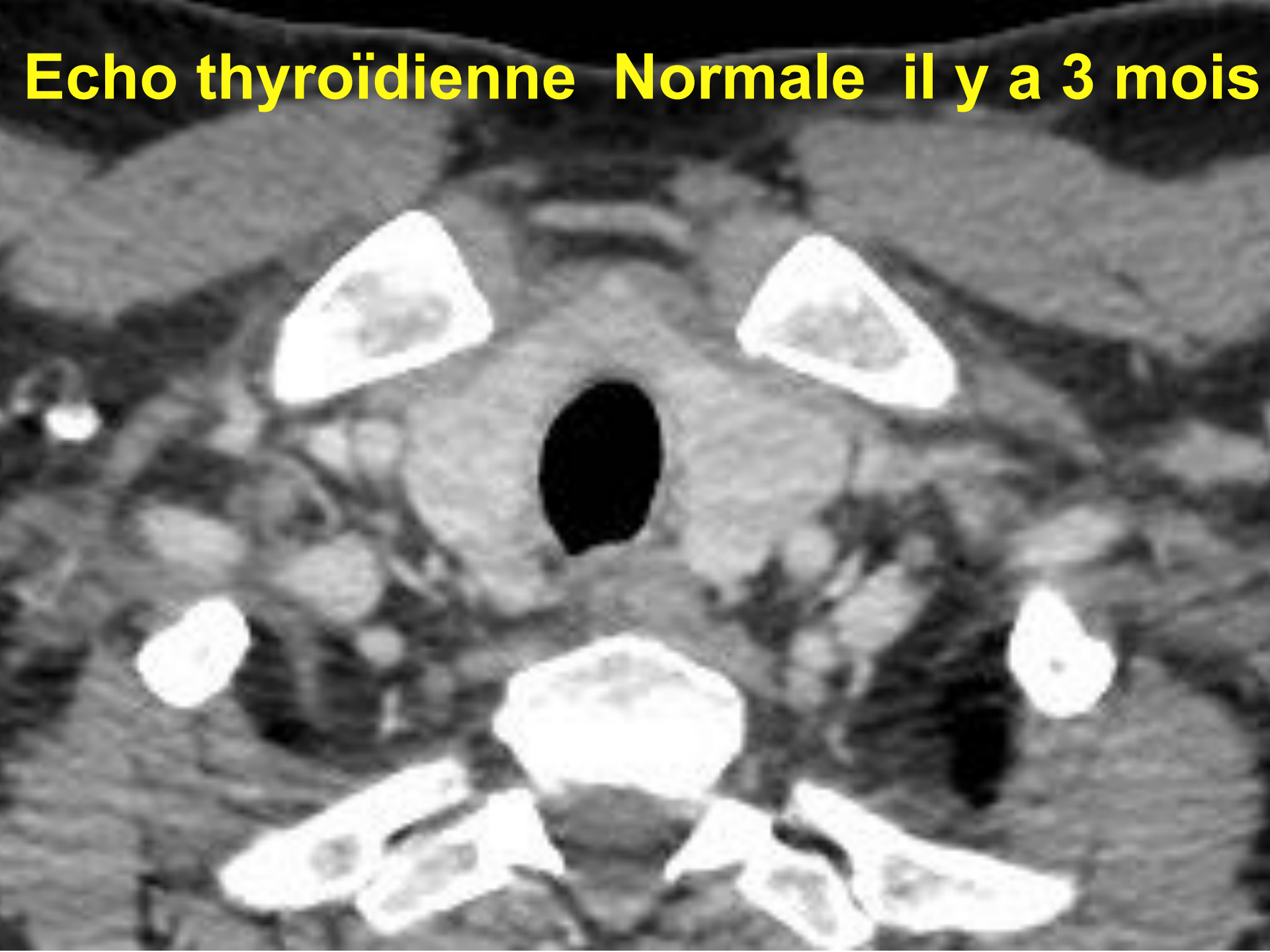
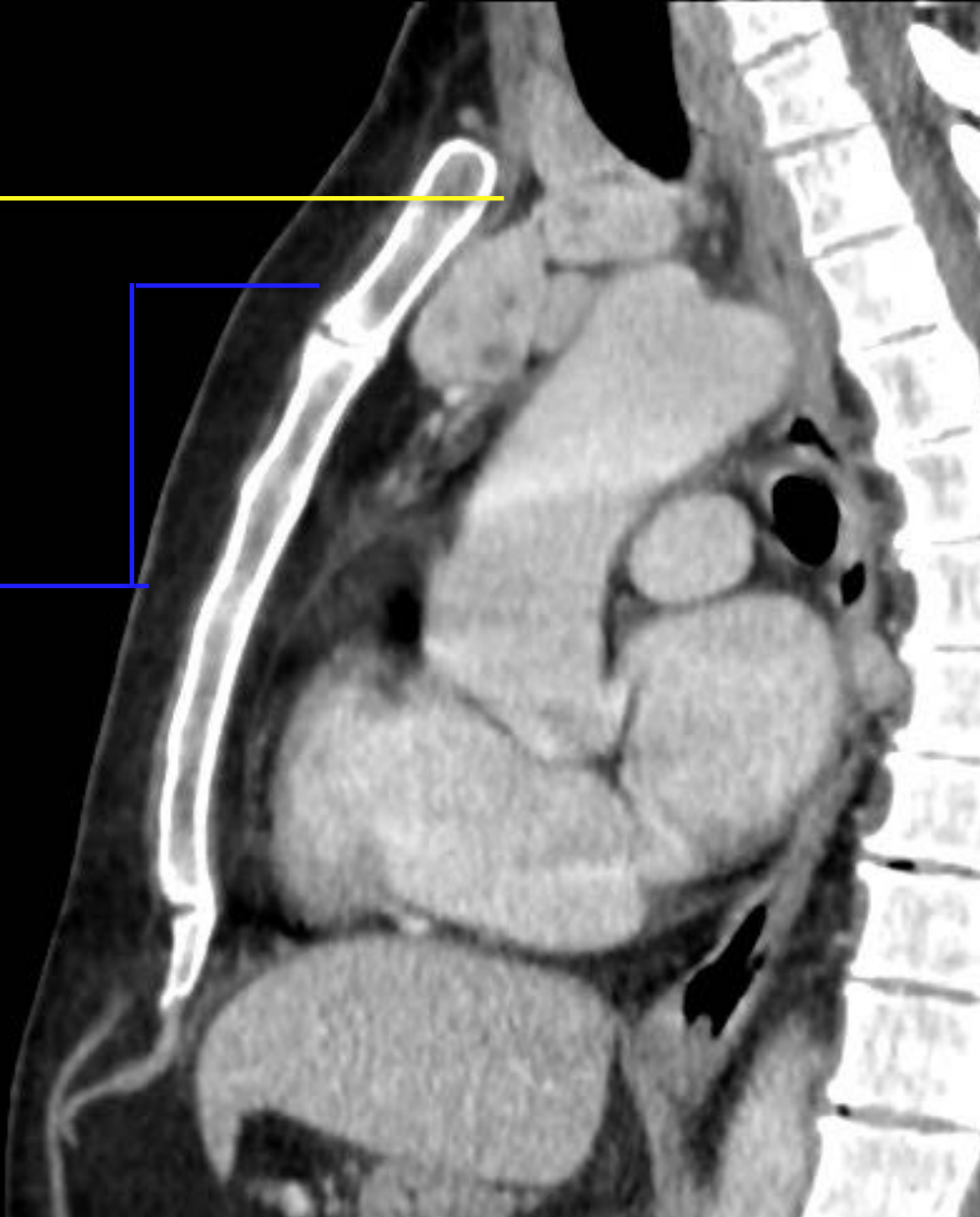
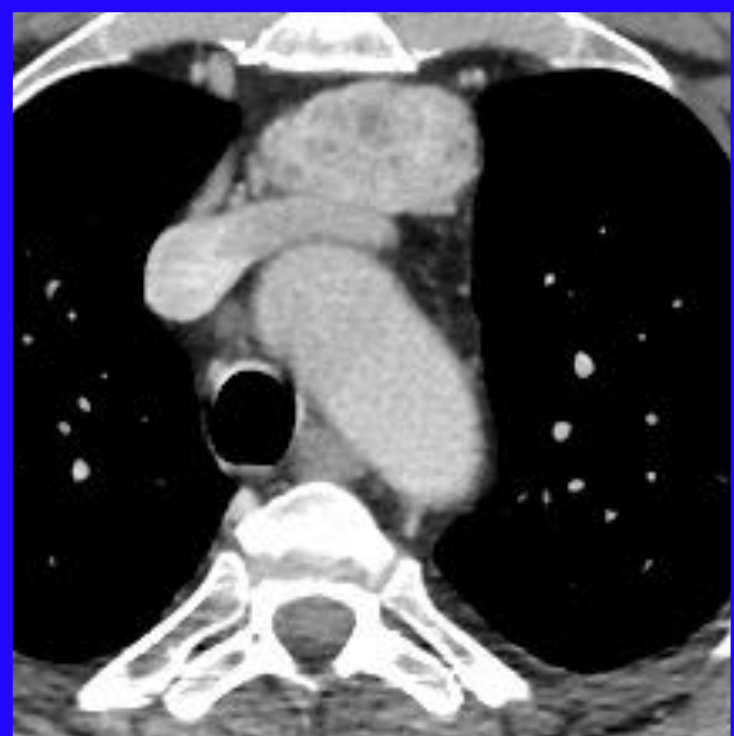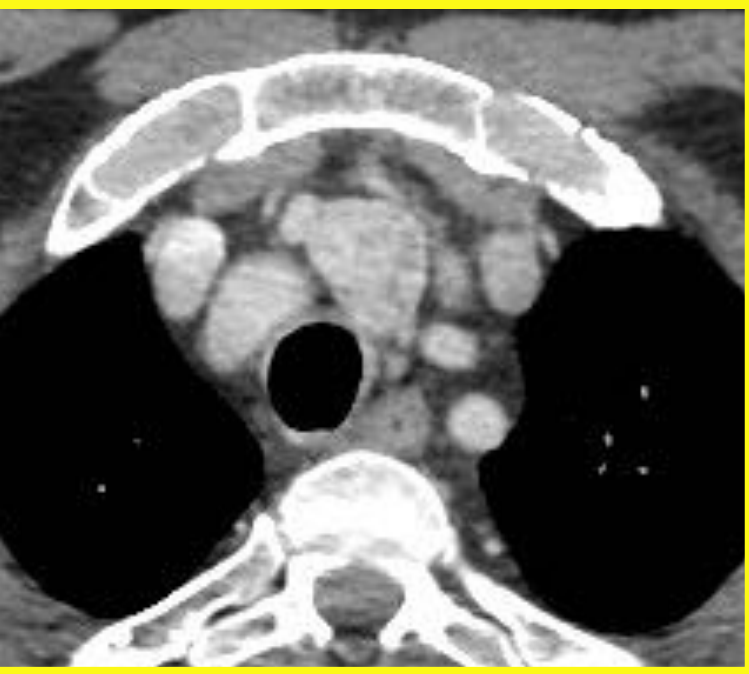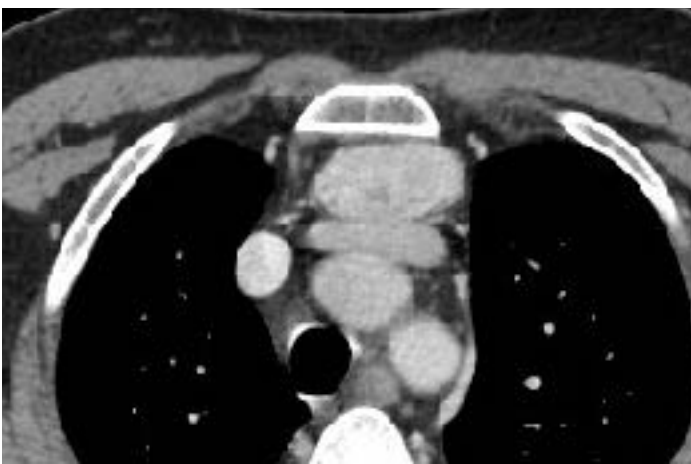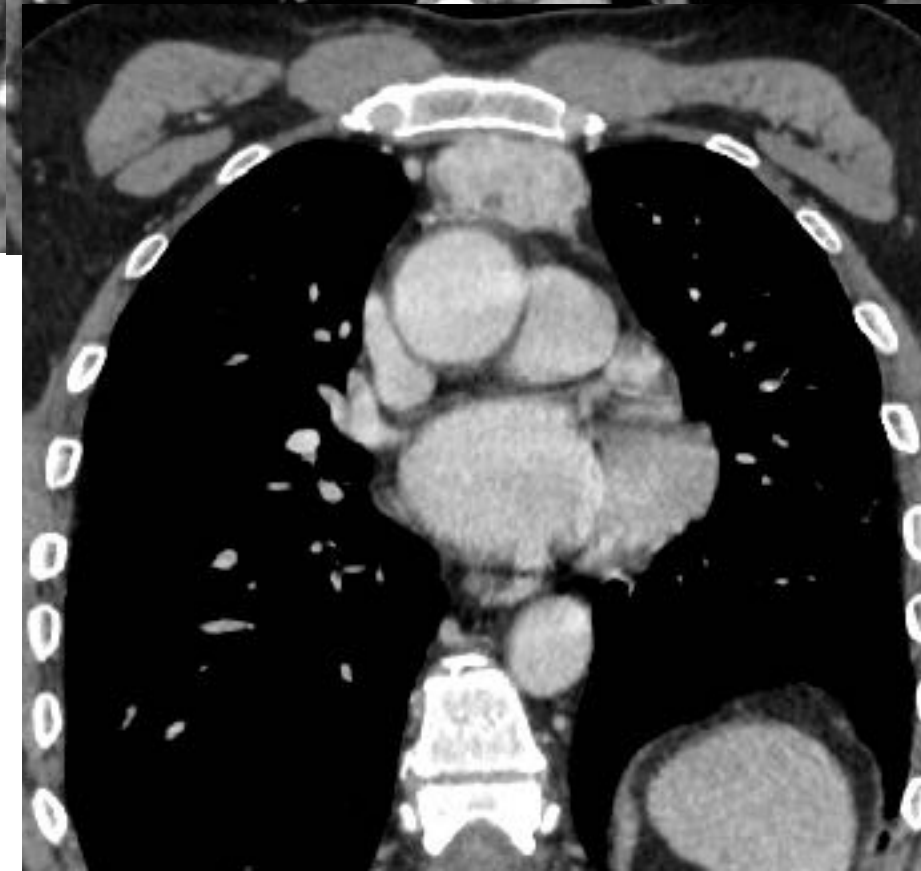
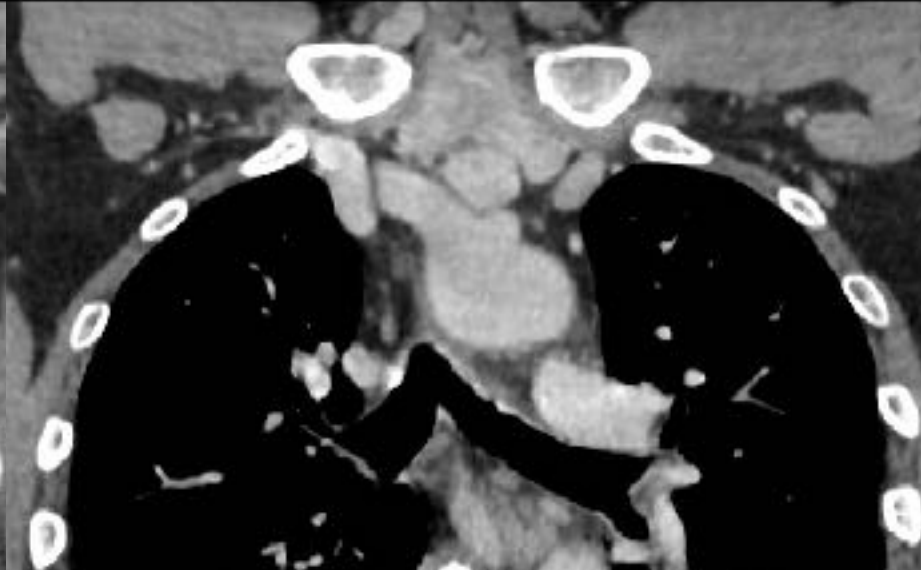
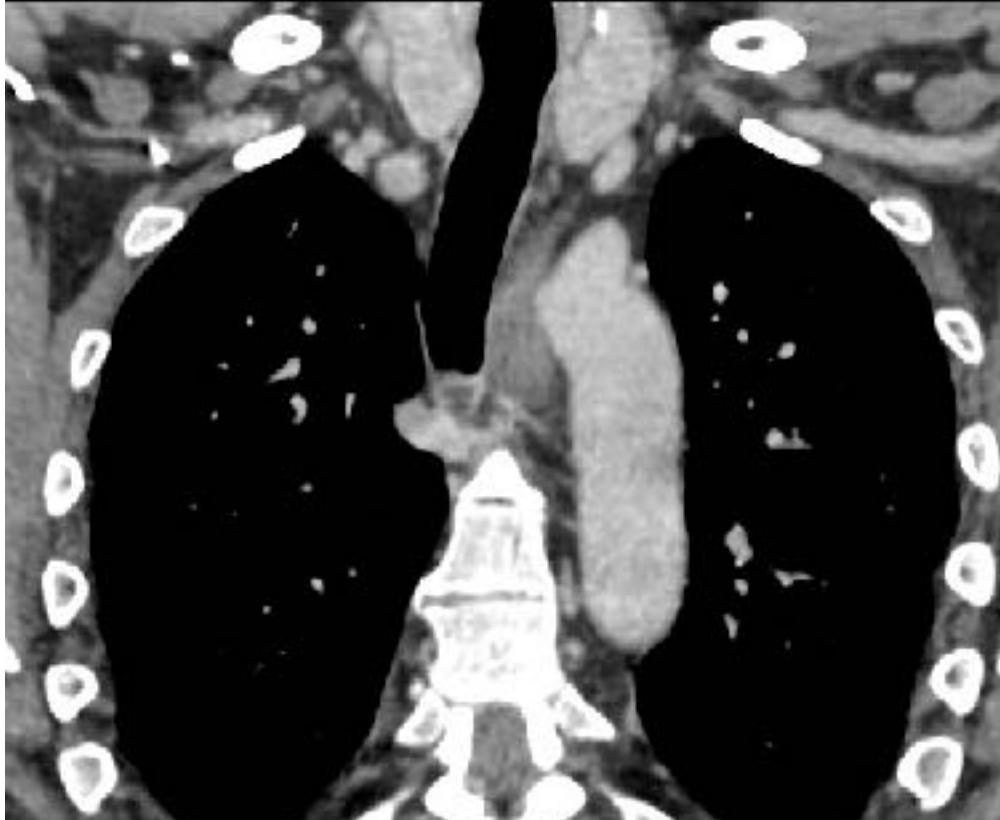


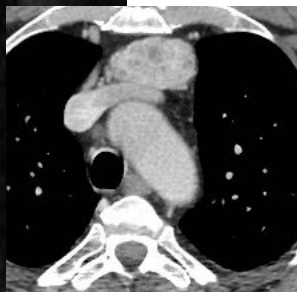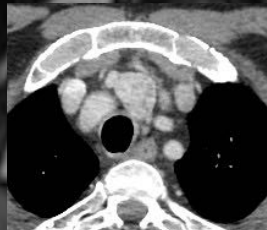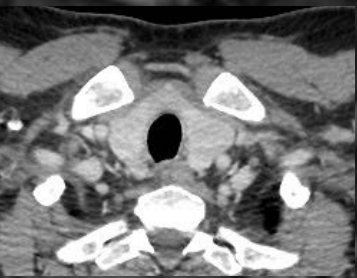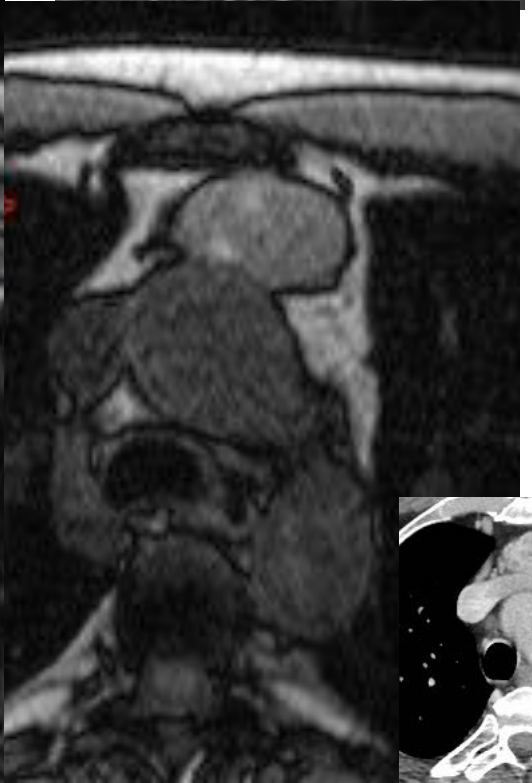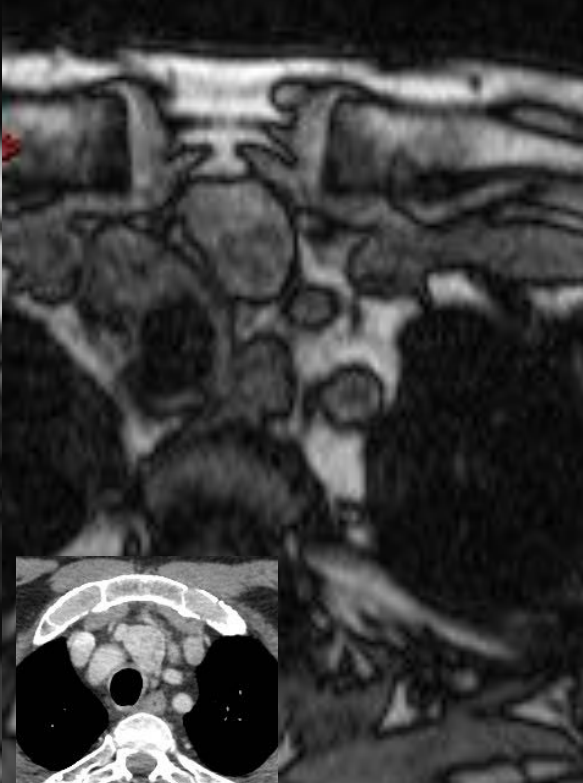
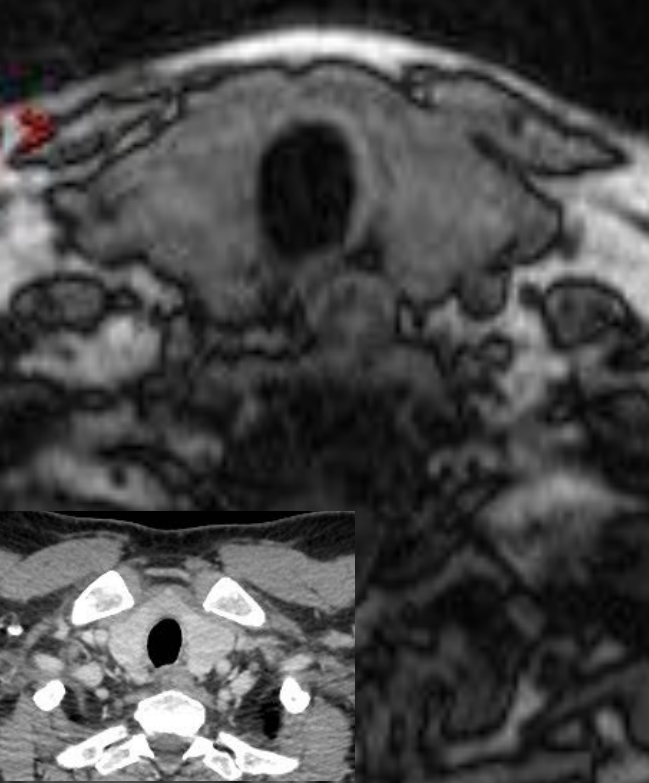
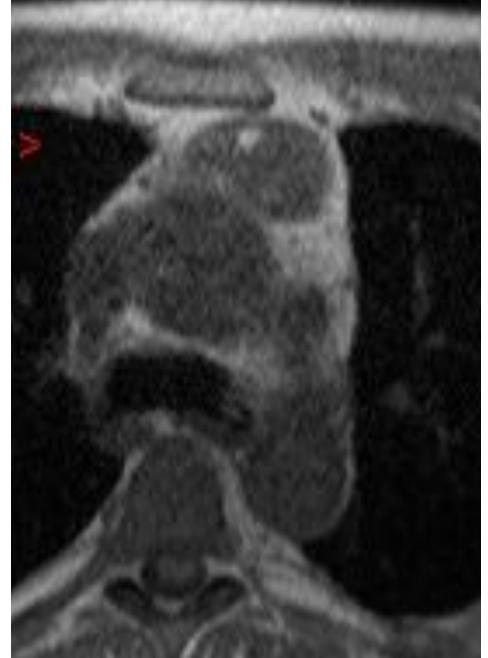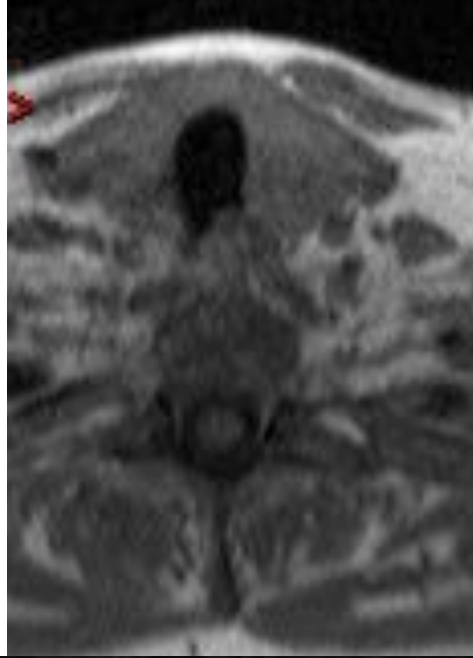
Echo thyroïdienne Normale il y a 3 mois

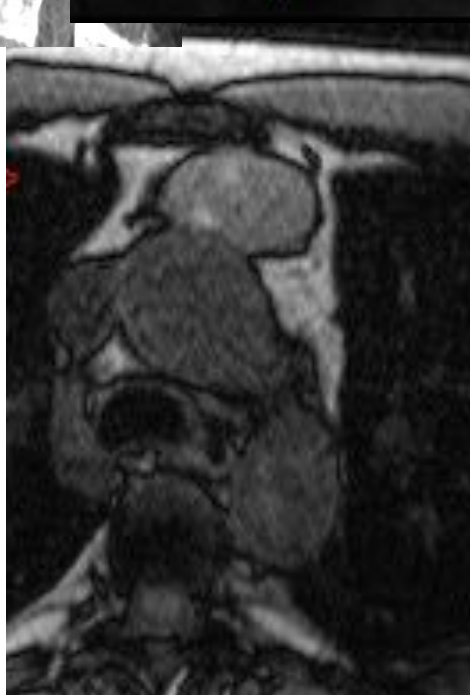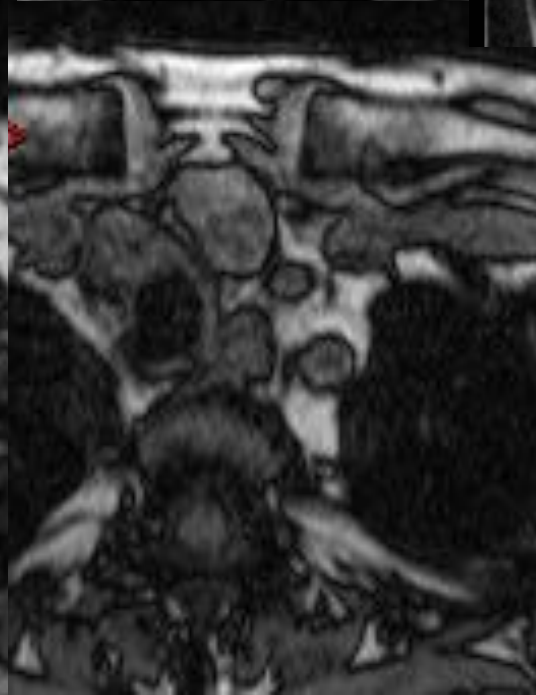
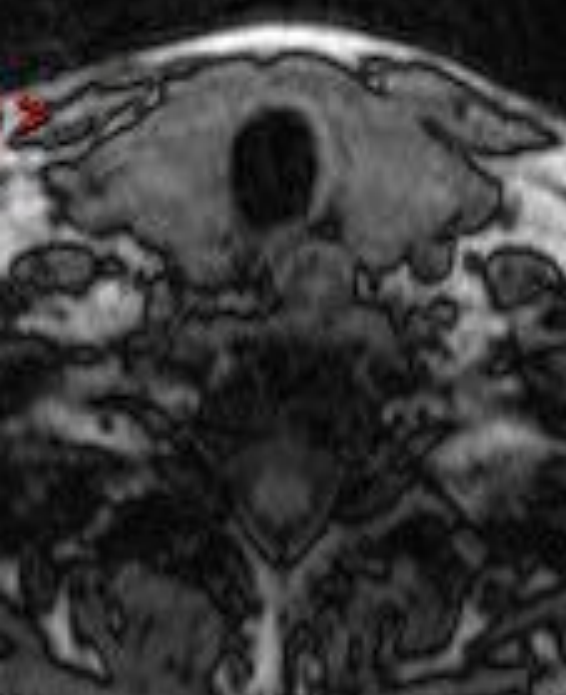
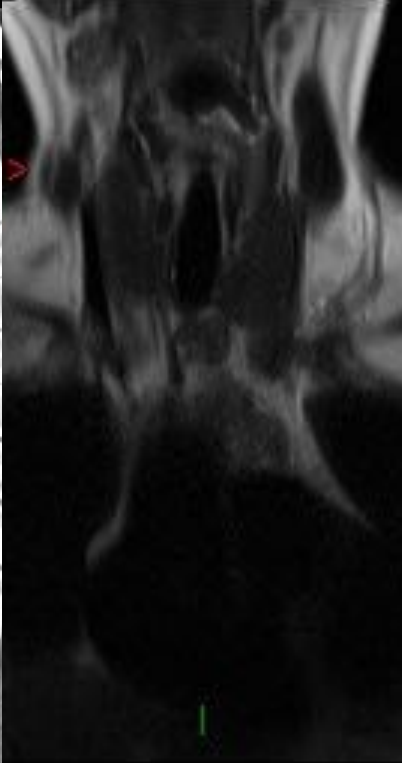
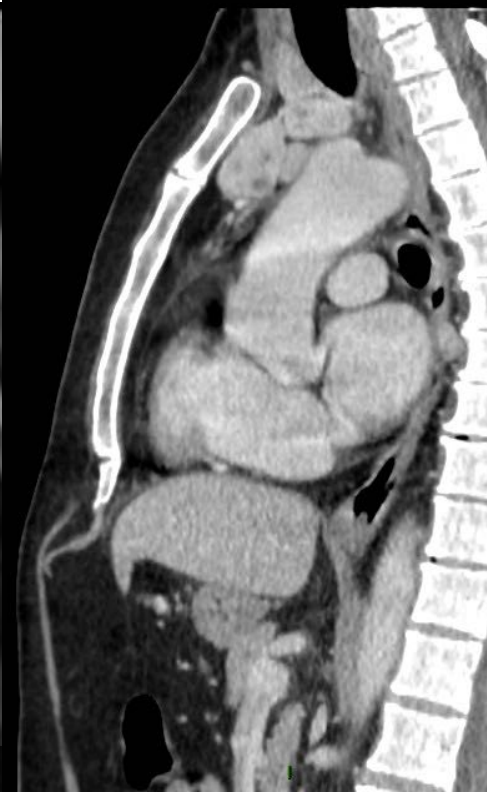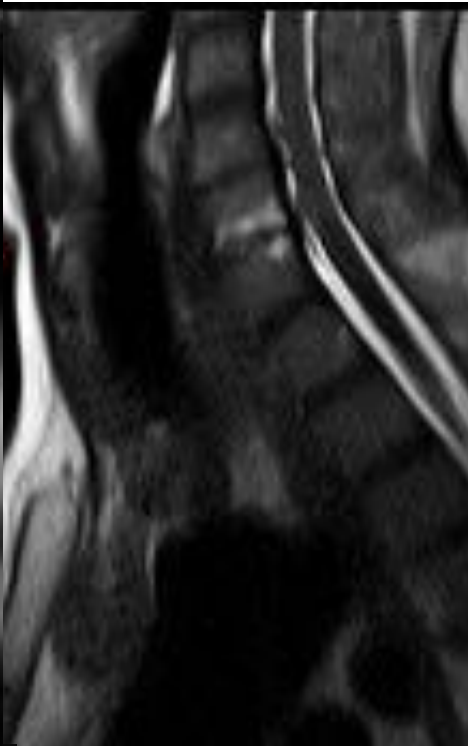
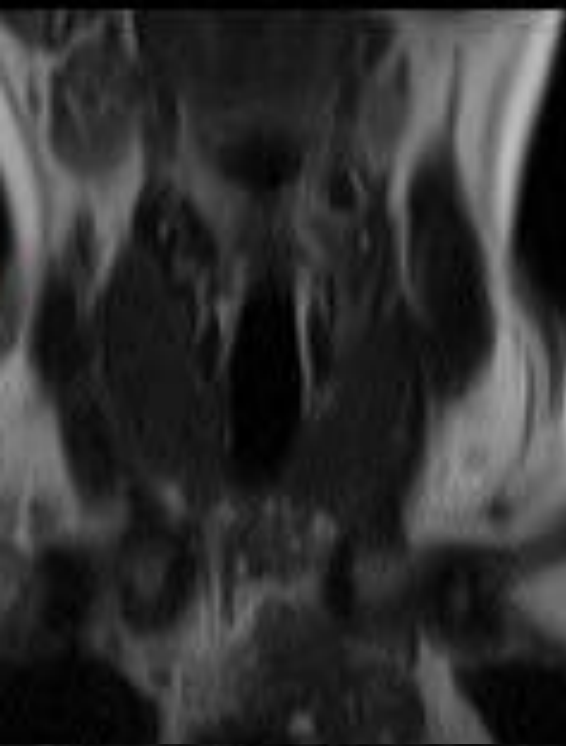


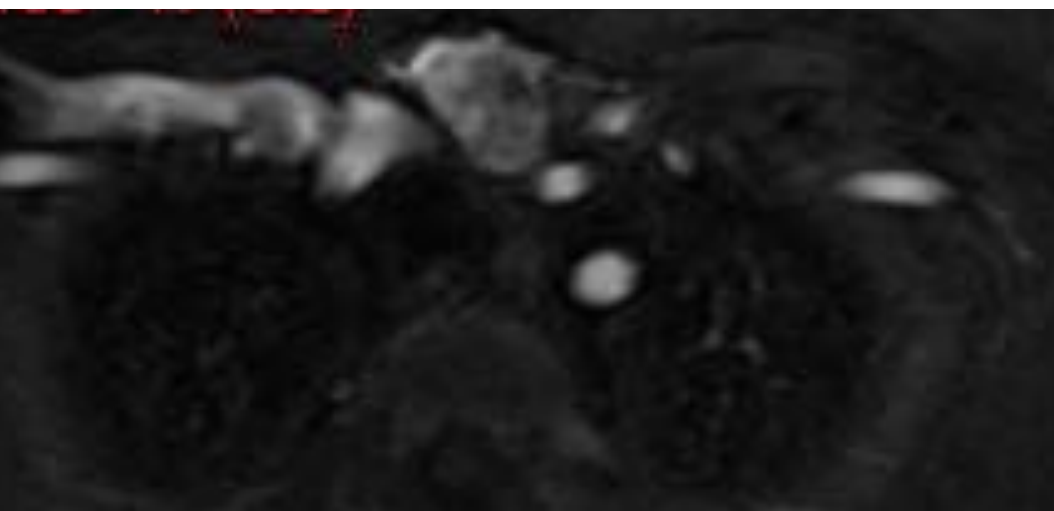
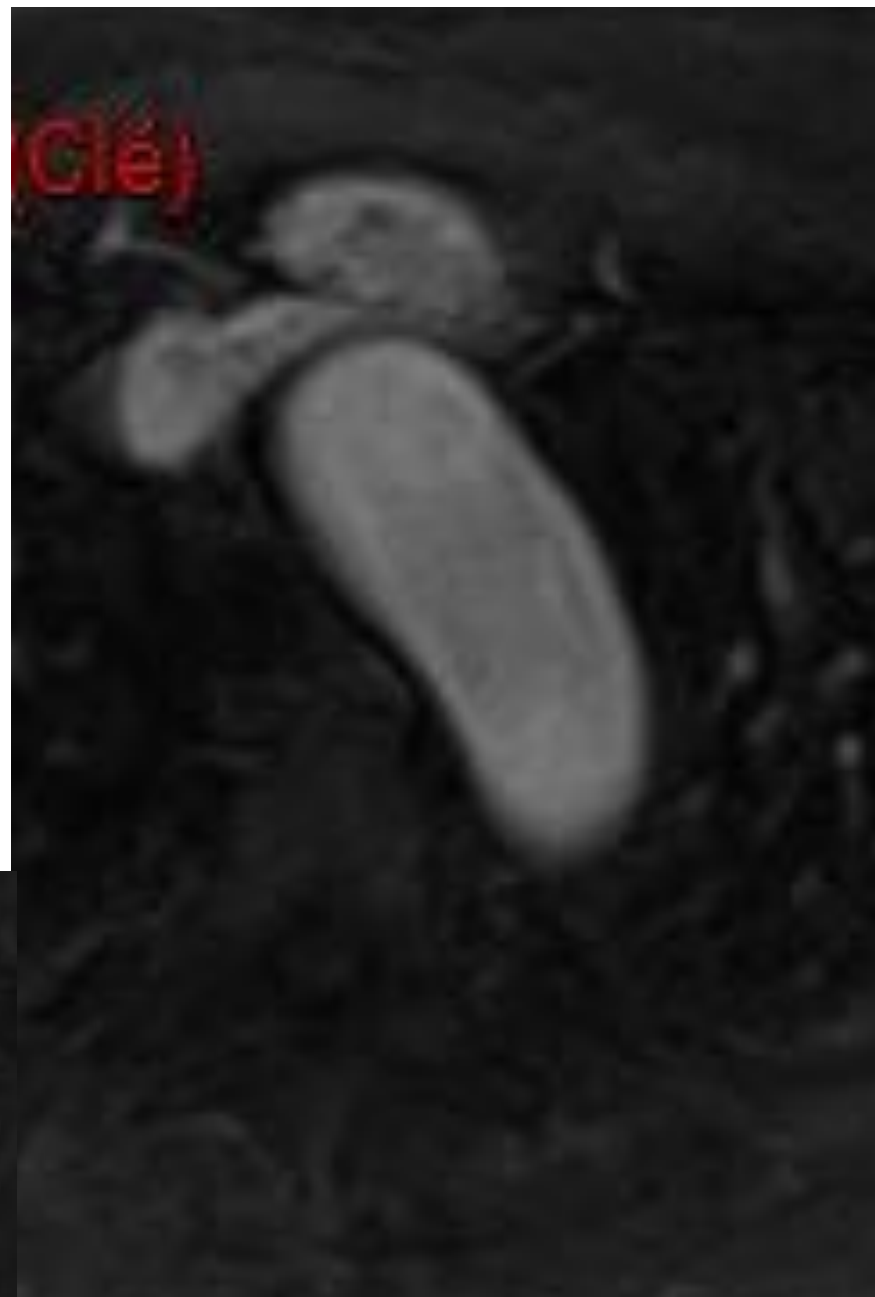
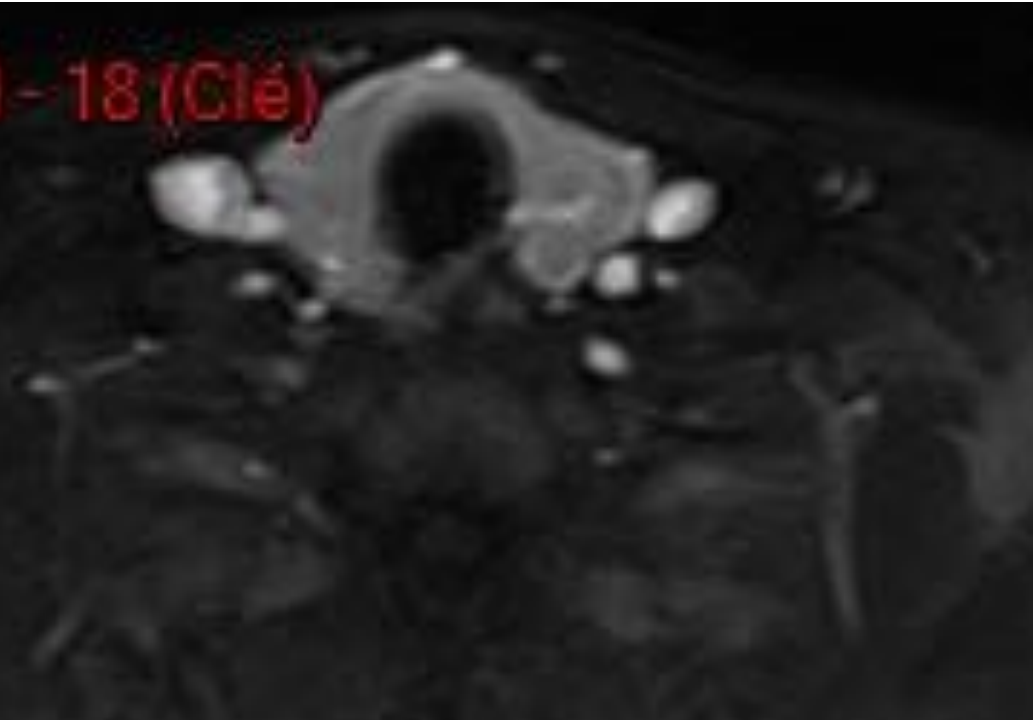


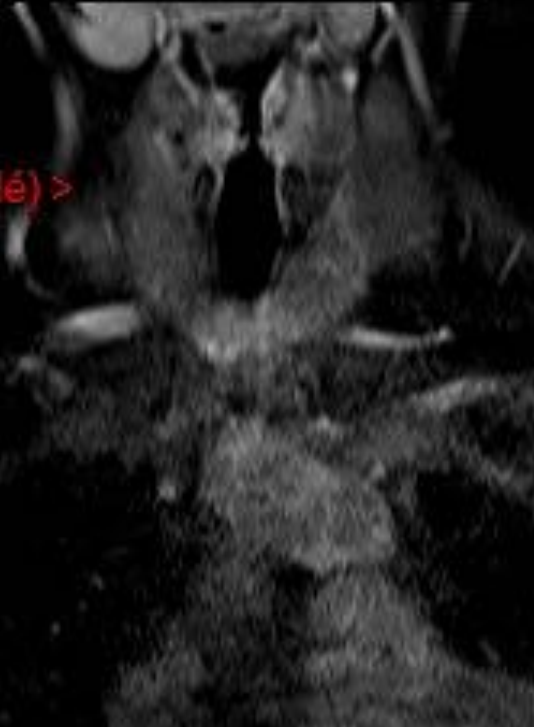
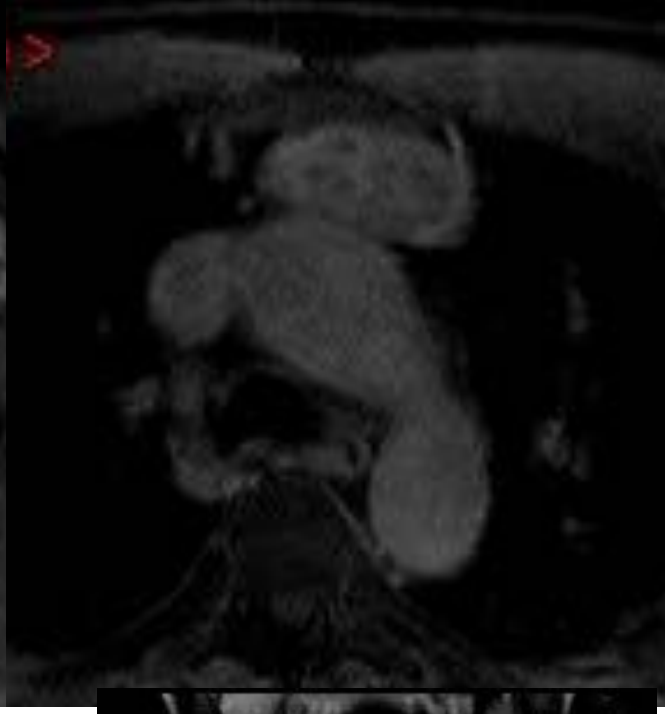
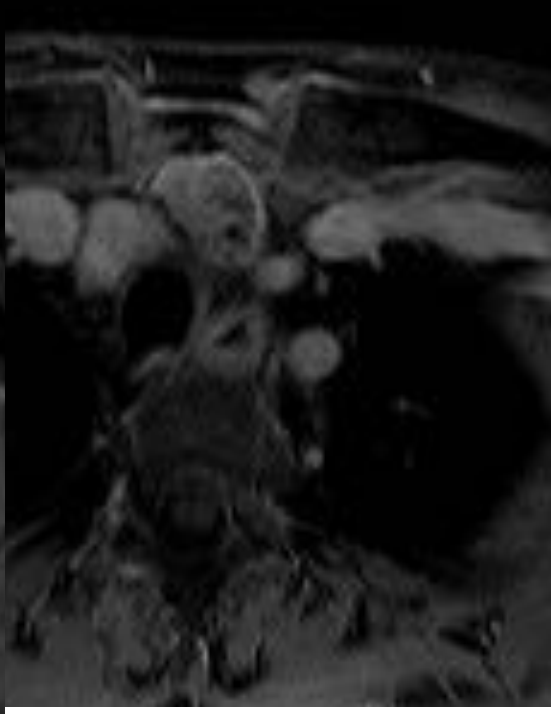
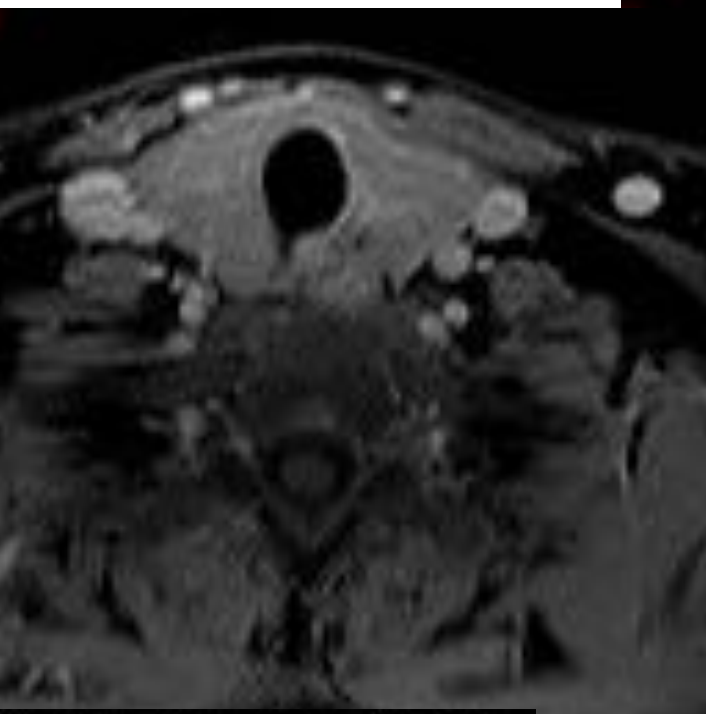


IRM









Hypothèse(s)
Prise en charge ?

