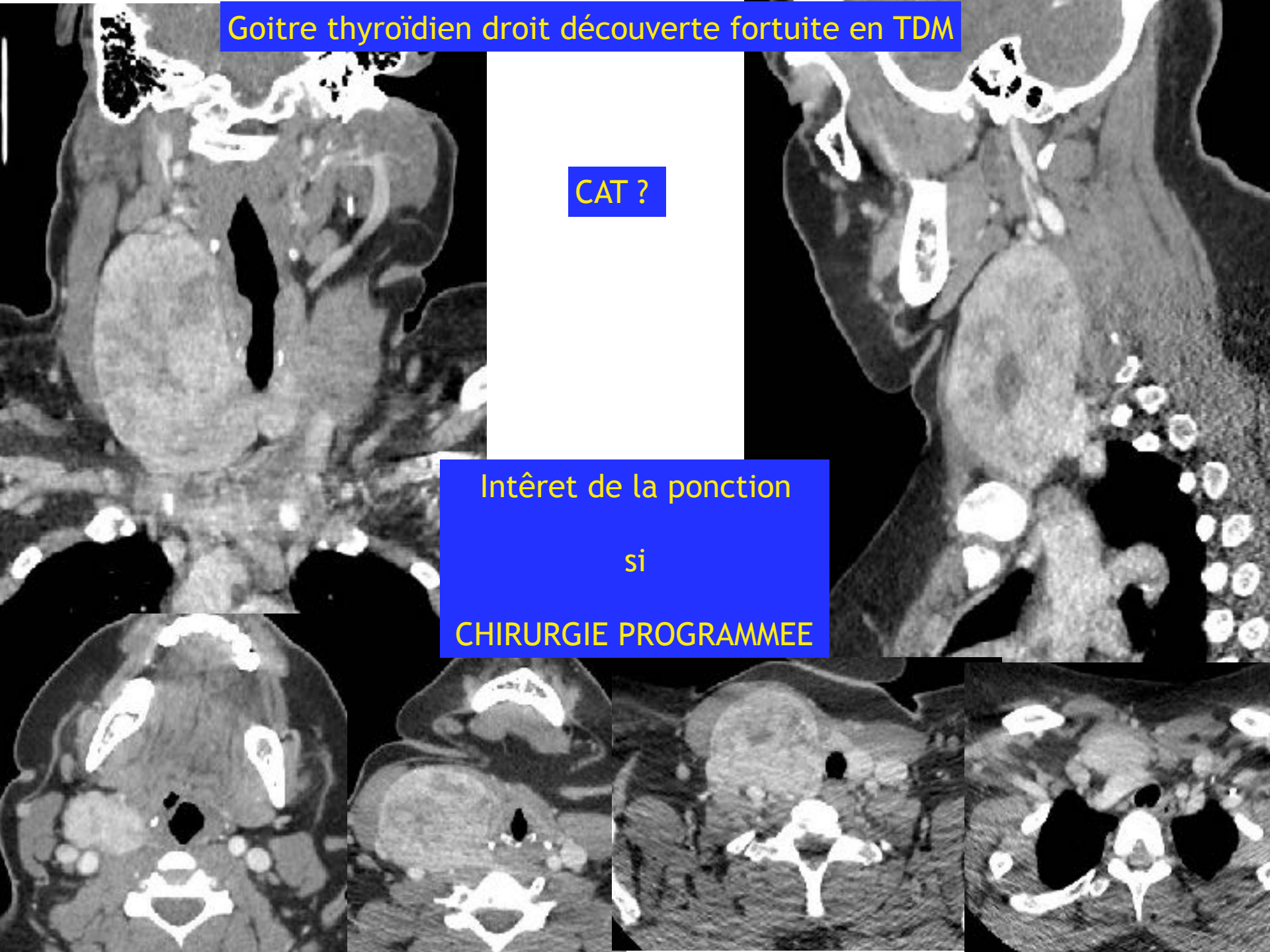


Goitre thyroïdien droit découverte fortuite en TDM

CAT ?

Intêret de la ponction  
si  
CHIRURGIE PROGRAMMEE



32/33  
11Hz

32/33  
10Hz

Volume 1 Vol.: 148.9cm<sup>3</sup>  
Iax-x: 65.9mm 2ax-y: 51.8mm Max-z: 83mm

07  
F82

6/7  
3Hz

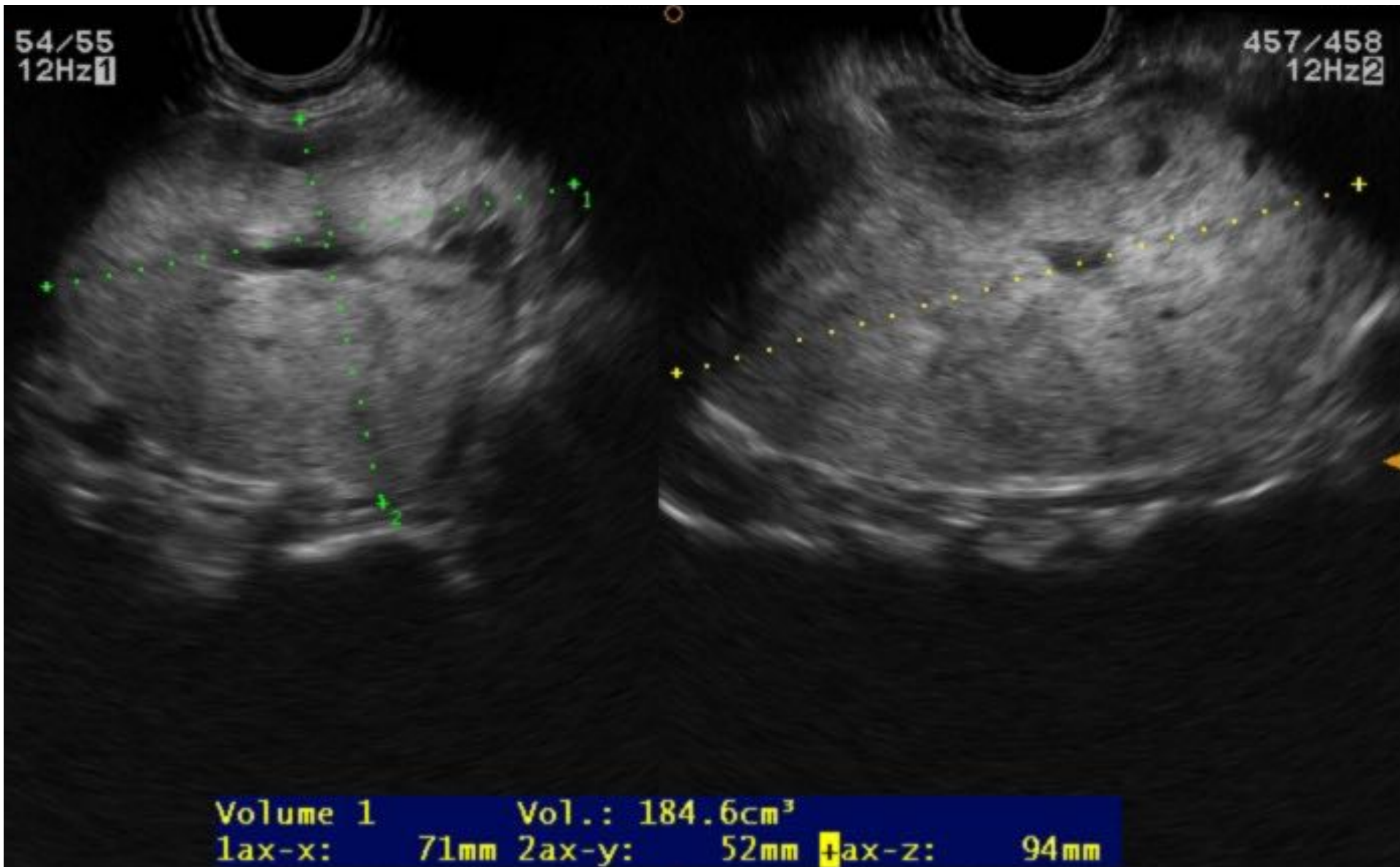
05  
C

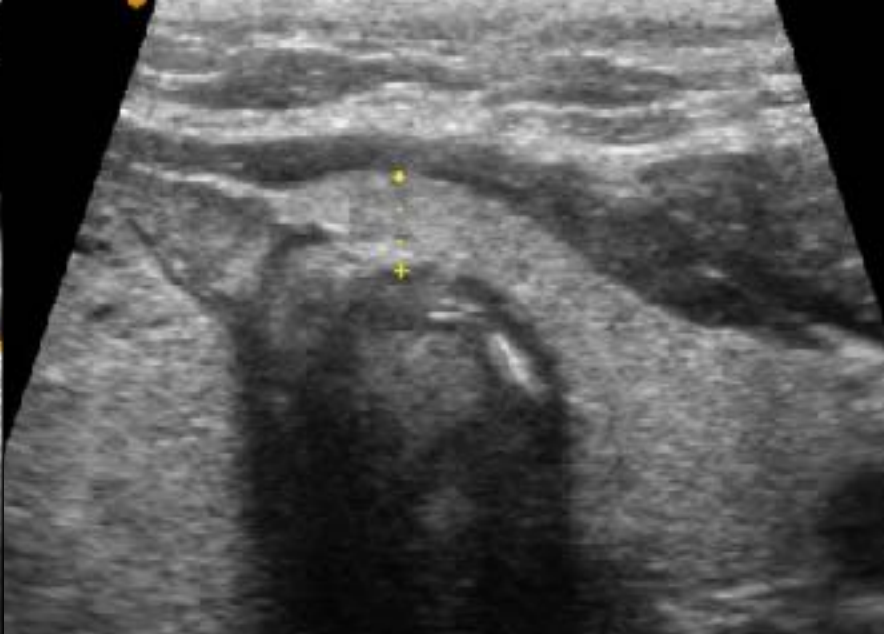
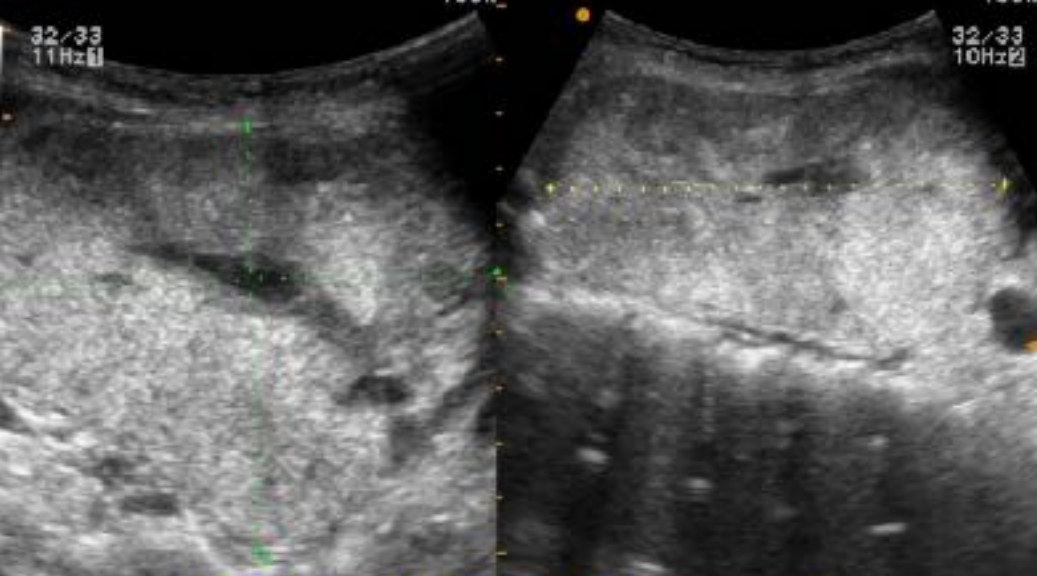
147.5

24.9

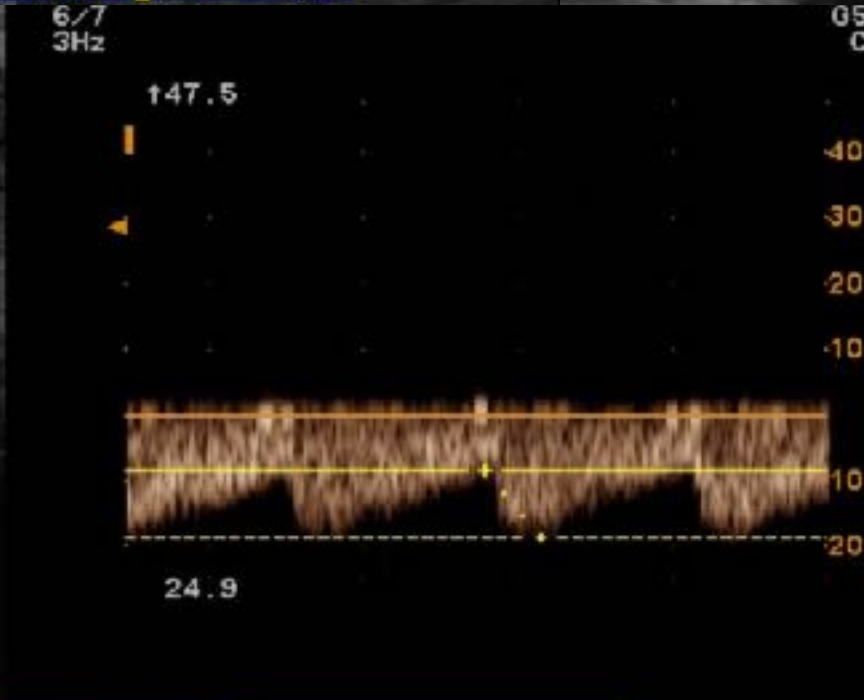
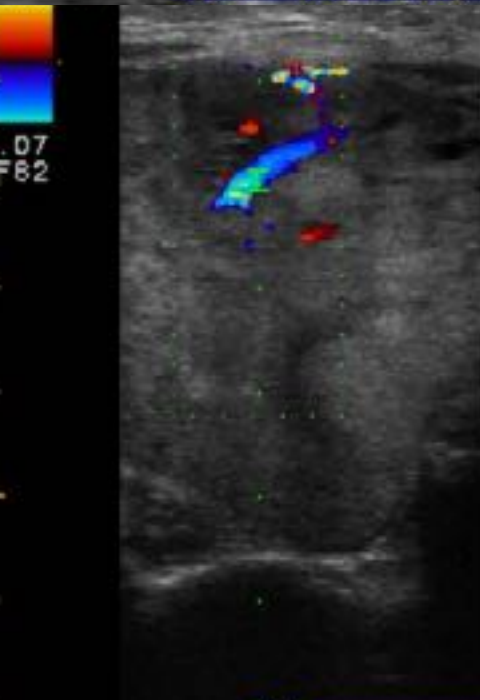
IR: 0.545  
S/D: 2.20 Vs: 18.7cm/s Vd: 8.5cm/s

Goitre thyroïdien droit découverte fortuite en TDM  
Nodule TOTOLOBAIRE DROIT: TIRADS ?  
Lobe Gauche normal: CAT





Volume 1 Vol.: 148.9cm<sup>3</sup>  
Iax-x: 65.9mm 2ax-y: 51.8mm Max-z: 83mm



IR: 0.545  
S/D: 2.20 Vs: 18.7cm/s Vd: 8.5cm/s

TIRADS ?