Quiz case

M Tassart, S Périé,

Hôpital Tenon, APHP, Paris
UPMC

Patient de 21A, arrivée en France Mai 2016, IR terminale.
Hémodialysée depuis 5 ans

Bilan d'exophtalmie

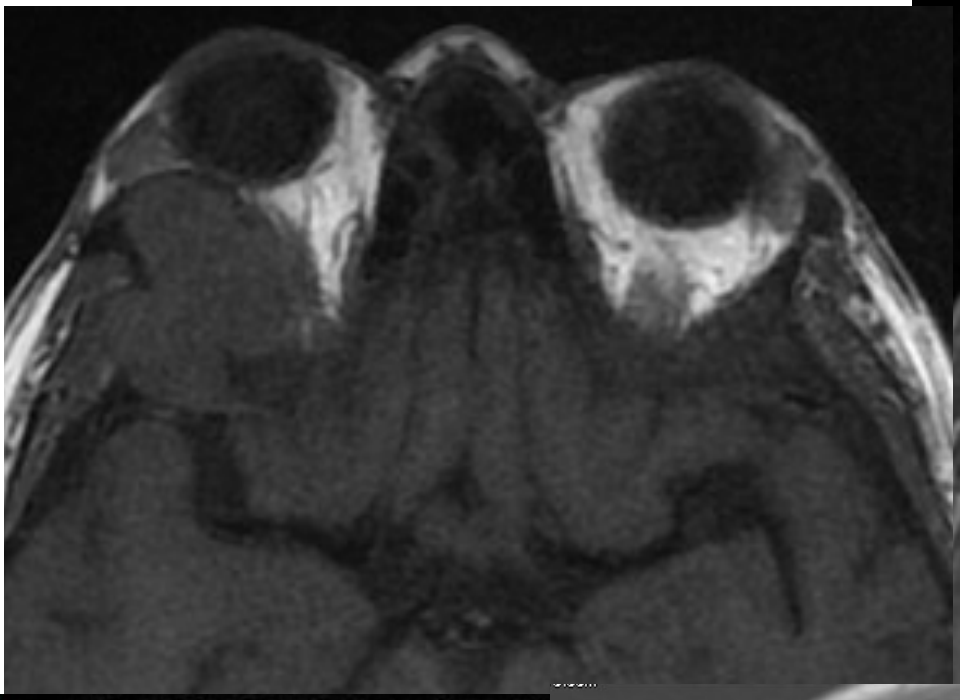

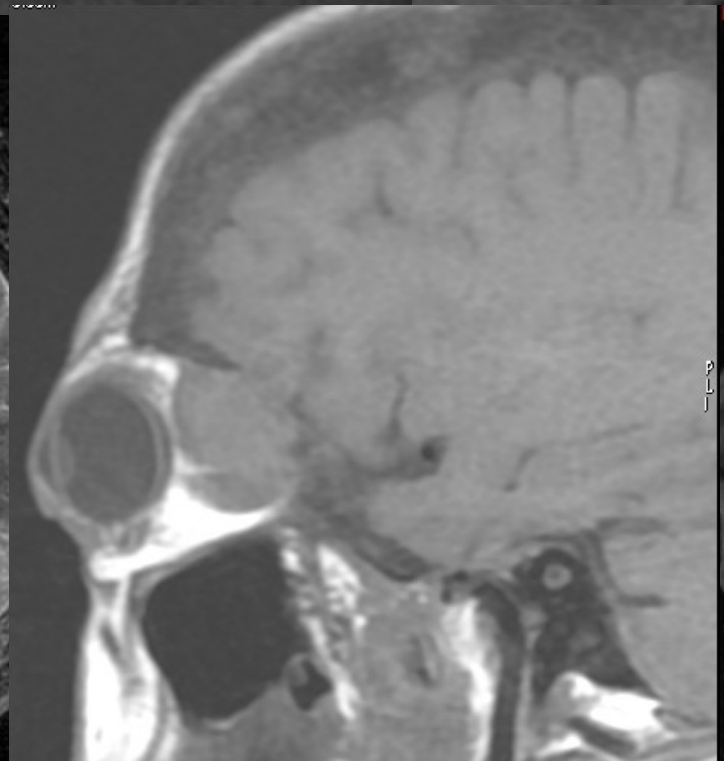
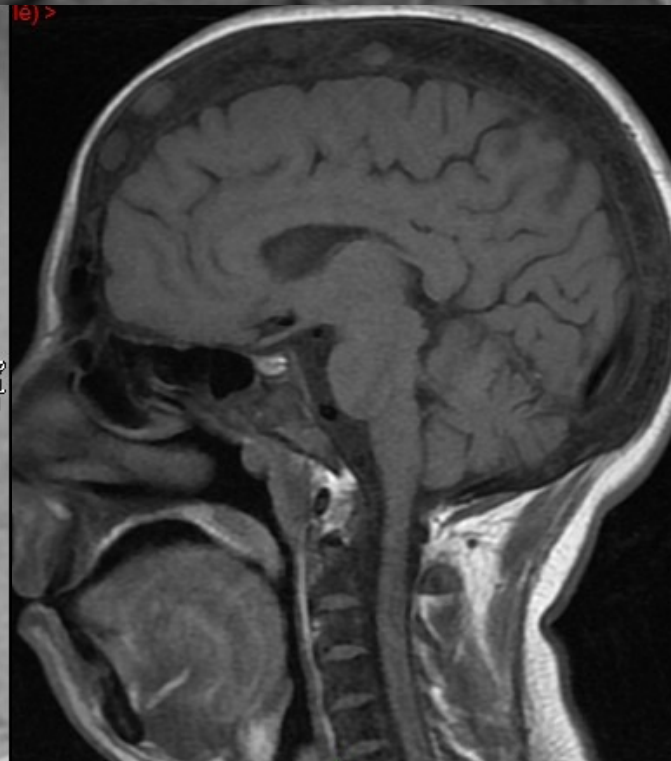

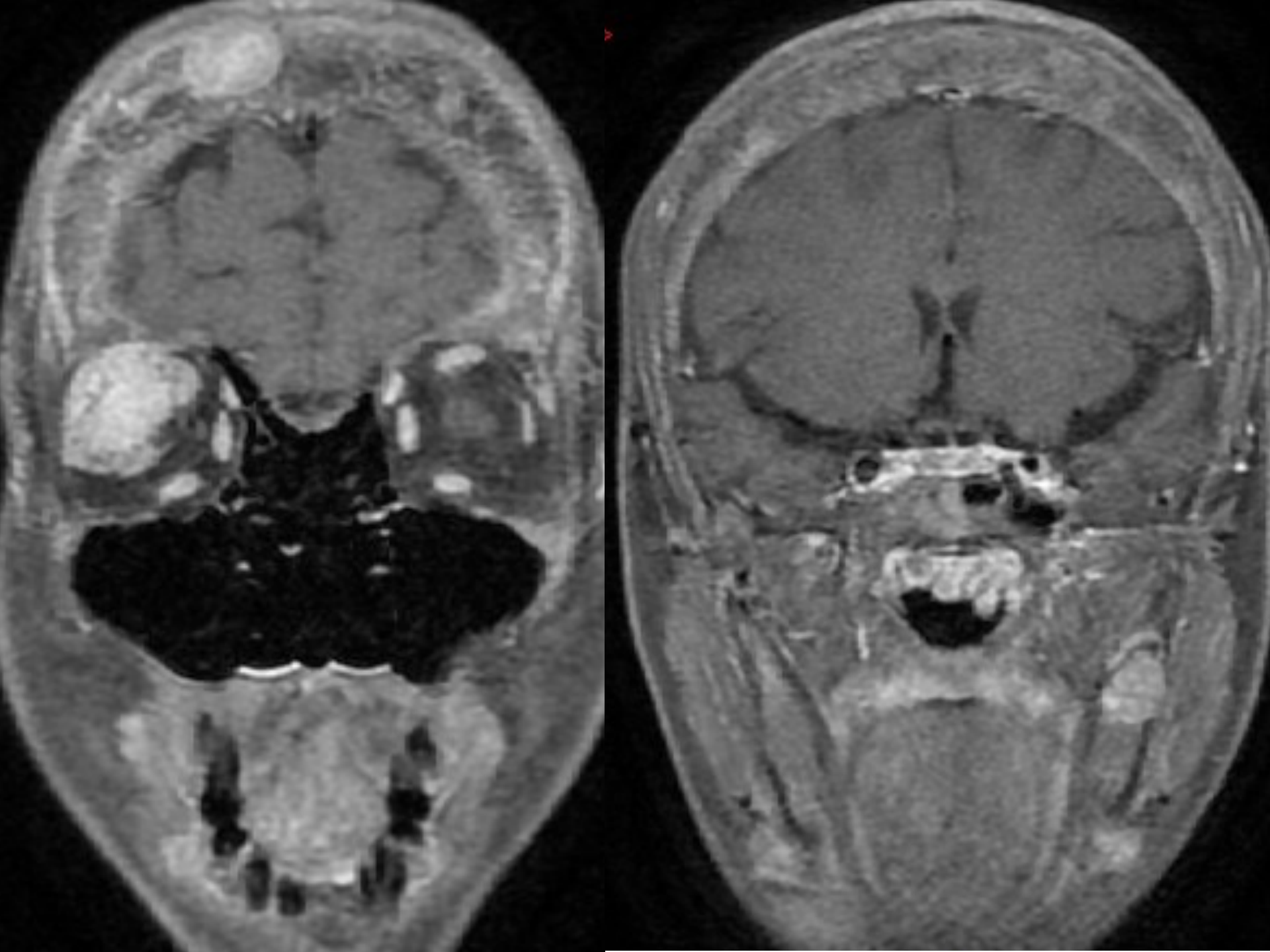

RADIO
Systématique

Il y a 3 mois

Quel bilan ?
PTH à 1800 pg/ml

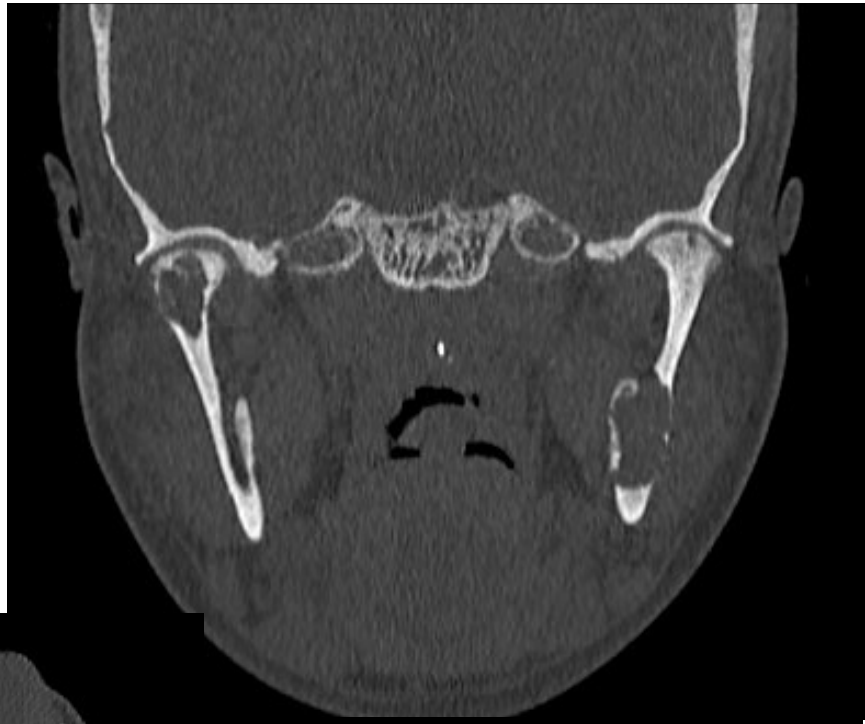

P

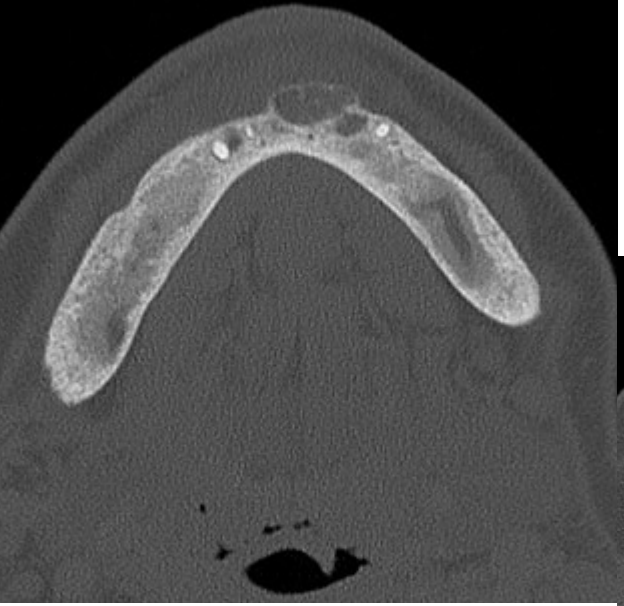

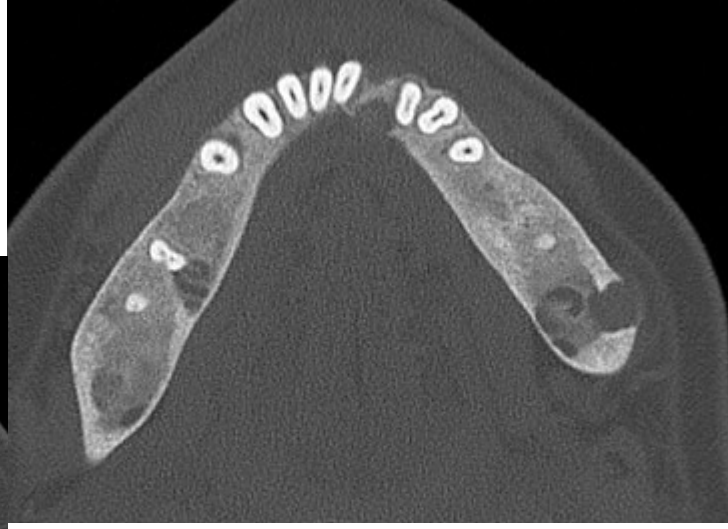

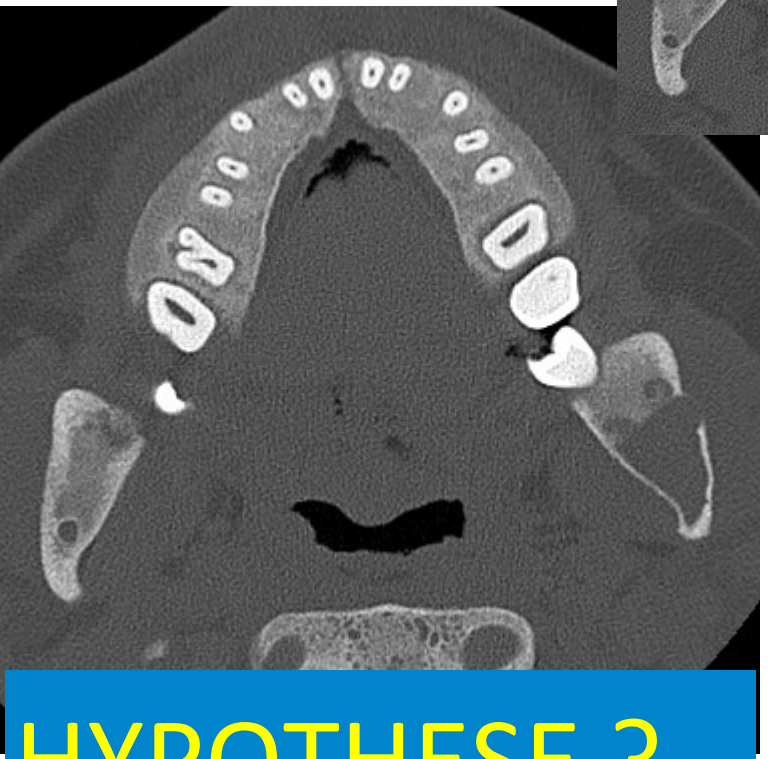

HYPOTHESE ?

D
CARESTR

TUMEURS BRUNES HYPERPARA THYROÏDIE IIaire

311 patients sur 20 ans (1993-2013)

Tumeurs brunes (6.75%); Dialyse > 85 mois; PTH >1900 pg/ml

Douleurs osseuses: 76,1%

Lésions soufflantes Multifocales (57,1%)

Costales plus fréquentes (28,5%)

Mandibule très évocatrice

Parathyroïdectomie (3/4 ou 7/8)

Brown tumors in chronic hemodialysis patients. Gorsane I. Nephrol Ther. 2016 Apr; 12(2):86-93

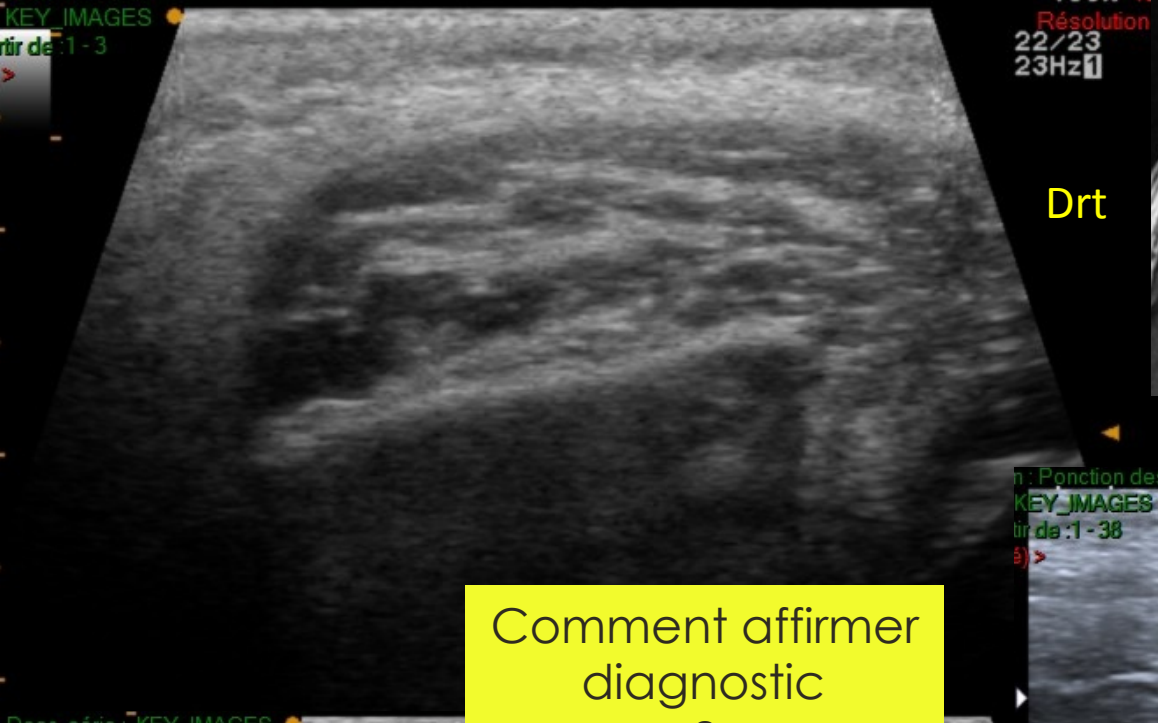

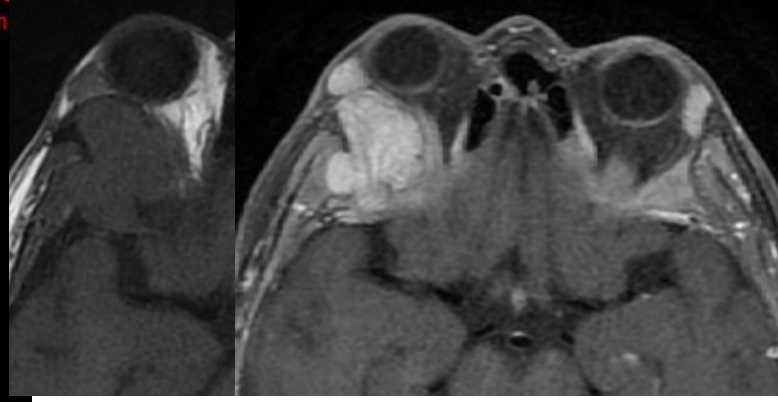

Comment affirmer diagnostic ?

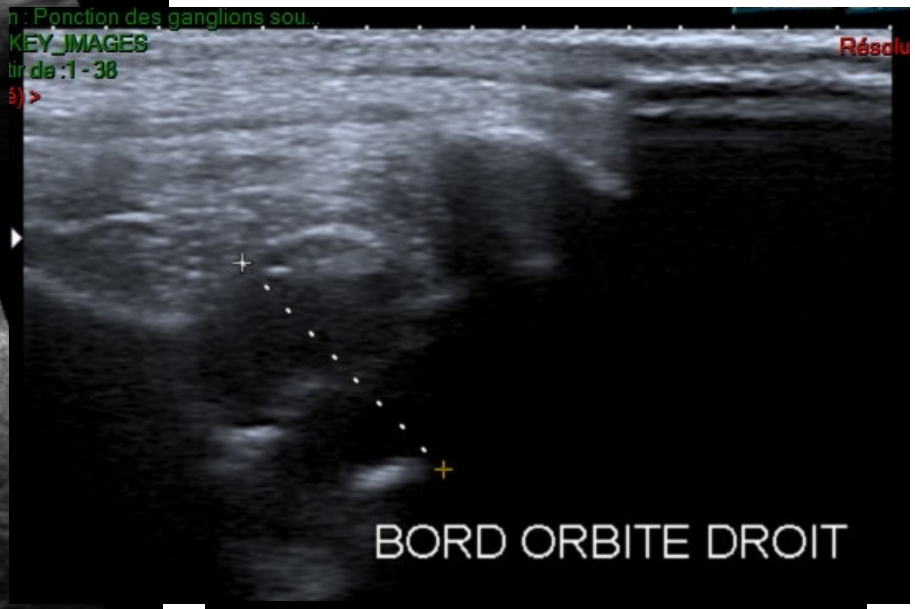

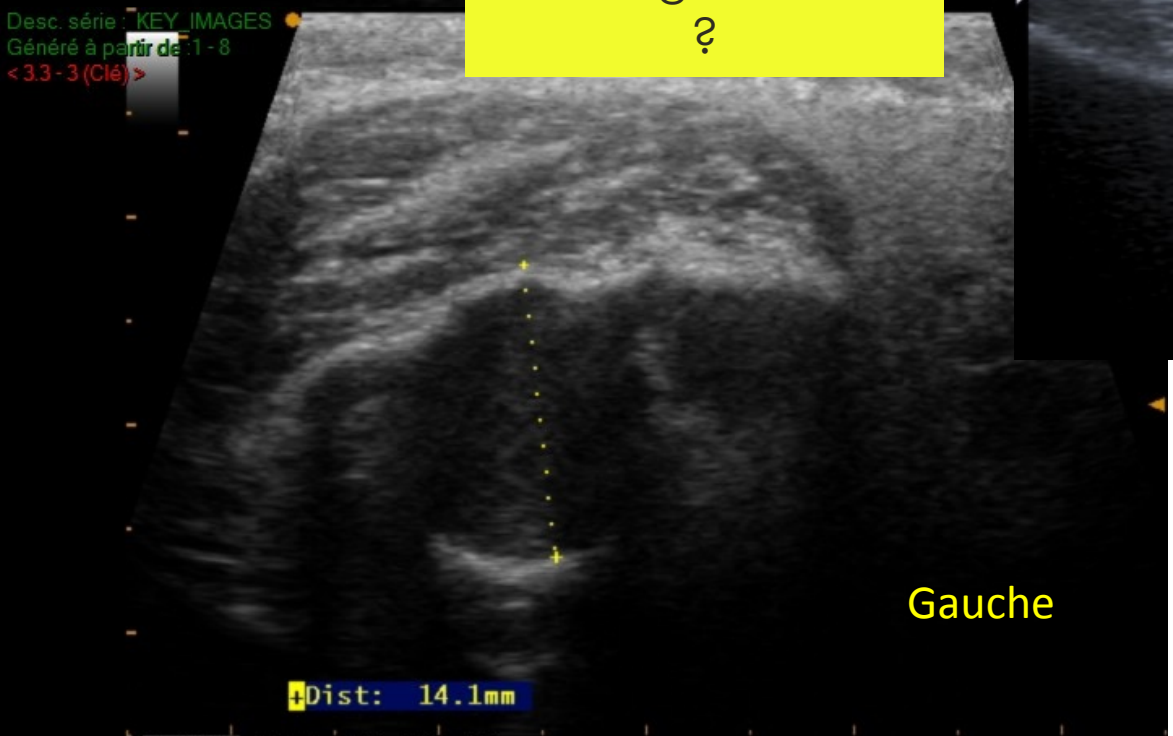

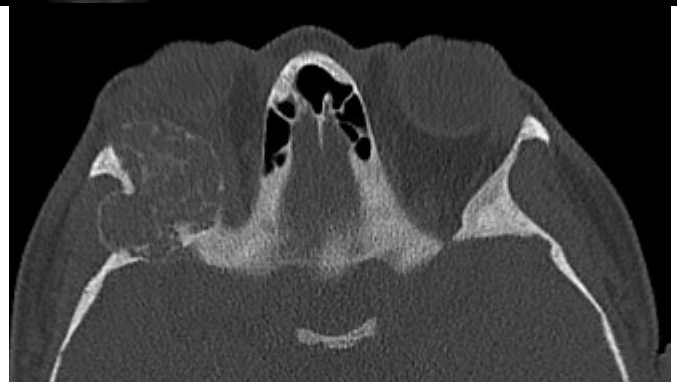

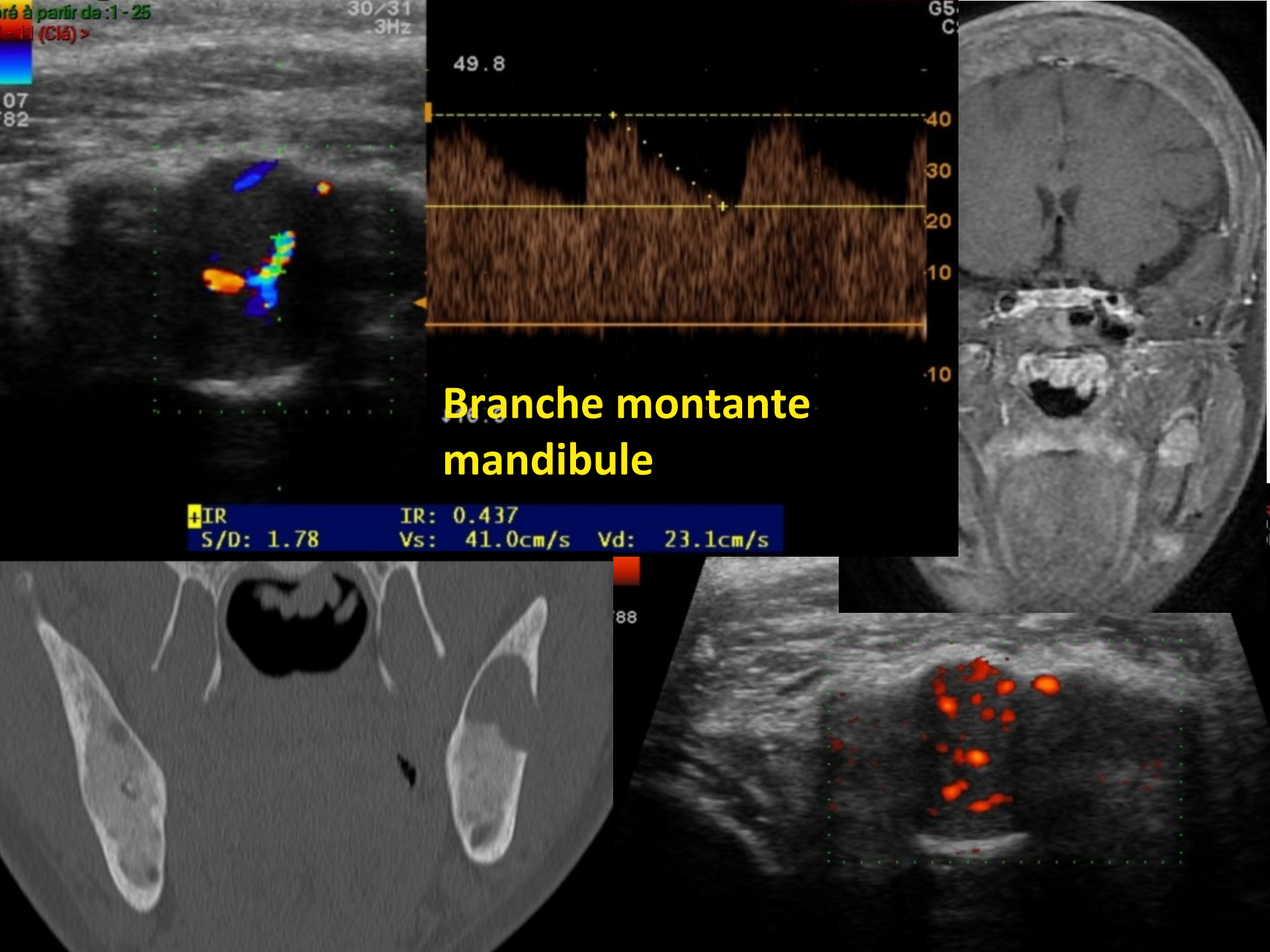
Branche montante
mandibule
IR
S/D: 1.78
IR: 0.437
Vs: 41.0cm/s
Vd: 23.1cm/s

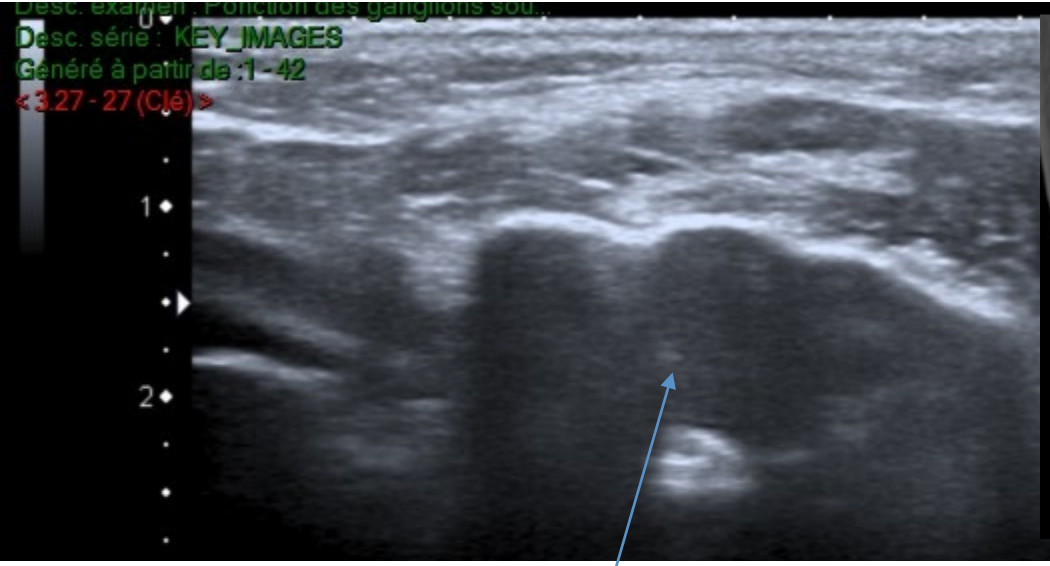

PONCTION CYTO 27G: TUMEUR BRUNE (Ostéoclastes)

QUEL BILAN ?

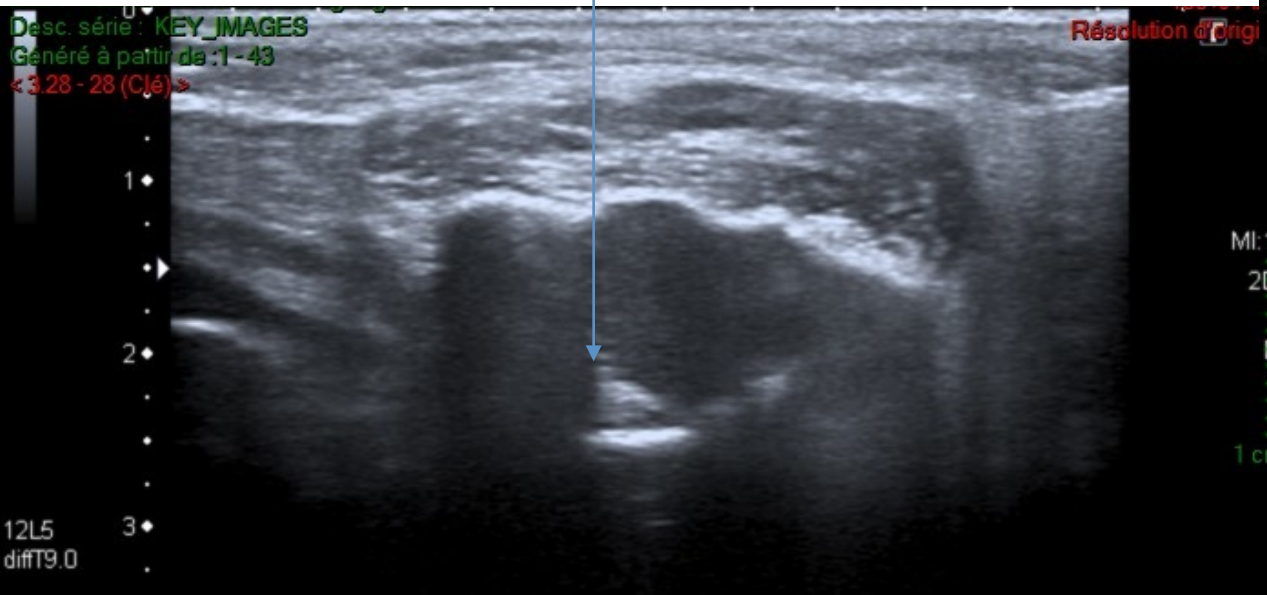

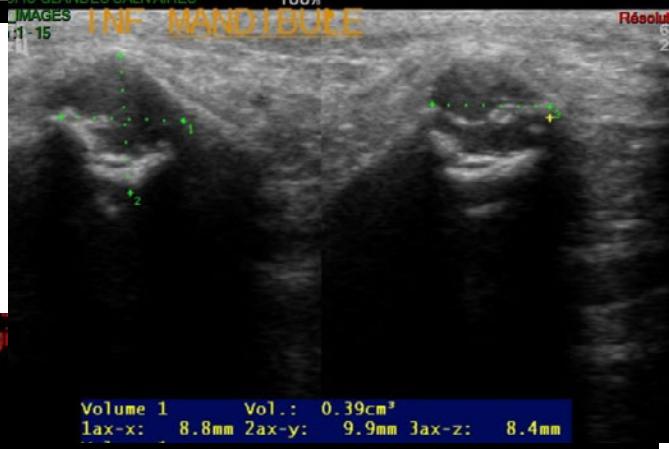

Bilan Préopératoire
REPERAGE

2 PTH Gches

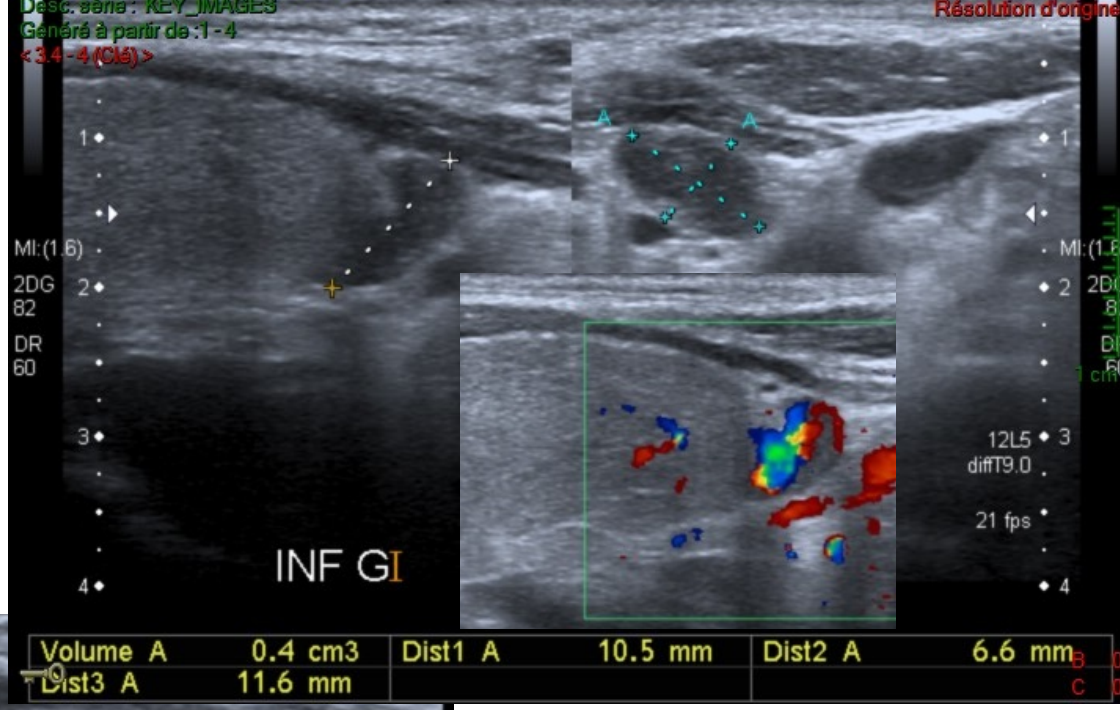

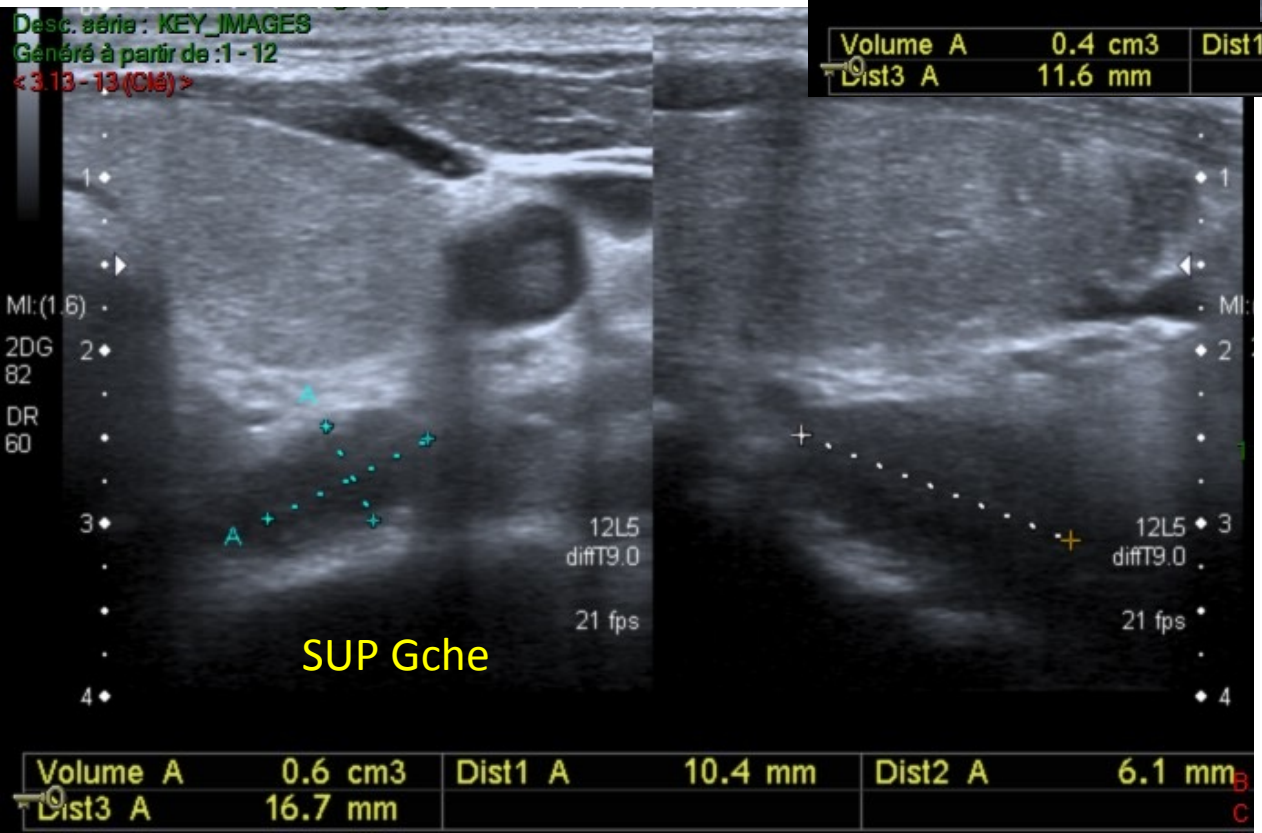

2 PTH Droites

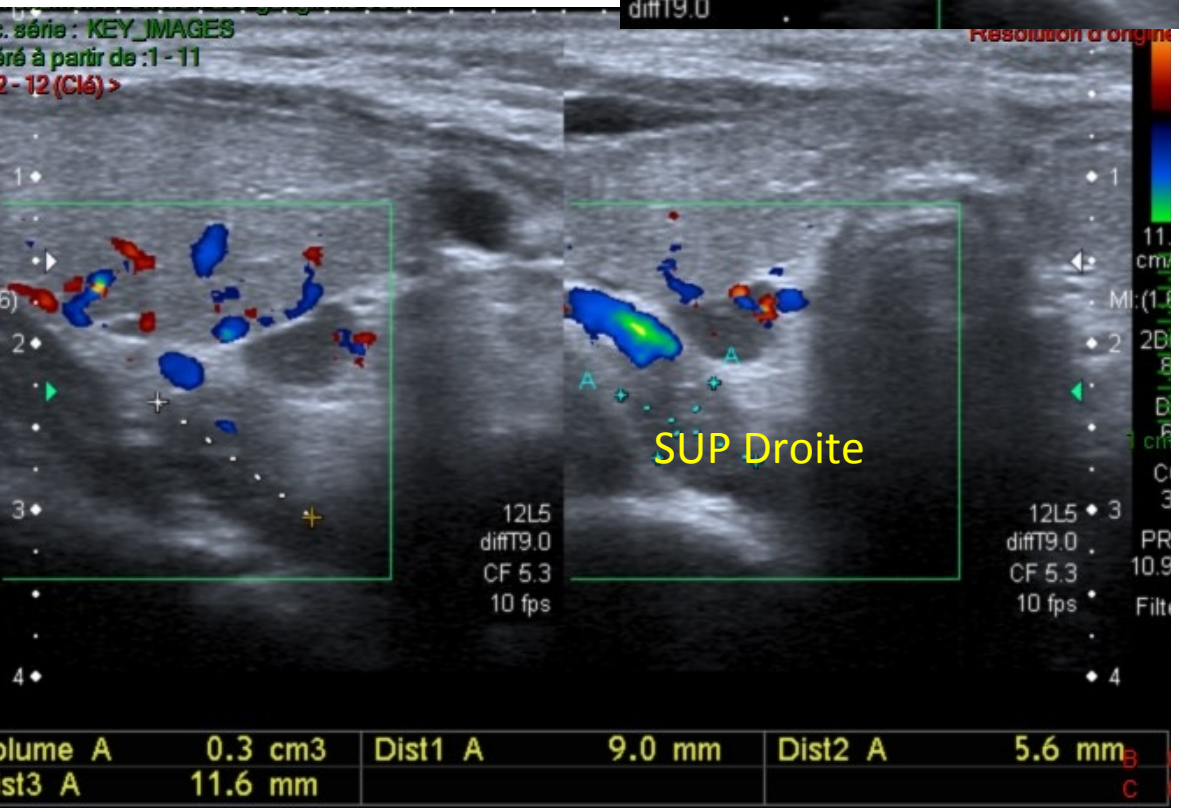

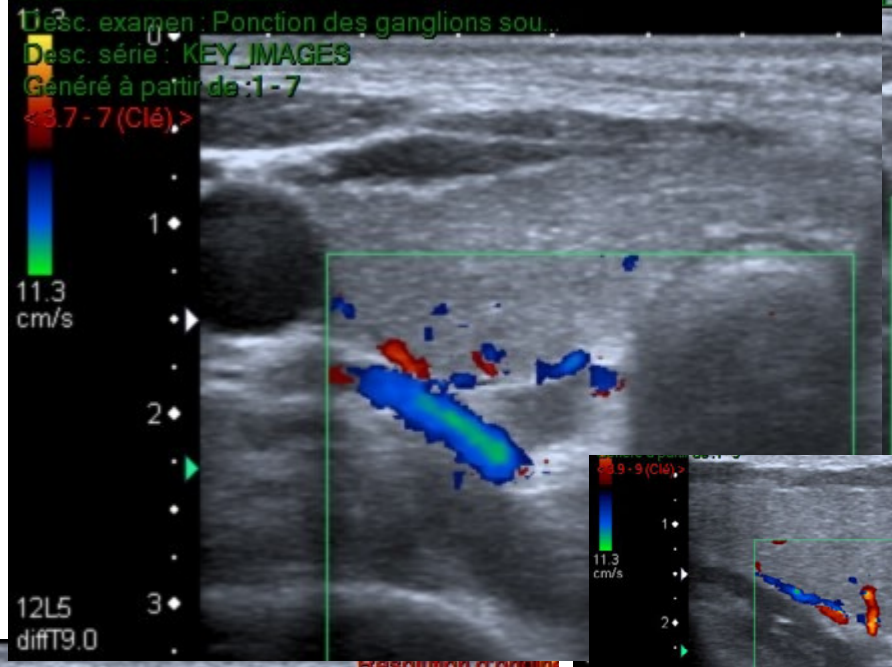

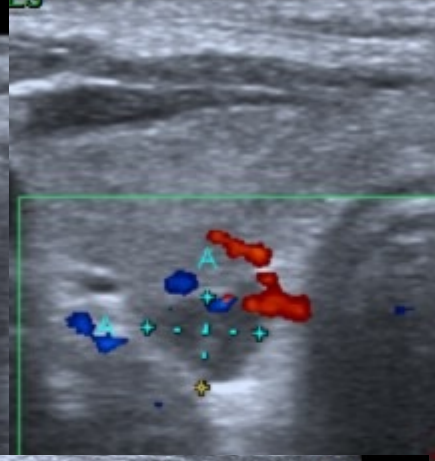

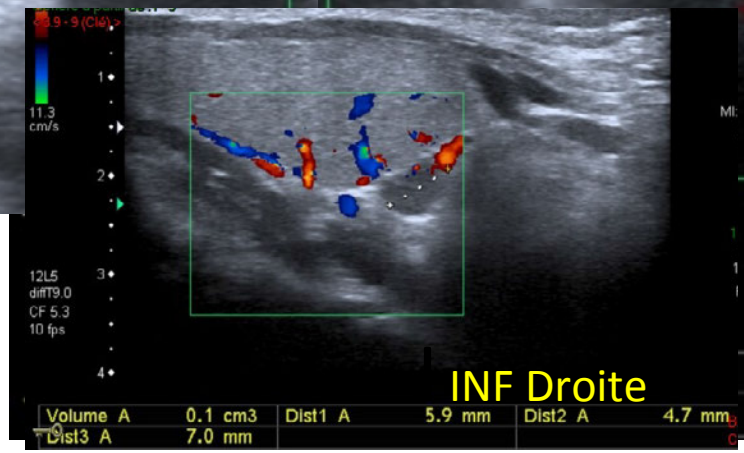

Pas de Scinti MIBI

mais

TEP CHOLINE

!!!!

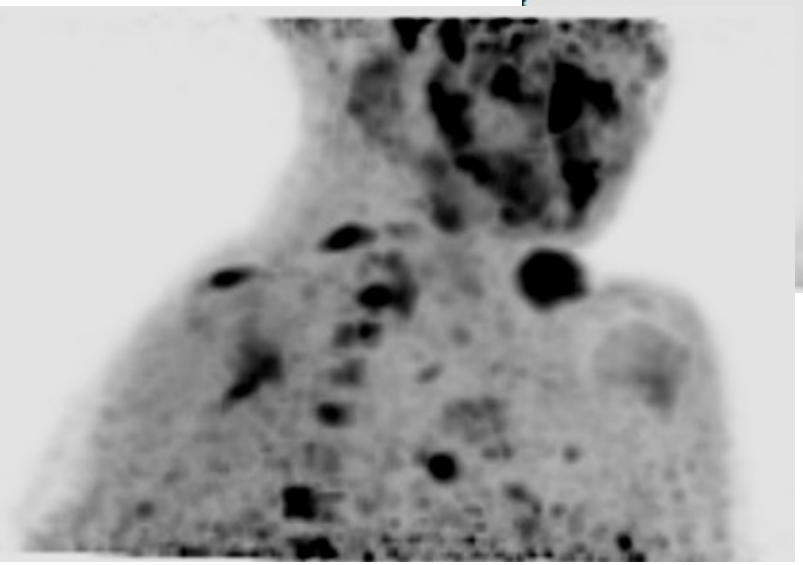

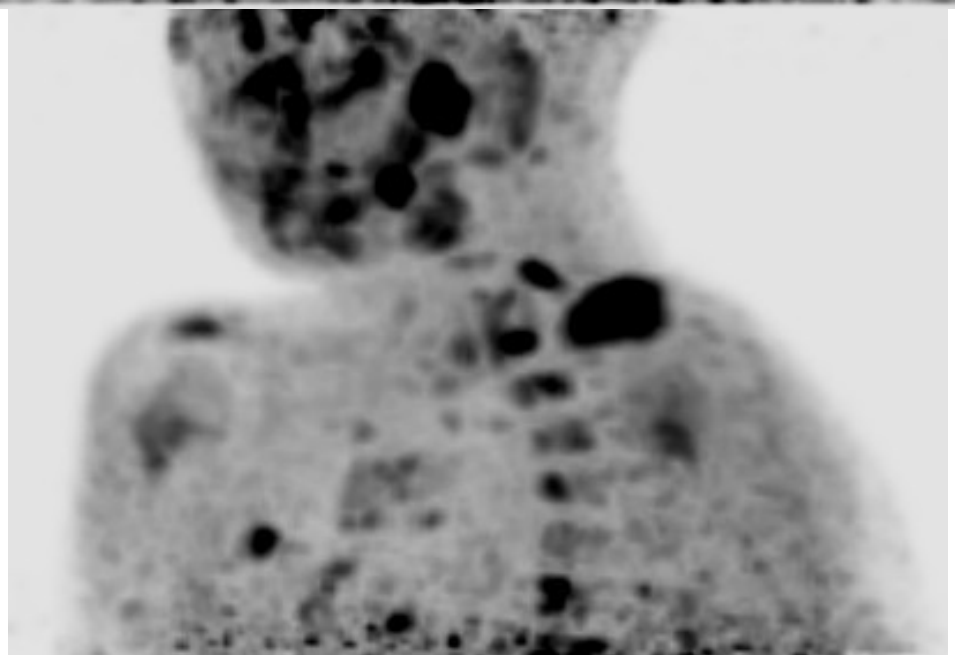

Numerous high-uptake bone lesions.
18-FDG PET/CT> 99mTc-MIBI scintigraphy

Gahier Penhoat M. Contribution of 18-FDG PET/CT to brown tumor detection in a patient with primary hyperparathyroidism. Joint Bone Spine. 2016

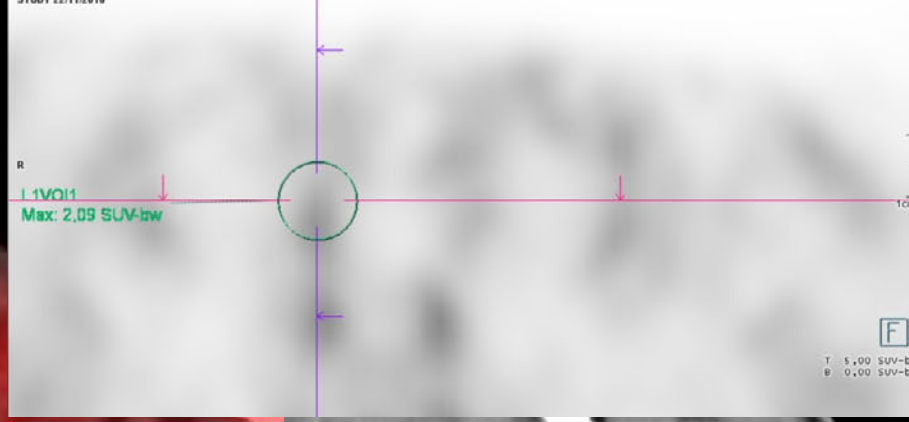

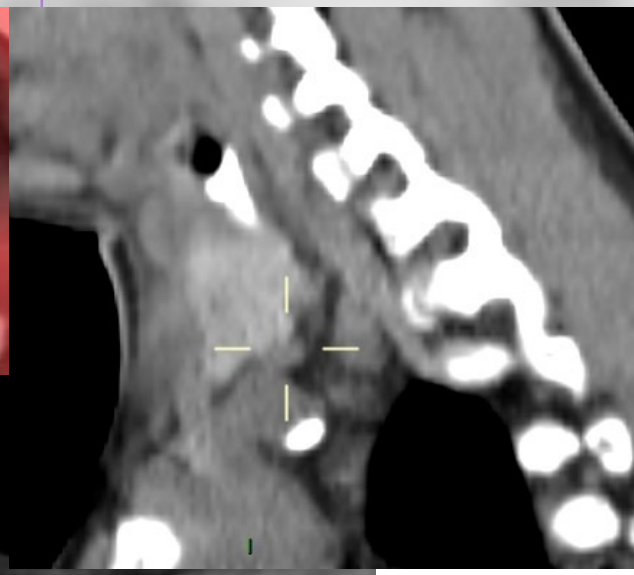

PTH inf
Droite
(1 seule)

mais ?

A quoi correspondent ces fixations

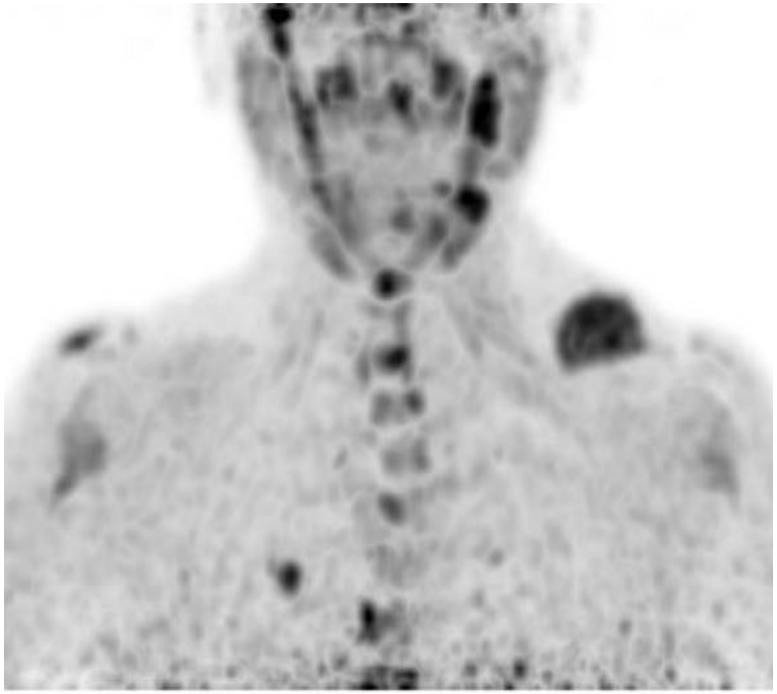

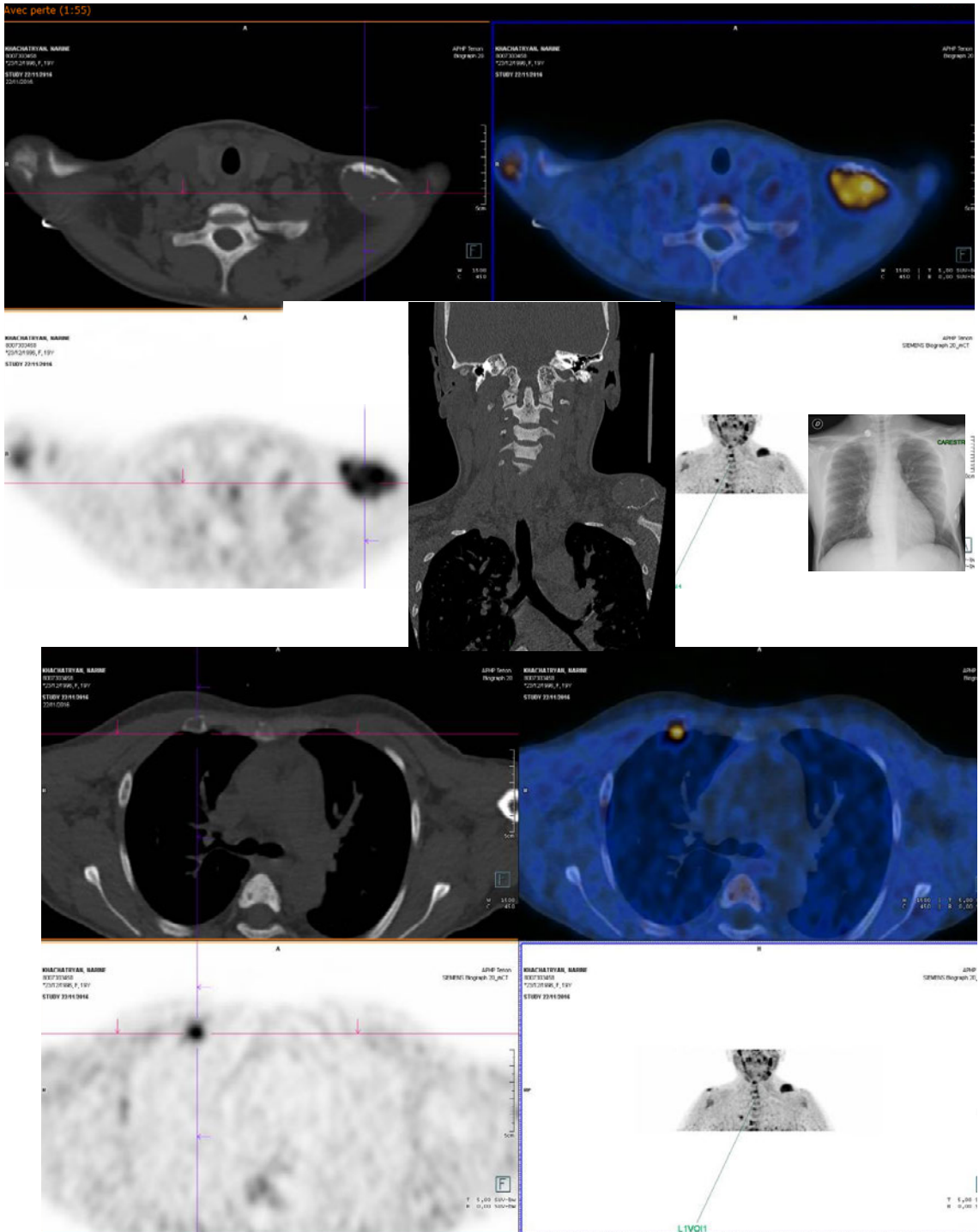

Multiples tumeurs brunes
Costale
Clavicule

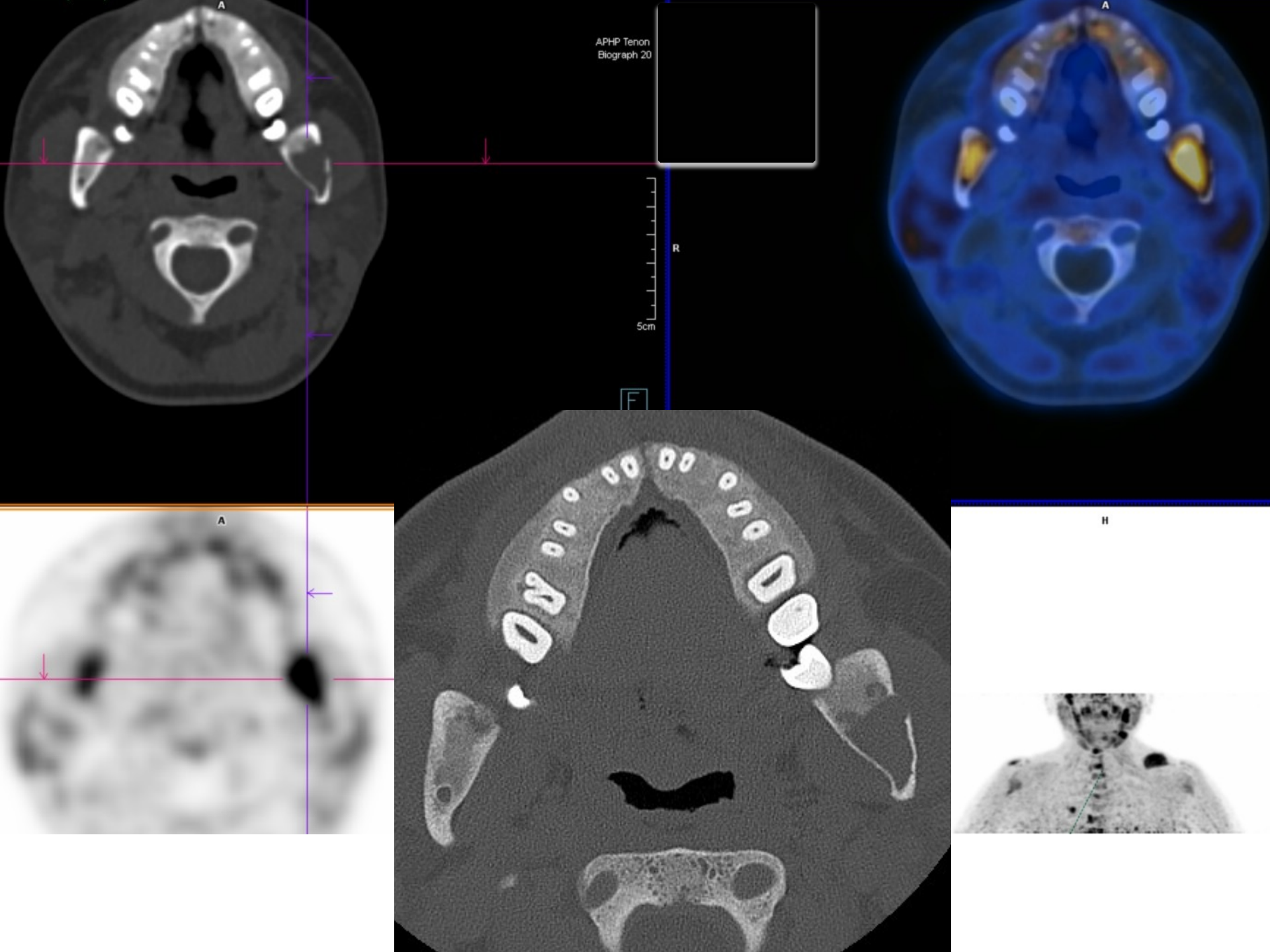
A
APHP Tenon
Biograph 20
R
5cm
A
A
H

R
5cm
F
W 1500
C 450

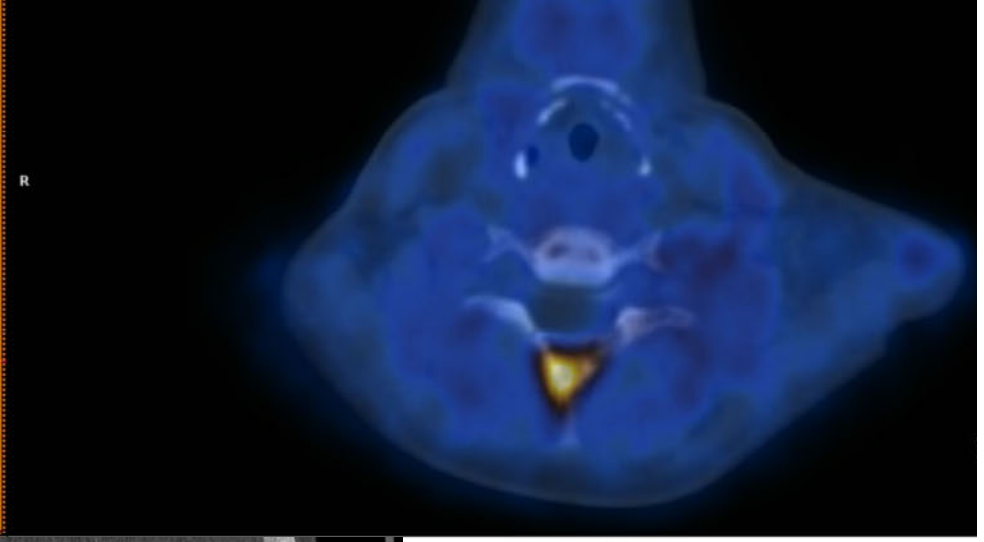


A

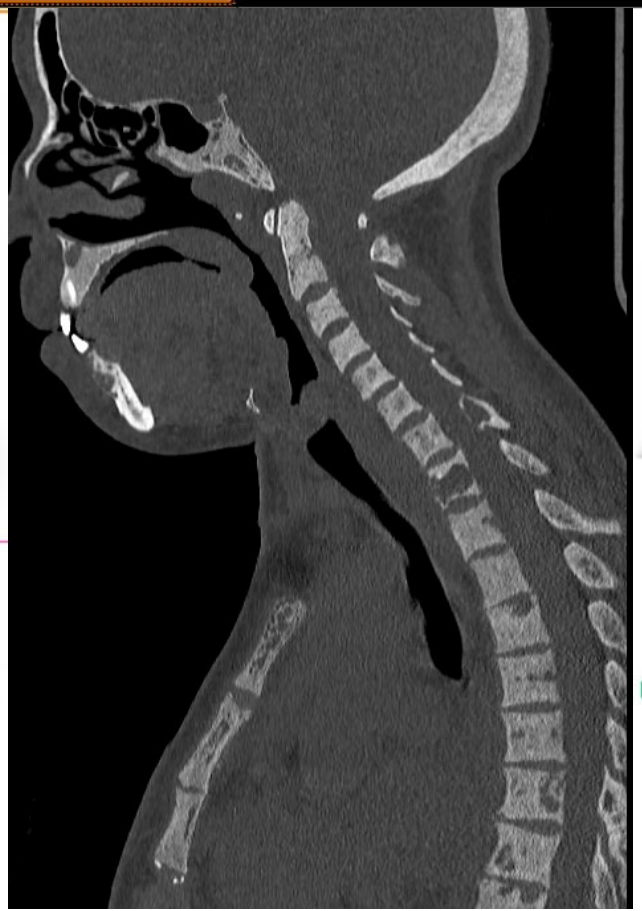

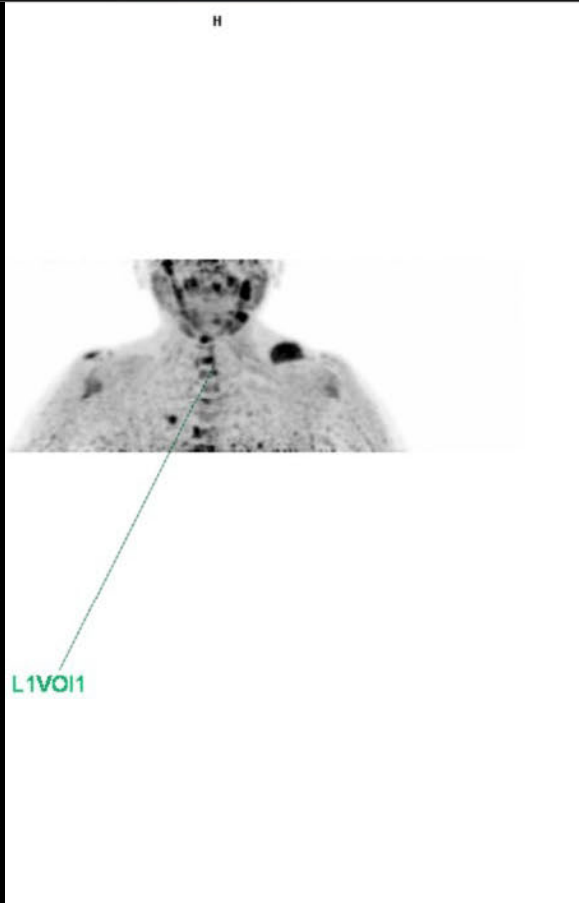
H
L1VOI1

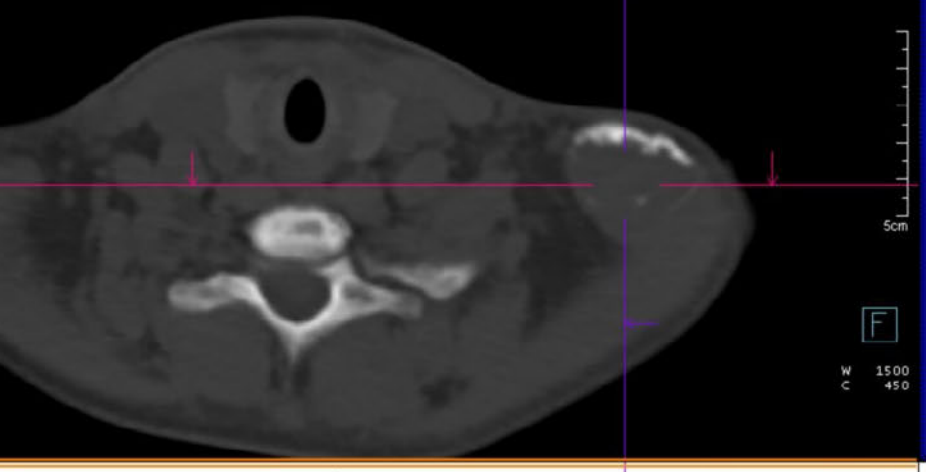
5cm
F
W 1500
C 450
A

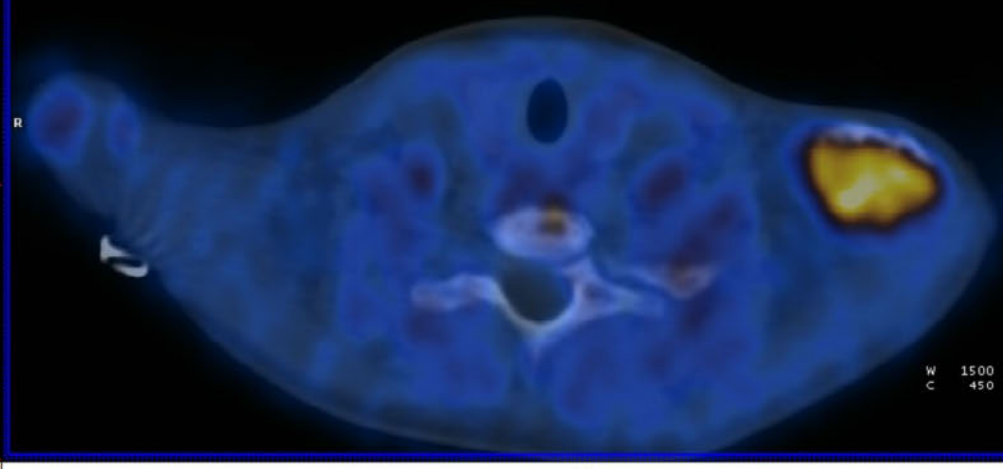
R
W 1500
C 450
H

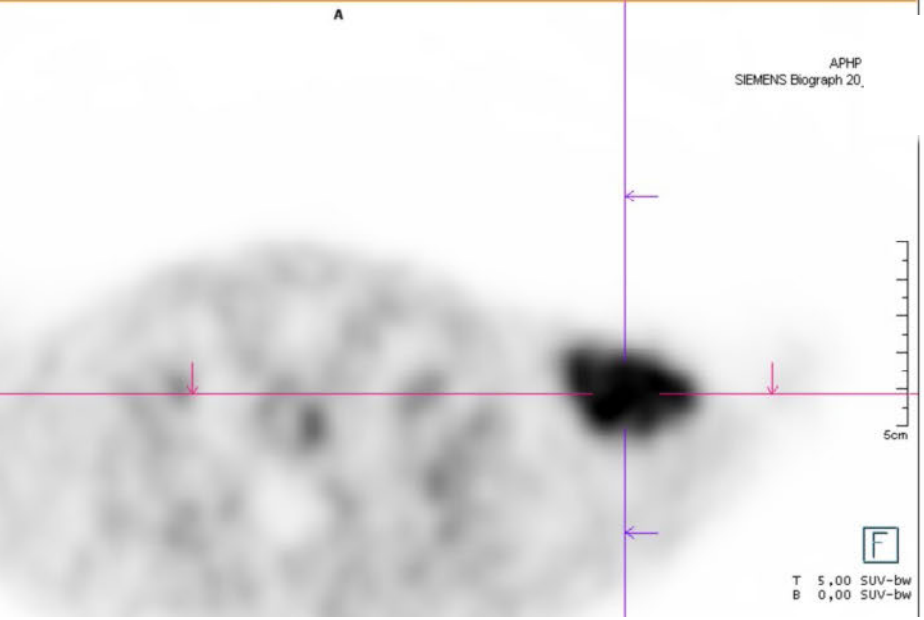
APHP
SIEMENS Biograph 20
RP
5cm
F
T 5,00 SUV~bw
B 0,00 SUV~bw

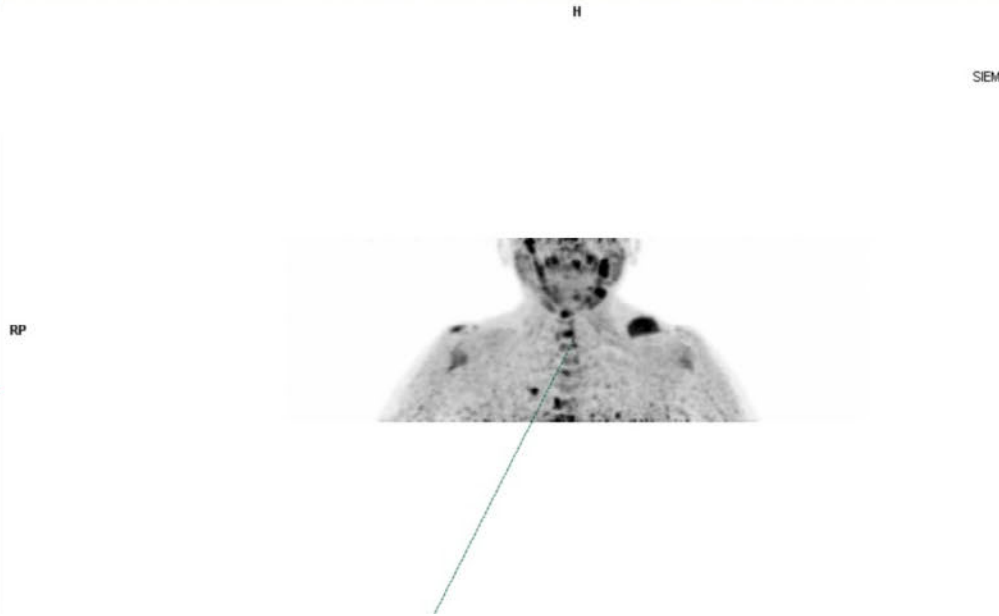
SIEM

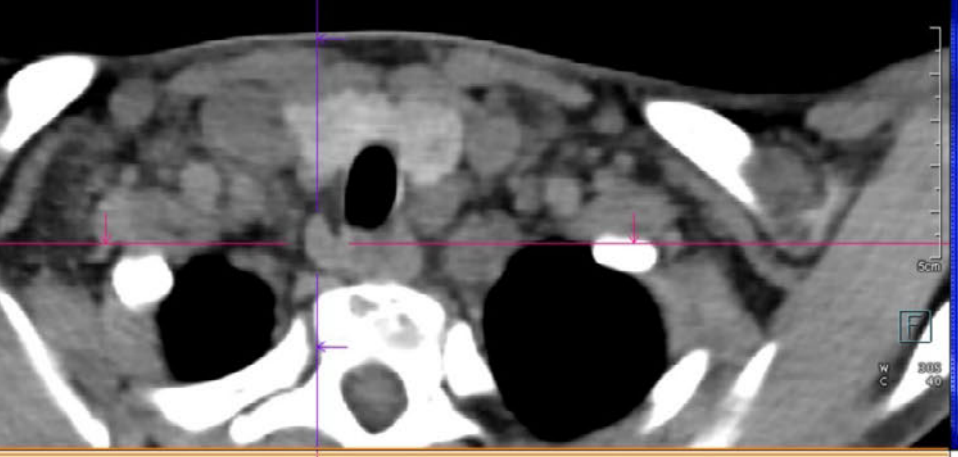

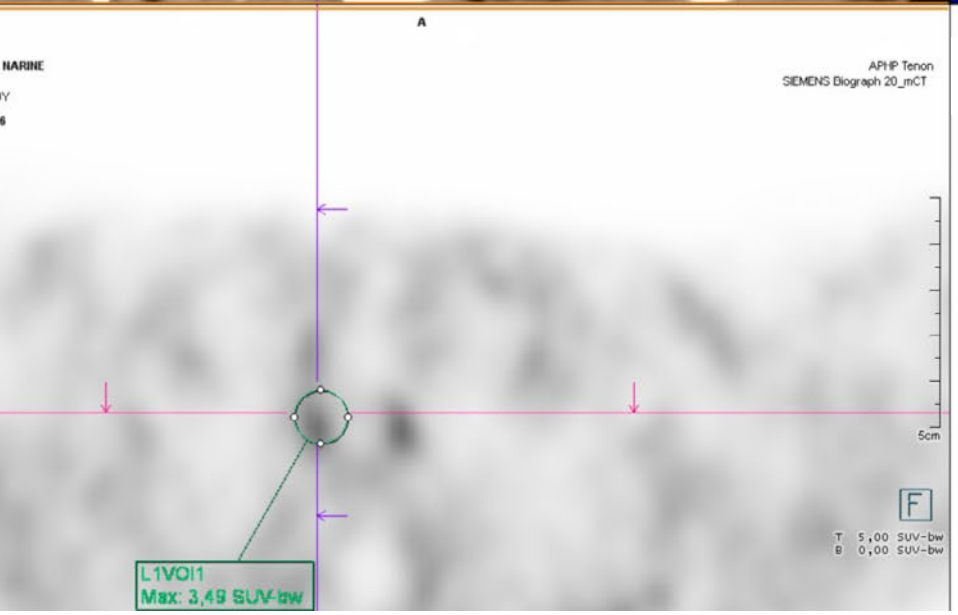

Mais aussi des Ganglions Récurentiels ?

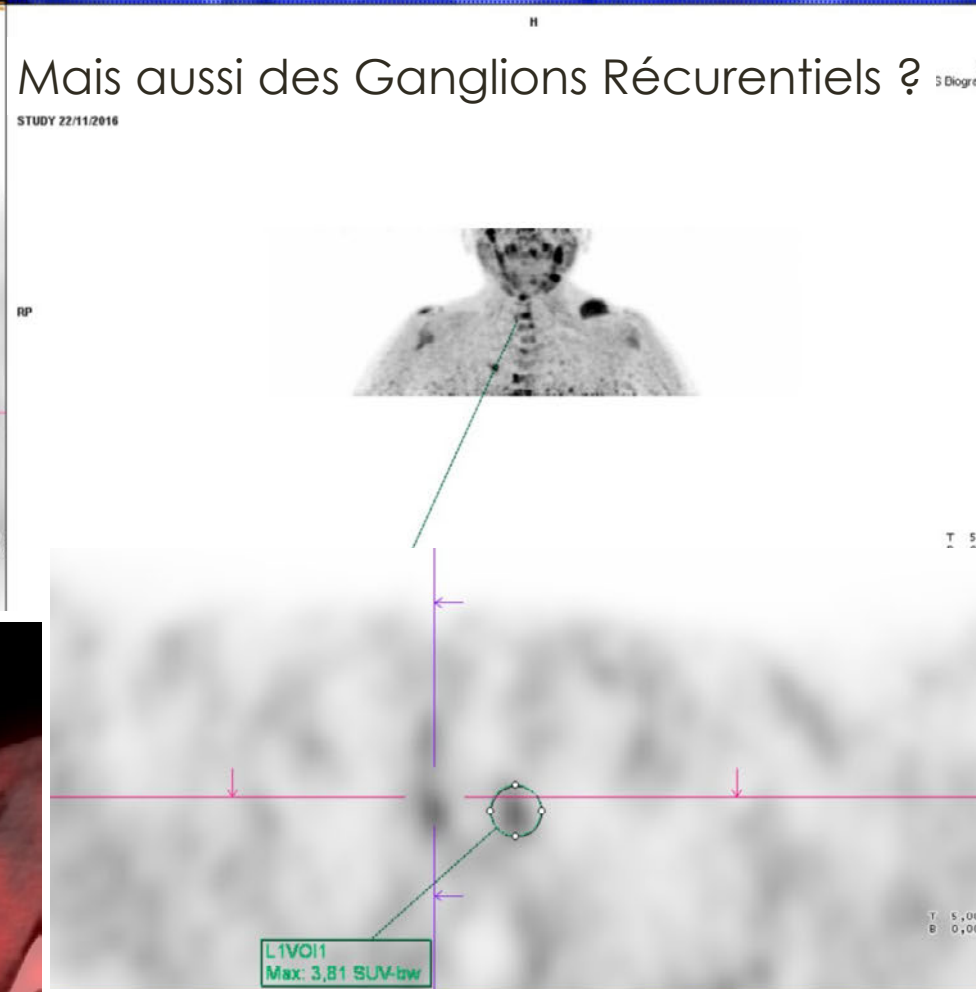

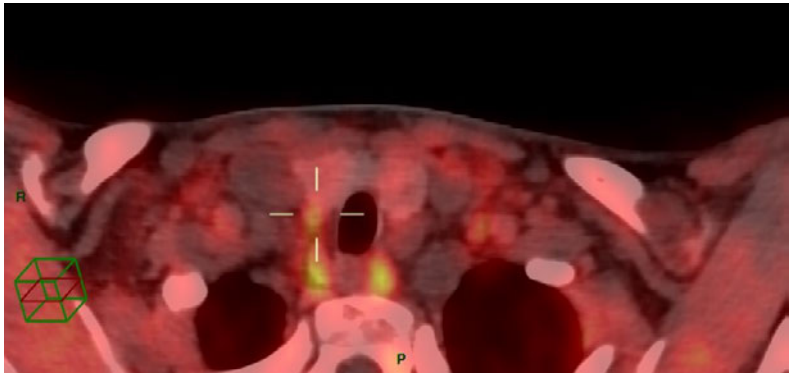

Prise en charge:

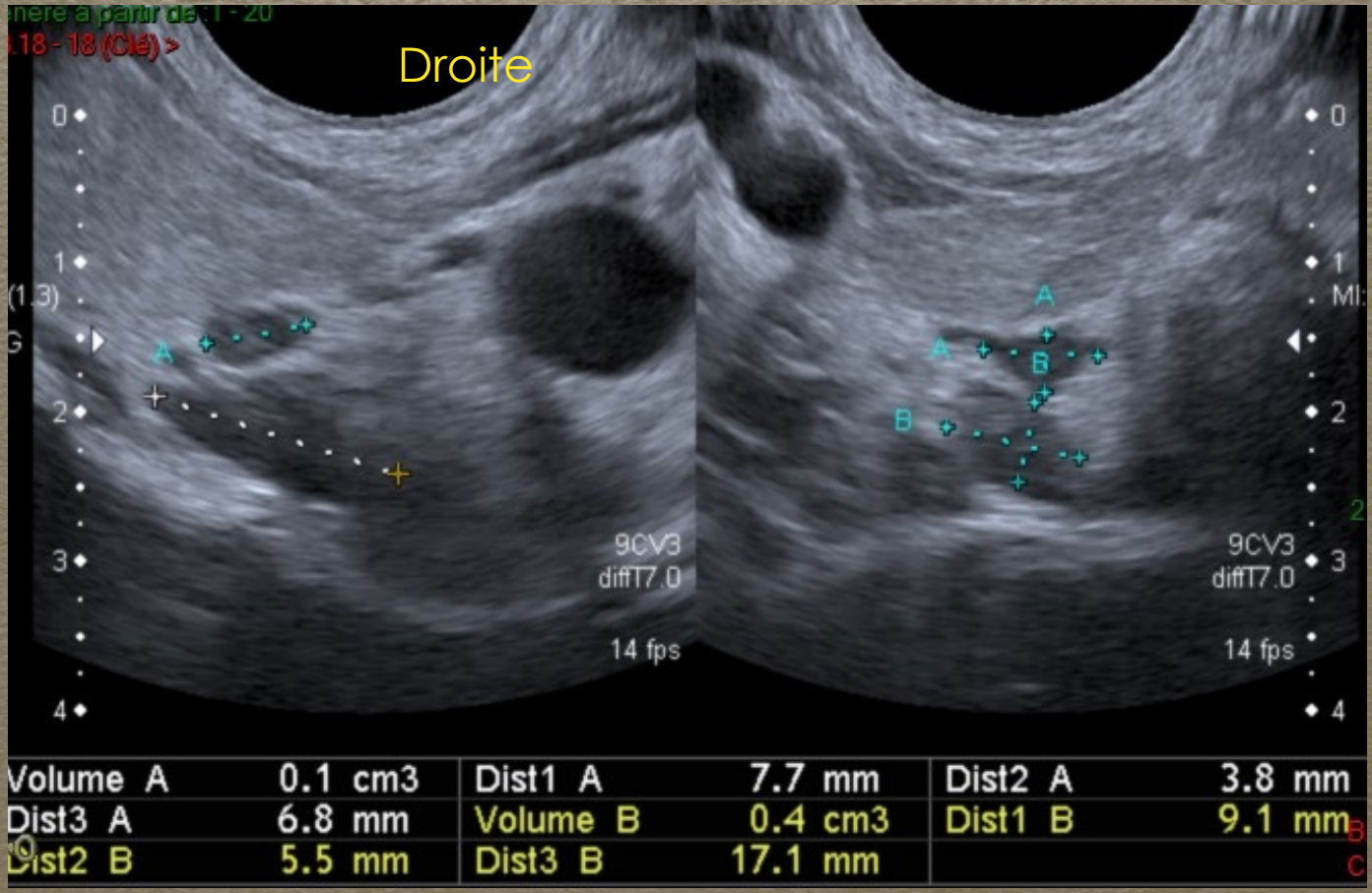

Monitorage,

PARATHYROIDECTOMIE des 3/4, en laissant la PTH inf D, de D à G

Oliveira FM. Regression of orbital brown tumor after surgical removal of parathyroid adenoma. Arch Endocrinol Metab. 2015 Oct;59(5):455-9.

Prise en charge:

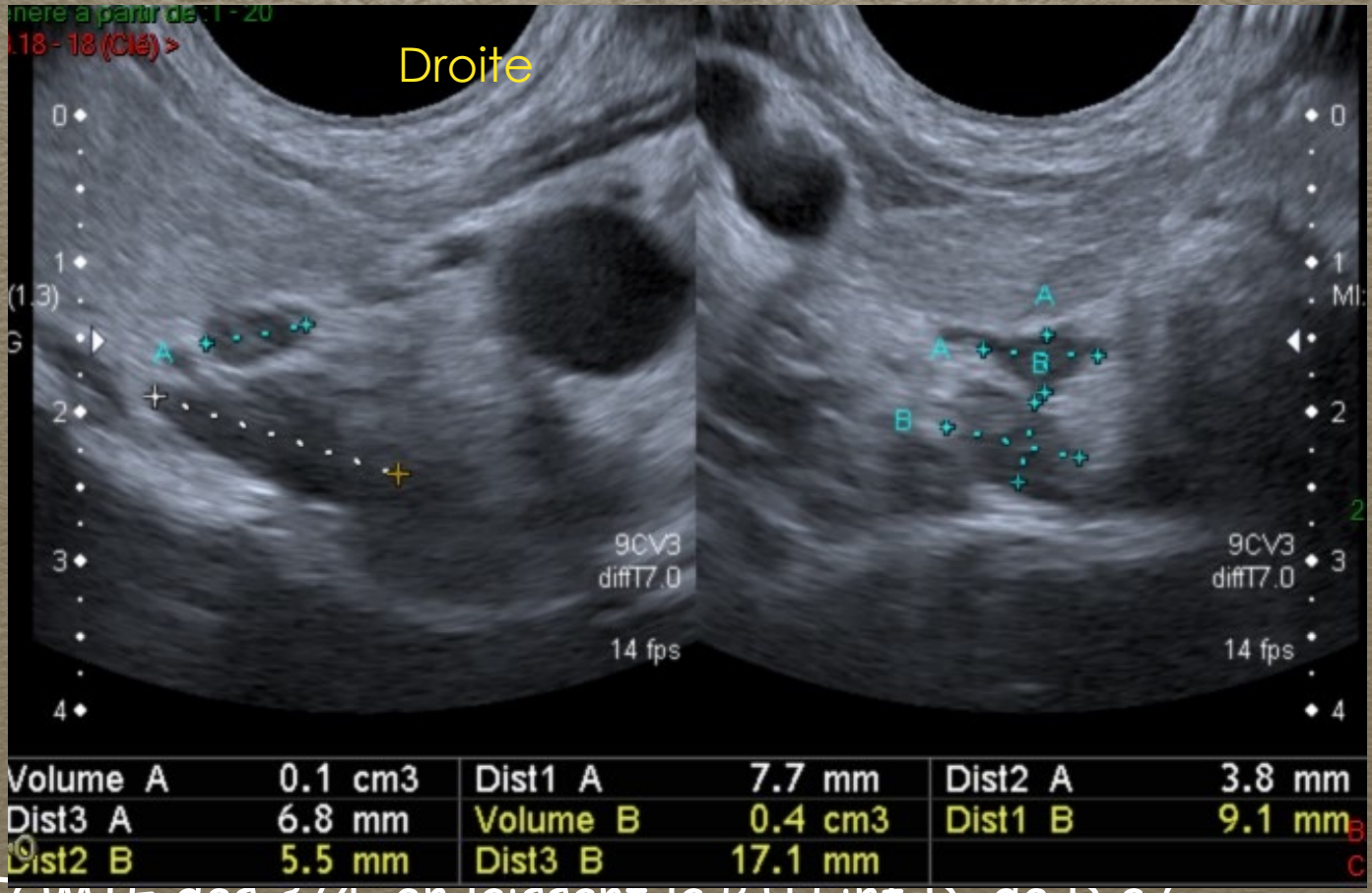

Monitorage,

PARATHYROIDECTOMIE des 3/4, en laissant la PTH inf D de D à G

Histologie: Hyperplasie des 3PTx

PTH J1 1000, ca élevé

Que décider?

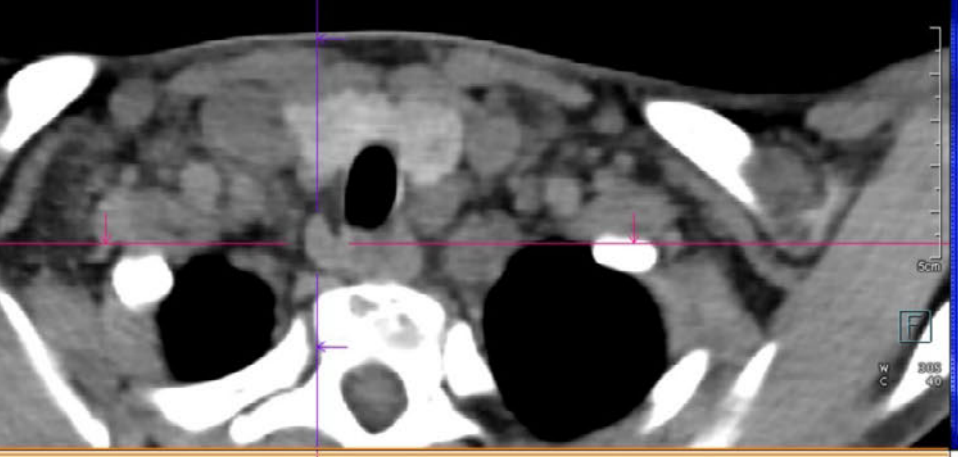

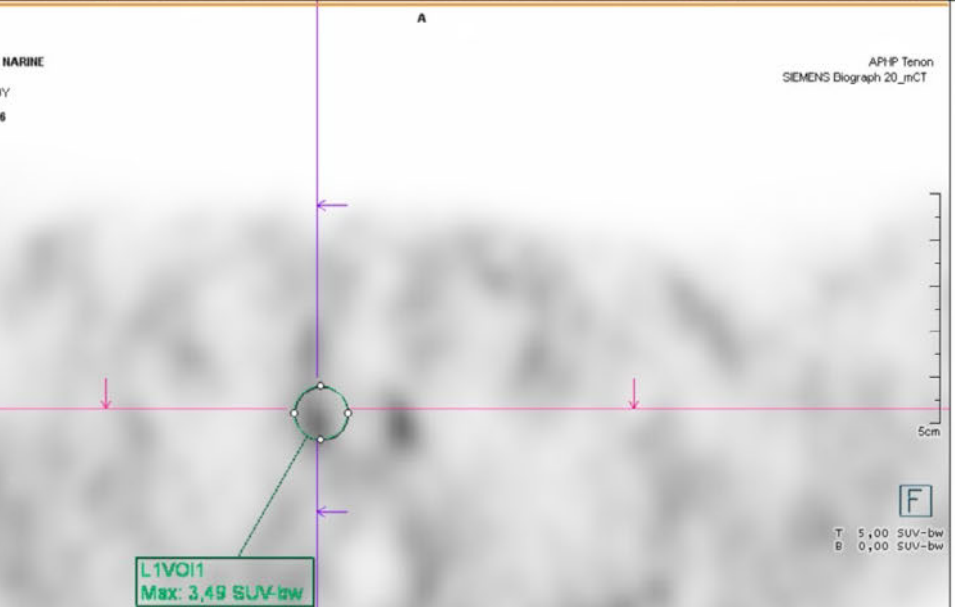

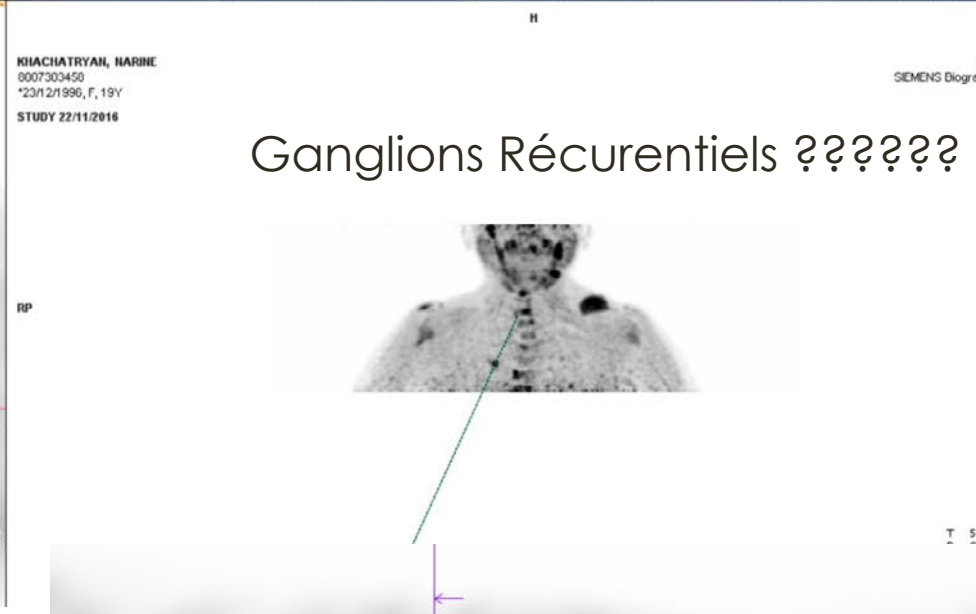
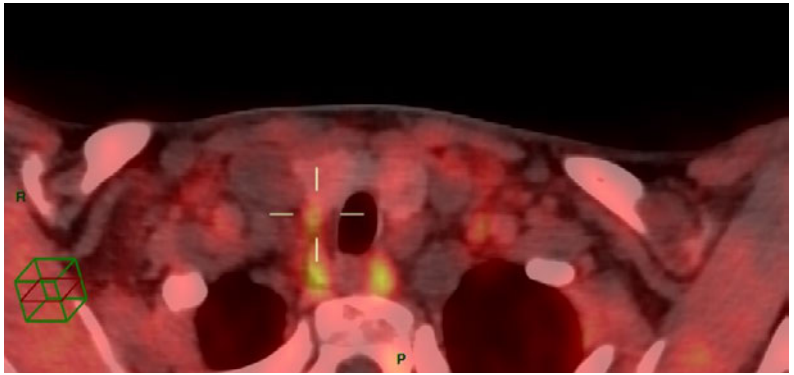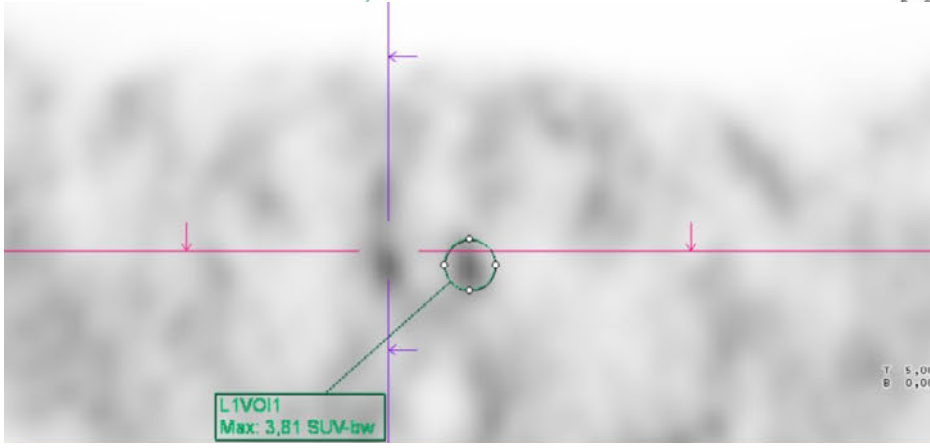
Ganglions Récurentiels ??????