eshnr

european society of
head and neck radiology

ESHNR 2015

28th Annual Meeting and Refresher Course

September 24–26, 2015, Krakow, Poland

FINAL PROGRAMME

www.eshnr.eu



Gala Dinner

Friday, September 25, 2015, 19:30 I Wieliczka Salt Mine

Join us for an extraordinary night 135 meters under sea level!

The “Wieliczka Salt Mine” is one of the most visited historical monuments of Poland and also featured on the UNESCO’s World Cultural and Natural Heritage List.

In the middle of salt lakes and sculptures, the dinner will take place in the breathtaking Haluszka chamber.

There will be a shuttle service from the congress venue to the salt mine and back. **Buses will leave at 19:00 from the Holiday Inn Hotel.**

Dress code: casual elegant

“Wieliczka Salt Mine” | ul. Daniłowicza 10 | 32-020 Wieliczka

Important Information:
As the Gala Dinner takes place in such a special location 135 meters under sea level, please consider the following points:
- Please do not use high heels.
- If you tend to be claustrophobic or don’t like narrow rooms you should reconsider your participation at the Gala Dinner.

INDEX

ESHNR 2015

28th Annual Meeting and Refresher Course

Welcome Reception

Thursday, September 24, 2015
Holiday Inn Krakow City Center

18:00 Foyer & exhibition area

We cordially invite you to the ESHNR 2015 Welcome Reception, which starts subsequently to the scientific programme. Snacks and drinks will be served in the foyer and the exhibition area at the Holiday Inn Krakow City Center for participants of ESHNR 2015. Take the chance and get in touch with experts and colleagues from Europe and from all over the world.

We are looking forward to seeing you!

DEAR COLLEAGUES AND FRIENDS,

On behalf of the European Society of Head and Neck Radiology (ESHNR), it is a great privilege for me to welcome you to the 28th Annual Meeting and Refresher Course in Krakow.

Since its establishment, the ESHNR has been highly successful in teaching state-of-the-art Head and Neck Radiology. This year, our scientific programme has again been carefully designed to address the needs and interests of both, beginners and experts in Head and Neck Radiology.

The 28th Annual Meeting and Refresher Course offers keynote speeches, panels, symposia, scientific sessions, posters, instruction courses and lunch with the lecturers, providing an outstanding opportunity for individual interaction during this two and a half day meeting. For Head and Neck surgeons, residents, research scientists and specialists from all allied fields, this memorable event will present cutting edge knowledge in Head and Neck Radiology. A particular highlight will be the "ESHNR boys vs. girls quiz session" where two teams of radiologists will compete against each other in image interpretation.

Besides the meeting, I hope you will have the opportunity to explore the city. Krakow is the second largest city in Poland and is rich in history. The old town of Krakow is vibrant with lots of restaurants, bars, museums, parks and river side walks along the Vistula river with plenty for the visitor to do.

Moreover, I would like to express my sincere appreciation to the Scientific- and Organising Committee for their hard work, to all speakers and moderators who kindly accepted to contribute to this outstanding event as well as for the support of my colleagues.

Sincerely Yours,

Agnieszka Trojanowska
Meeting President
ESHNR 2015 – 28th Annual Meeting and Refresher Course

Honorary patronage: His Magnificence Rector of the Medical University in Lublin, Prof. Andrzej Drop

PRESIDENT & COMMITTEES

Congress President

A. Trojanowska, Lublin/PL

Local Organising Committee

B. Bobek-Billewicz, Gliwice/PL
E. Czekajska-Chehab, Lublin/PL
M. Członkowski, Lublin/PL
A. Drop, Lublin/PL
L. Grzycka-Kowalczyk, Lublin/PL
A. Koltowska, Wroclaw/PL
M. Nózka-Kozik, Lublin/PL
P. Trojanowski, Lublin/PL
A. Urbanik, Krakow/PL

Scientific Committee

M. Becker, Geneva/CH
S. Bisdas, Tübingen/DE
B. Bobek-Billewicz, Gliwice/PL
J.W. Casselman, Bruges/BE
J.A. Castelijns, Amsterdam/NL
C. Czerny, Vienna/AT
H.B. Eggesbø, Oslo/NO
N.J.M. Freling, Amsterdam/NL
B. Hendrich, Wroclaw/PL
M.G. Mack, Munich/DE
R. Maroldi, Brescia/IT
J. Olliff, Birmingham/UK
B. Ozgen Mocan, Ankara/TK
M. Sasiadek, Wroclaw/PL
A. Trojanowska, Lublin/PL
A. Varoquaux, Marseille/FR
F. Veillon, Strasbourg/FR
B. Verbist, Leiden/NL

FACULTY

G. Atay, Ankara/TR
T. Beale, London/UK
M. Becker, Geneva/CH
S. Bisdas, Tübingen/DE
B. Bobek-Billewicz, Gliwice/PL
A. Borges, Lisbon/PT
J.W. Casselman, Bruges/BE
J.A. Castelijns, Amsterdam/NL
V. Chong, Singapore/SG
C. Czerny, Vienna/AT
B. de Foer, Antwerp/BE
F. Dubrulle, Lille/FR
H.B. Eggesbø, Oslo/NO
D. Farina, Brescia/IT
L. Ginsberg, Houston/US
S. Golding, Oxford/UK
P. Golusinski, Poznan/PL
L. Grzycka-Kowalczyk, Lublin/PL
H.F. Harnsberger, Utah/US
H. Imhof, Vienna/AT
T. Jargiello, Lublin/PL
C.Z. Karaman, Aydin/TR
A. King, Hong Kong/HK
R. Kohler, Sion/CH
S. Kösling, Halle a.d. Saale/DE
S. Langner, Greifswald/DE
M. Lemmerling, Beervelde/BE
M. Lemort, Louvain-la-Neuve/BE
R. Lingam, London/UK
E. Loney, Bradford/UK
M.G. Mack, Munich/DE
A. Maliborski, Warsaw/PL
R. Maroldi, Brescia/IT
N. Martin-Duverneuil, Paris/FR
I. Noebauer-Huhmann, Vienna/AT
J. Olliff, Birmingham/UK
B. Ozgen Mocan, Ankara/TR
F. Pameijer, Utrecht/NL
B.S. Purohit, Singapore/SG
K. Pyra, Lublin/PL
M. Ravanelli, Brescia/IT
S. Robinson, Vienna/AT
S. Rohde, Dortmund/DE
M. Sasiadek, Wroclaw/PL
B. Schuknecht, Zurich/CH
K. Skladowski, Gliwice/PL
M. Szymanski, Lublin/PL
A. Trojanowska, Lublin/PL
P. Trojanowski, Lublin/PL
F. Veillon, Strasbourg/FR
B. Verbist, Leiden/NL
J. Walecki, Warsaw/PL

GENERAL INFORMATION

Onsite Congress Office

In case of any questions, kindly consult the ESHNR registration desk, staff members will be happy to assist you.

Registration/Badge/Tickets

You receive your badge and the final programme at the registration counter onsite. You are kindly asked to wear your badge visibly on the congress grounds at all time.
Pre-ordered evening event tickets will be handed out additionally to the congress badges. Evening event tickets may be purchased onsite at the registration desk upon availability.

Certificate of Attendance

The Certificate of Attendance/CME Accreditation can be viewed and printed after the congress upon entering your ESHNR MyUserArea at the ESHNR website (www.eshnr.eu). To enter your MyUserArea, please use your lastname in combination with your personal ID printed on your congress badge.

CME Credits

Continuing Medical Education (CME) is a programme of educational activities to guarantee the maintenance and upgrading of knowledge, skills and competence following completion of postgraduate training. CME is an ethical and moral obligation for each radiologist throughout his/her professional career, in order to maintain the highest possible professional standards.

The 28th Annual Meeting and Refresher Course of ESHNR is designated up to a maximum of 15 CME credits by the European Accreditation Council for Continuing Medical Education (EACCME). Each medical specialist should only claim those hours of credit that he/she actually spent in the educational activity

Conference Language

The meeting will be held in English and no simultaneous translation will be offered.

Onsite Registration Fees

ESHNR Members*	€ 450.00
ESHNR Non-Members	€ 585.00
Residents in training**	€ 330.00
Single Day Ticket***	€ 310.00

* only available if the ESHNR 2015 membership is paid
**requires confirmation of the institution's head by way of proof
***only available once per person/ registration

Fee includes: admittance to scientific sessions and exhibition, final programme including book of abstracts, refreshments during coffee breaks, welcome reception, certificate of attendance and opening ceremony.

Payment

Onsite payment can only be made by credit card (Visa or Euro/Mastercard) or in cash (Euro). Please understand that no other payment facilities like debit cards, cheques, etc. will be accepted.

Congress Venue

Holiday Inn Krakow City Center
ul. Wielopole 4
31-072 Krakow/Poland
Phone: +48 12 619 00 00

Disclaimer/Liability

The Education Congress and Research GmbH/ ESHNR cannot accept any liability for the acts of the suppliers to this meeting or the attendees‘ safety while travelling to or from the congress. All participants and accompanying persons are strongly advised to carry adequate travel and health insurance, as ECR GmbH/ ESHNR cannot accept liability for accidents or injuries that may occur. ECR GmbH/ ESHNR is not liable for personal injury and loss or damage of private property.

Name Changes

Name changes will be treated like the cancellation of the registration and a new registration of the other participant.

Mobile Phones

Please do not forget to switch off your mobile phones before entering any of the lecture rooms.

Organising Secretariat

ESHNR Office
Neutorgasse 9
1010 Vienna, Austria
Phone: +43 1 532 21 91
Fax: +43 1 532 21 91 445
office@eshnr.eu
www.eshnr.eu

Education Congress Research GmbH
Neutorgasse 9
1010 Vienna, Austria
Phone: +43 1 533 40 64
Fax: +43 1 533 40 64 448

Media Center

Speakers are reminded to check in at the Media Center at least two hours prior to their scheduled presentation. Trained staff will be available to assist you with the equipment. The Media Center should only be used for a test run of the presentation(s). Please note that the Media Center should not be used to prepare your entire presentation(s) and that due to the large number of speakers the workstations are only available for minor editing.

Opening Hours

Thursday, September 24	07:30 – 18:00
Friday, September 25	07:30 – 18:00
Saturday, September 26	07:30 – 13:00

Registration Opening Hours

Wednesday, September 23	15:00 – 17:00
Thursday, September 24	07:30 – 18:00
Friday, September 25	07:30 – 18:00
Saturday, September 26	07:30 – 13:00

Poster Exhibition – EPOS™

ESHNR 2015 is using the EPOS™ system, Electronic Presentation Online System, the electronic format of the scientific exhibition developed by the European Congress of Radiology (ECR). EPOS™ offers a much greater flexibility than traditional scientific exhibits and provides better options for scientific communication.

EPOS™ Area

Several workstations are available in the EPOS™ Area at which the current electronic exhibits can be viewed by the congress participants during the congress. All ESHNR electronic posters will be accessible online after the congress via the ESHNR website.

Opening Hours

Thursday, September 24	09:00 – 18:00
Friday, September 25	08:00 – 18:00
Saturday, September 26	08:00 – 12:00

NEW: Connect your own mobile device and browse through ESHNR 2015 posters:
http://posters.webges.com/eshnr2015/e-poster

ESHNR Awards

ESHNR awards the following prizes:
€ 750.00 for the best oral presentation
€ 750.00 for the best scientific poster presentation
€ 300.00 for the best educational poster

Free registration to ESHNR 2016 – 29th Annual Meeting and Refresher Course for the second best oral presentation and second best scientific poster presentation.

Industry Exhibition

The industry exhibition area is located in the foyer of the ground floor.

Opening Hours

Thursday, September 24	09:00 – 18:00
Friday, September 25	09:00 – 18:00
Saturday, September 26	09:00 – 13:00

Breaks

Complimentary coffee, tea and refreshments will be served during the official coffee breaks to all congress delegates.

Future Meeting Desk

This area – located in the foyer of the ground floor – offers you an overview of future meetings in the field of radiology and related disciplines, from all over the world. Feel free to contribute flyers and posters to promote your own meetings and courses.

Welcome Reception

On behalf of the meeting president Agnieszka Trojanowska, the local Organising Committee and the Executive Committee of ESHNR, we would like to cordially invite you to join the Welcome Reception in the foyer and exhibition area on Thursday, September 24, 2015. The Welcome Reception starts at the end of the scientific programme.

Gala Dinner

Join us on Friday, September 25, 2015, at 19:30 (buses will leave at 19:00 from the congress venue) for an extraordinary night at the “Wieliczka Salt Mine”, 135 meters under sea level. As one of the most visited monuments of Poland, it is also featured on the UNESCO’s World Cultural and Natural Heritage List.

Tickets are limited – price per ticket is set at EUR 55.00.

Dresscode: casual elegant (no high heels)

Guideline for Speakers

The Media Center is located on the ground floor next to the exhibition area.

- You are kindly requested to submit your presentation two hours before your session starts at the latest (USB sticks are recommended).
- All presentations have to be uploaded to the conference IT-system. No personal computer will be accepted for presentation.
- Please be at the lecture room at the latest five minutes prior to the start of your session and identify yourself to the moderators.
- Kindly observe exactly your presentation time. Each session contains enough time for discussion. Exceeding the time limit will not be accepted and the chairpersons are requested to stop presentations in such cases.

Recording

Video- or audio-recording of any sessions or presentations is not allowed without the speaker's/organiser's prior written permission.

Diploma Examination

The European Board in Head and Neck Radiology Diploma takes place on Friday, September 25, 2015, in room Gaugin I, located on the ground floor. Only for pre-registered persons!

Industry Symposia

Thursday, September 24, 2015, 13:30 – 14:30

Olea Medical — Room 1

"The wet tumour": unraveling intravoxel incoherent motion imaging in head and neck oncology
S. Bisdas, Tübingen/DE

Olea Medical
Improved diagnosis for life™

Friday, September 25, 2015, 13:30 – 14:30

GE Healthcare — Room 1

PET/MR in head and neck cancer
M. Hüllner, Lucerne/CH

GE Healthcare

Attendees of any industry symposium agree that their registration details will be forwarded to the company organising that symposium. This agreement may be cancelled at any time by writing to the ESHNR Office.

KRAKOW INFORMATION

Restaurants

Restaurant Wierzynek €€€

Rynek Glowny 16

With a tradition going all the way back to 1364, this restaurant has become something of an Old Town's landmark in its own. Thanks to its exquisite traditional Polish cuisine, perfectly trained staff, elegance and timeless charm, Wierzynek was appreciated as the best restaurant in Krakow by the prestigious Michelin Red Guide 2008. The restaurant was also mentioned in the American bestseller "1000 Places to See Before You Die" as a place that is definitely worth a visit.

Restaurant Hawelka €€€

Rynek Glowny 34

Hawelka is something of a Cracovian institution. Founded in 1876, this is an elegant, rather formal throwback to the twilight years of the Austro Hungarian Empire. A stately portrait of the Emperor Franz Josef adorns the walls, resplendent with his legendary bushy whiskers – Hawelka hails from that golden epoch when the Austrians and Poles put aside their differences and Cracow regained its status as Poland's cultural capital.

Restaurant Pod Baranem €€

ul. sw. Gertrudy 21

Pod Baranem may have some old-fashioned touches here and there but it still feels fresh and relaxed, and unlike some other restaurants, you will actually find Poles eating here - a sure sign that Pod Baranem has got it right.

U Vincenta €

ul. Józefa 11

This is paradise for the connoisseurs of pierogi, the Polish cousins of Italian ravioli and Japanese gyoza. In a tiny interior with no room to twist a cat, young and friendly staff serve your pierogi in some two dozen variations, traditional and novel, savoury and sweet.

Krakow sights

Krakow has always been, in many respects, a charmed city. With a history that dates back to the 4th century settlement of Wawel Hill, Krakow has fortuitously avoided destruction since the pesky Mongols stopped bullying the area in the 13th century, growing into one of the most prominent cities in Central Europe. Krakow is today one of the most beautiful showpieces of Eastern Europe – a claim validated by its historic centre's inclusion on the first ever UNESCO World Heritage List in 1978, along with the nearby Wieliczka Salt Mine and only ten other places in the world.
A city of majestic architectural monuments, cobbled thoroughfares, cultural treasures, timeless courtyards, priceless artworks and legendary beer cellars and gardens, Krakow's historic centre is the pride of Poland.

What To See

Krakow's centre can be divided into two main sections – the Old Town and Kazimierz (the former Jewish Quarter), with Wawel (the former Royal Castle) towering between them.

Just west of the Old Town lies Salwator – Krakow's greenest district, and home to one of its most unique outdoor attractions, Kosciuszko Mound. Also consider visiting Nowa Huta, one of only two planned socialist realist cities ever built.

Rynek Glowny

All roads in the Old Town lead to the 14th century market square. One of Europe's grandest and largest open spaces it's 200m by 200m and hosts nearly all the city's major festivals, parades and jamborees.

Cloth Hall, St Mary's Church and the Town Hall Tower

These are the Rynek's three big draws. Its centrepiece is the Cloth Hall lending a sense of balance to the square so it never feels too big and next to it, guarded by lions, is the Town Hall Tower. Rising majestically over the northeastern corner of the square is St. Mary's Church with its two towers of differing heights. Listen out for the hejnal (medieval bugle call warning) every hour.

Wawel Hill

You could spend a day here exploring the complex of castle, cathedral, museums and underground lairs that make up Wawel Hill. Once the coronation spot for kings and queens, it's the city's number one tourist destination. The castle features royal and state apartments and an armoury, the cathedral with its mixture of Gothic and Renaissance styles houses the tombs of Poland's royal dynasties.

FLOORPLAN

Holiday Inn Krakow City Centre

Ground Floor *-2 Floor*

PROGRAMME OVERVIEW

Thursday, September 24, 2015

	Room 1	Room 2
08:00		
08:30	Opening ceremony	
09:00	Scientific session 1 Modern diagnostic approach to head and neck cancer	Scientific session 2 Temporal bone: Not so easy
09:30		
10:00		
10:30	Coffee break	
11:00	Scientific session 3 Tumour board session: The changing face of head and neck cancer	Scientific session 4 Temporal bone: Not so often seen
11:30		
12:00		
12:30	Short oral presentation session 1 Temporal bone	Short oral presentation session 2 Head and neck cancer
13:00		
13:30	Industry sponsored symposium	
14:00		
14:30	Scientific session 5 The risk of recurrence – Case based session	Scientific session 6 Temporal bone: Not so obvious
15:00		
15:30		
16:00	Coffee break	
16:30	Interactive teaching session 1 Cases of head & neck cancer	
17:00		
17:30		
18:00	Welcome reception	

Friday, September 25, 2015

	Room 1	Room 2
08:00	Refresher course 1 – Imaging of nasopharynx	
08:30	Refresher course 2 – Imaging of the anterior and central skull base	
09:00	Scientific session 7 Soft tissues of the neck	Scientific session 8 Orbit and eye
09:30		
10:00		
10:30	Coffee break	
11:00	Scientific session 9 Neck vessels and nerves	Scientific session 10 Paranasal sinuses
11:30		
12:00		
12:30	Short oral presentation session 3 Brain, skull base & face	Short oral presentation session 4 Various
13:00		
13:30	Industry sponsored symposium	
14:00		
14:30	Image interpretation quiz	
15:00		
15:30	Coffee break	
16:00	Interactive teaching session 2 Head and neck is not only about cancer	
16:30		
17:00		
17:30		
	ESHNR General assembly	
18:00		
19:30	Gala dinner	

Saturday, September 26, 2015

	Room 1	Room 2
08:00	Refresher Course 3 – Imaging of the jaws and TMJ	
08:30	Refresher Course 4 – Imaging of the masticator space	
09:00	Special lecture 1 Disasters of the masters	Refresher course 5 – Imaging of the parapharyngeal space
09:30		Refresher course 6 – Pitfalls in head and neck imaging
10:00		Refresher course 7 – Imaging of the oropharynx
10:30	Coffee break	
11:00	Special lecture 2 Beyond morphology: Exploring squamous cell carcinoma properties with functional imaging	Scientific Session 11 Salivary glands
11:30		
12:00		
12:30	Closing ceremony	
13:00		
13:30		
14:00		
14:30		
15:00		
15:30		
16:00		
16:30		
17:00		
17:30		
18:00		

PROGRAMME THURSDAY, SEPTEMBER 24, 2015

08:45		**Opening ceremony** *A. Trojanowska, Lublin/PL*	**Room 1**
09:00–10:30	**SS 1**	**Modern diagnostic approach to head and neck cancer** *M.G. Mack, Munich/DE; H.F. Harnsberger, Utah/US*	**Room 1**
09:00	SS 1.1.	CT *A. Trojanowska, Lublin/PL*	
09:30	SS 1.2.	MRI *R. Maroldi, Brescia/IT*	
10:00	SS 1.3.	PET-CT and PET-MRI *M. Becker, Geneva/CH*	
09:00–10:30	**SS 2**	**Temporal bone: Not so easy** *E. Loney, Bradford/UK; M. Szymanski, Lublin/PL*	**Room 2**
09:00	SS 2.1.	Conductive hearing loss in patients with intact tympanic membrane *E. Loney, Bradford/UK*	
09:30	SS 2.2.	7 Tesla imaging of the inner ear *B. Verbist, Leiden/NL*	
10:00	SS 2.3.	How to evaluate a cholesteatoma? *B. de Foer, Antwerp/BE*	
10:30–11:00	*Coffee break*		
11:00–12:30	**SS 3**	**Tumour board session: The changing face of head and neck cancer** *B. Schuknecht, Zurich/CH; P. Trojanowski, Lublin/PL*	**Room 1**
11:00	SS 3.1.	HPV connection *L. Ginsberg, Houston/US*	
11:20	SS 3.2.	Current trends for non-surgical treatment *K. Skladowski, Gliwice/PL*	
11:40	SS 3.3.	Working together: Tumour board cases (Panel discussion) *K. Skladowski, Gliwice/PL* *P. Golusinski, Poznan/PL* *P. Trojanowski, Lubin/PL* *B. Bobek-Billewicz, Gliwice/PL* *L. Ginsberg, Houston/US* *R. Maroldi, Brescia/IT*	

11:00–12:30	**SS 4**	**Temporal bone: Not so often seen** *V. Chong, Singapore/SG; E. Loney, Bradford/UK*	**Room 2**
11:00	SS 4.1.	Congenital anomalies of the temporal bone *B. Ozgen Mocan, Ankara/TR; G. Atay, Ankara/TR*	
11:25	SS 4.2.	Skull base and brain lesions affecting temporal bone *J.W. Casselman, Bruges/BE*	
11:50	SS 4.3.	Petrous apex lesions: Diagnostic approach *D. Farina, Brescia/IT*	
12:15	SS 4.4.	Menière and endolymphatic hydrops *F. Veillon, Strasbourg/FR*	

12:30–13:30	**SOPS 1**	**Temporal bone** *J. Olliff, Birmingham/UK; B. Bobek-Billewicz, Gliwice/PL*	**Room 1**
12:30	SOPS 1.1.	Interpreting non-echoplanar diffusion weighted images in post-operative cholesteatoma: Navigating past the pitfalls *R. Lingam, London/UK*	
12:40	SOPS 1.2.	Describing cochlear size and morphology using an automatic tracing method to determine cochlear walls and the course of the scala tympani *A.M. van der Jagt, Leiden/NL*	
12:50	SOPS 1.3.	CT visualisation of the Eustachian Tube using focal contrast administration: A feasibility study *B. Falkenberg-Jensen, Oslo/NO*	
13:00	SOPS 1.4.	Fractures of the temporal bone: An easier way to read your CT *A. Venkatasamy, Strasbourg/FR*	
13:10	SOPS 1.5.	Role of mastoid pneumatization in temporal bone fractures: What really protect? *H. Kim, Anyang/KR*	
13:20	SOPS 1.6.	Does non-echo planar Diffusion Weighted MRI perform better in adults than in children in detecting post-operative cholesteatoma? *R. Lingam, London/UK*	

12:30–13:30	**SOPS 2**	**Head and neck cancer** *S. Kösling, Halle a.d. Saale/DE; C.Z. Karaman, Aydin/TR*	**Room 2**
12:30	SOPS 2.1.	Diagnostic accuracy of non-contrast and contrast-enhanced MRI in assessing cartilaginous infiltration by laryngeal tumours *L. Preda, Milan/IT*	
12:40	SOPS 2.2.	SPECT scanning and parathyroid surgery in the Southern Trust, Northern Ireland *D. Neeson, Belfast/UK*	
12:50	SOPS 2.3.	HIV- associated facial lipoatrophy: evaluation of tissue morphology before and after injection of hyaluronic acid filler with MRI *A. Ailianou, Geneva/CH*	
13:00	SOPS 2.4.	Impact of combined FDG-PET/CT and MRI on detection of recurrent thyroid cancer and nodal metastases *J.-M. Hempel, Tübingen/DE*	
13:10	SOPS 2.5.	US diagnosis of micro medullary thyroid carcinoma mMTC *P.Y. Marcy, Ollioules/FR*	
13:20	SOPS 2.6.	Perineural spread of head and neck tumours detected by MDCT and MRI *S. Petrovic, Nis/RS*	

13:30–14:30	*Industry sponsored symposium*	*Room 1*

14:30–16:00	**SS 5**	**The risk of recurrence – Case based session** *S. Rohde, Dortmund/DE; D. Farina, Brescia/IT*	**Room 1**
14:30	SS 5.1.	Follow-up for surgically treated patients *R. Lingam, London/UK*	
14:55	SS 5.2.	Follow-up after chemo-radiotherapy: The power of imaging studies *F.A. Pameijer, Utrecht/NL*	
15:20	SS 5.3.	Recurrence or expected findings? (Panel discussion) *L. Ginsberg, Utah/US* *P. Trojanowski, Lublin/PL* *B.S. Purohit, Singapore/SG*	

14:30–16:00	**SS 6**	**Temporal bone: Not so obvious** *J. Walecki, Warsaw/PL; M. Lemmerling, Beervelde/BE*	**Room 2**
14:30	SS 6.1.	CN VII palsy *B. Verbist, Leiden/NL*	
14:55	SS 6.2.	Temporal bone trauma and its complications *V. Chong, Singapore/SG*	
15:20	SS 6.3.	Contemporary imaging issues in pulsatile and non-pulsatile tinnitus *H.F. Harnsberger, Utah/US*	
16:00–16:30	*Coffee break*		
16:30–18:00	**IS 1**	**Interactive teaching session**	**Room 1**
	IS 1.1.	Cases of head & neck cancer *H.F. Harnsberger, Utah/US*	

PROGRAMME FRIDAY, SEPTEMBER 25, 2015

08:00–08:30	**RC 1**	**Imaging of nasopharynx** *J.W. Casselman, Bruges/BE*	**Room 1**
08:30–09:00	**RC 2**	**Imaging of the anterior and central skull base** *A. Borges, Lisbon/PT*	**Room 1**
09:00–10:30	**SS 7**	**Soft tissues of the neck** *I. Noebauer-Huhmann, Vienna/AT; J.A. Castelijns, Amsterdam/NL*	**Room 1**
09:00	SS 7.1.	Congenital lesions of the neck *H. Imhof, Vienna/AT*	
09:30	SS 7.2.	Neck swelling *B. Schuknecht, Zurich/CH*	
10:00	SS 7.3.	MSK system lesions in the neck *I. Noebauer-Huhmann, Vienna/AT*	
09:00–10:30	**SS 8**	**Orbit and eye** *B. Verbist, Leiden/NL; M. Lemort, Louvain-la-Neuve/BE*	**Room 2**
09:00	SS 8.1.	Double vision and vision loss *M. Lemmerling, Beervelde/BE*	
09:30	SS 8.2.	Exophtalmus and enophtalmus *S. Langner, Greifswald/DE*	
10:00	SS 8.3.	Naso-lacrimal pathways: Diagnostic evaluation *A. Maliborski, Warsaw/PL*	
10:30–11:00	*Coffee break*		
11:00–12:30	**SS 9**	**Neck vessels and nerves** *S. Bisdas, Tübingen/DE; T. Jargiello, Lublin/PL*	**Room 1**
11:00	SS 9.1.	Vascular pathologies and related diseases *S. Rohde, Dortmund/DE*	
11:30	SS 9.2.	Neural pathologies including perideural spread *D. Farina, Brescia/IT*	
12:00	SS 9.3.	Unexpected findings: With tumours concerning carotid space *K. Pyra, Lublin/PL*	

11:00–12:30	**SS 10**	**Paranasal sinuses** *F. Dubrulle, Lille/FR; J.A. Castelijns, Amsterdam/NL*	**Room 2**
11:00	SS 10.1.	Unilateral opacification of a sinus: Diagnostic approach *H.B. Eggesbø, Oslo/NO*	
11:30	SS 10.2.	Chronic rhino-sinusitis: Understanding problem *L. Grzycka-Kowalczyk, Lublin/PL*	
12:00	SS 10.3.	Radiological evaluation for FESS *T. Beale, London/UK*	

12:30–13:30	**SOPS 3**	**Brain, skull base & face** *M. Sasiadek, Wroclaw/PL; E. Loney, Bradford/UK*	**Room 1**
12:30	SOPS 3.1.	Validating a threshold of ocular gaze deviation for the prediction of acute ischaemic stroke *E. Woo, Aylesbury/UK*	
12:40	SOPS 3.2.	Is migraine related with medial meningeal artery and spinous foramen caliber *H. Nalbant, Ankara/TR*	
12:50	SOPS 3.3.	Ambigous and surprising cases in jaw pathologies *B. Ruhin, Paris/FR*	
13:00	SOPS 3.4.	Pre- and postoperative multi-slice and cone-beam computed tomography in midface trauma *O. Pavlova, Moscow/RU*	
13:10	SOPS 3.5.	Evaluation of flow pattern of arteries in oral submucous fibrosis by colour Doppler ultrasonography *A. Chaurasia, Luckow/IN*	
13:20	SOPS 3.6.	Sex determination on the basis of Cephalometric forehead angulations *R. Patil, Luckow/IN*	

12:30–13:30	**SOPS 4**	**Various** *N. Martin-Duverneuil, Paris/FR; J. Olliff, Birmingham/UK*	**Room 2**
12:30	SOPS 4.1.	Importance of head and neck radiology training in clinical evaluation of new cancer cases in South-Eastern Sweden region *B. Kovacsovics, Linköping/SE*	
12:40	SOPS 4.2.	How accurate is conventional MRI in staging oral cavity carcinomas? *L. Ismail, London/UK*	
12:50	SOPS 4.3.	Absence/atrophy of the anterior belly of the digastric muscle *C. Bowles, Portsmouth/UK*	
13:00	SOPS 4.4.	Evaluating trabecular bone architecture quantitatively with roughness parameters *F. Yasar, Konya/TR*	
13:10	SOPS 4.5.	Knowledge, attitude and practices regarding biomedical and hazardous waste disposal among radiation workers *A. Tripathi, Lucknow/IN*	

13:30–14:30	*Industry sponsored symposium*	*Room 1*

14:30–15:30	**Image interpretation quiz boys vs. girls** *A. Trojanowska, Lublin/PL; C. Czerny, Vienna/AT* Boys team leader: M.G. Mack, Munich/DE Girls team leader: B. Ozgen Mocan, Ankara/TR	**Room 1**

15:30–16:00	*Coffee break*	

16:00–17:30	**IS 2**	**Interactive teaching session**	**Room 1**
	IS 2.1.	Head and neck is not only about cancer *H.F. Harnsberger, Utah/US*	

17:45	**ESHNR General assembly**	**Room 1**

PROGRAMME SATURDAY, SEPTEMBER 26, 2015

08:00–08:30	**RC 3**	**Imaging of the jaws and TMJ** *C. Czerny, Vienna/AT*	**Room 1**
08:30–09:00	**RC 4**	**Imaging of the masticator space** *C.Z. Karaman, Aydin/TR*	**Room 1**
09:00–10:30	**SL 1**	**Disasters of the masters** *L. Ginsberg, Houston/US, C. Czerny, Vienna/AT*	**Room 1**
09:00	SL 1.1.	My most unforgettable mistakes *L. Ginsberg, Houston/US*	
09:20	SL 1.2.	What I missed and why *M.G. Mack, Munich/DE*	
09:40	SL 1.3.	What I misinterpreted and why *R. Kohler, Sion/CH*	
10:00	SL 1.4.	How to deal with mistakes *S. Golding, Oxford/UK*	
09:00–09:30	**RC 5**	**Imaging of the parapharyngeal space** *B.S. Purohit, Singapore/SG*	**Room 2**
09:30–10:00	**RC 6**	**Pitfalls in head and neck imaging** *J. Olliff, Birmingham/UK*	**Room 2**
10:00–10:30	**RC 7**	**Imaging of the oropharynx** *A. Trojanowska, Lublin/PL*	**Room 2**
10:30–11:00	*Coffee break*		

11:00–12:30	**SL 2**	**Beyond morphology: Exploring squamous cell carcinoma properties with functional imaging** *A. King, Hong Kong/HK; R. Maroldi, Brescia/IT*	**Room 1**
		Part 1 – The basics	
11:00	SL 2.1.	Tumour cellularity, perfusion, hypoxia, necrosis, stromal burden, etc.. How signal changes on DCE, DWI, IVIM correlate with pathology? *S. Bisdas, Tübingen/DE*	
11:20	SL 2.2.	Peritumoral edema, early & late post-treatment healing and fibrosis. Which validation for DCE, DWI, IVIM? *M. Ravanelli, Brescia/IT*	
11:35	SL 2.3.	Can PET solve all these issues? *S. Bisdas, Tübingen/DE*	
		Part 2 – Which functional imaging parameters should we focus on for response prediction?	
11:50	SL 2.4.	What we know from current studies on DCE/DWI & IVIM *A. King, Hong Kong/HK*	
12:05	SL 2.5.	Multiparametric analysis: an useful insight into tumour properties? *J.W. Casselman, Bruges/BE*	
12:20		Discussion	

11:00–12:30	**SS 11**	**Salivary glands** *T. Beale, London/UK; B. Bobek-Billewicz, Gliwice/PL*	**Room 2**
11:00	SS 11.1.	Diagnostic approach of large salivary gland nodules *C. Czerny, Vienna/AT*	
11:30	SL 11.2.	Ultrasound of the face and neck *S. Robinson, Vienna/AT*	
12:00	SL 11.3.	Small and accessory salivary glands pathologies *A. Borges, Lisbon/PT*	

12:30	**Closing ceremony**	**Room 1**

ORAL PRESENTATION ABSTRACTS

Thursday, September 24, 2015

SS 1.1.
CT

A. Trojanowska; Lublin/PL

Short Summary: CT imaging plays a crucial role in defining the extension of cancer and in therapy planning.

Chemotherapy and radiotherapy are now considered as the standard of treatment in majority of cases. Also, criteria of inoperability have changed, consequently at present more extented resections and reconstructions are performed. Changes in treatment strategy of head and neck cancer, necessitate more accurate radiological evaluation, knowledge of tumour characteristics, behaviour and prognostic factors.

Take Home Points:
- Contemporary CT imaging of the head and neck provides information about tumour behaviour. It helps to understand tumor biology, like microvasculature, neo-angiogenesis and tissue oxygenation
- This information is crucial in contemporary approach to head and neck cancer, enables better treatment planning and follow-up both in surgically and non-surgically treated patients.
- True power of contemporary imaging studies lies in its ability to almost-immediate evaluation of the results of chemo- and radiotherapy.

Keywords: Functional imaging, Head and neck cancer, CT, Perfusion

SS 1.3.
PET-CT and PET-MRI

M. Becker; Geneva/CH

Short Summary: PET/CT is a robust, rapid and reliable technique in head and neck oncology mainly used to stage nodal disease, to detect distant metastases and synchronous tumours or unknown primary cancers. It also plays a major role for planning of radiotherapy and for the assessment of treatment response. Recently introduced hybrid PET/MRI systems allow acquisition of multiparametric information (morphologic, functional and molecular data) in a single examination with the potential to outperform PET/CT.
This lecture focuses on clinical applications of PET/CT and PET/MRI in head and neck oncology with special emphasis on squamous cell carcinoma. First, evidence about the combined use of PET/CT and MRI is discussed. Then, recent data on PET/MRI regarding clinical feasibility, PET quantification using MRI based attenuation maps, optimized protocols in clinical settings and current evidence for diagnostic performance in the head and neck are discussed. The appearance of primary squamous cell cancers, lymph node metastases and distant metastases on PET/MRI, as well as the added value of multiparametric imaging are

reviewed. Challenges in multiparametric image interpretation are discussed. The value of PET/MRI in the irradiated neck is equally illustrated, in particular for the differentiation of radiation-induced changes and complications from tumor recurrence.

Take Home Points:

- PET CT is a well established technique which is complementary to MRI in head and neck oncology patients.
- Although PET MR is still a research tool, it holds promise as it allows the acquisition of anatomic, functional and metabolic imaging in a single examination
- PET MR increases the diagnostic certainty in patients with previous radiation therapy

Keywords: PET CT, PET MR, Head and neck, Squamous cell carcinoma, PET CT, PET MR, Radiation therapy, Staging primary tumors

SS 2.1.
Conductive hearing loss in patients with intact tympanic membrane

E. Loney; Bradford/UK

Short Summary: Conductive hearing loss is the result of faulty sound transmission from the external environment to the inner ear apparatus. In this presentation we will be looking at causes 'beyond' the tympanic membrane i.e affecting the middle ear cavity, ossicular chain and round/ oval windows.

In order to make the differential memorable the middle ear will be compared to a 'washing machine' and pathology analogous to washing of different colours within it! The tympanic membrane is the door of the washing machine and we will look through it, comparing the view to that seen on otoscopy. In this way we will break down causes into easily memorable segments.

We will cover processes both benign and malignant, congenital and acquired, looking at why they cause hearing loss and using the clinical history to narrow our differential. The majority of the presentation will utilise high resolution CT images, touching on other modalities as appropriate.

Hopefully this logical approach with a sprinkling of humour will combine to produce an informative, yet easily understandable method for reporting imaging examinations.

Take Home Points:

Conductive hearing loss beyond the tympanic membrane can be due to:

- Material in the middle ear cavity, restricting movement of the ossicles
- A problem with the ossicles themselves such as absence, dysmorphia, ankylosis and discontinuity
- Abnormalities affecting sound transmission at the level of the round/ oval windows

When assessing potential causes take into account:
- the clinical history
- otoscopic findings
- appearances on imaging

Use a logical, methodical and repeatable approach to reporting such examinations to arrive at a sensible differential diagnosis.

Keywords: Middle ear pathology, Ossicular chain, Conductive hearing loss

SS 2.2.
7 Tesla imaging of the inner ear

B. Verbist, W. Brink, A.M. van der Jagt, J.H. Frijns, A. Webb; Leiden/NL

Short Summary: Since the FDA declared MRI-scanners up to 8 Tesla non significant risk devices in 2003 ultrahighfield (UHF) MRI became available for human imaging with promising advantages in image quality due to increased signal-to-noise ratio, better contrast and higher spatial resolution. Gradually its application in clinical research is expanding and in selected cases it is being used for patient care. Exploiting the benefits of UHF scanning, however, requires optimization of hardware and software and development of dedicated scanprotocols to overcome the technical challenges associated with imaging at higher magnetic field strengths.

The inner ear poses specific challenges when exposed to UHF:

1. due to its location within the temporal bone and the presence of air-bone-fluid interfaces it is extremely vulnerable to image degradation by inhomogeneous RF and magnetic field. High dielectric permittivity bags and image based shimming have been shown to be a good approach to deal with this [1-3] (Fig 1) and results in more detailed visualization of intralabyrinthine structures (Fig 2).
2. vestibular activation by the high static magnetic field may lead to vertigo and dizziness as transient side-effects.

This lecture will provide an overview on the challenges and solutions for inner ear imaging at 7T.

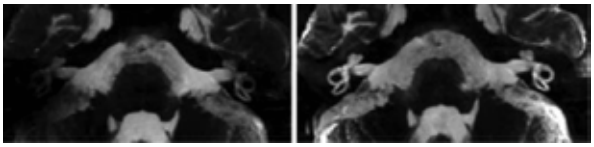

Figure 1: 3DMIP-reconstruction of the inner ear at 7T: artifacts inherent to high magnetic field hamper inner ear imaging (a). They are clearly reduced with the use of high dielectric permittivity bags (b)

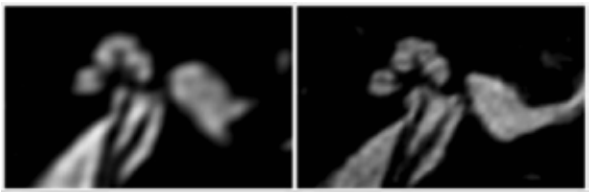

Figure 2: Cross-section through the labyrinth at 3T (0.6 mm isotropic voxel) (a) and 7T (0.3 mm isotropic voxel) (b) demonstrates improved visualization of fine anatomic structures at UHF.

References:
- Teeuwisse WM et al.Simulations of high permittivity materials for 7T-neuroimaging and evaluation of a new barium-titanate-based dielectric. Magn Reson Med 2012;67:912–918
- Brink WM et al. High permittivity dielectric pads improve high spatial resolution magnetic resonance imaging of the inner ear at 7 T. Invest Radiol. 2014 May;49(5):271-7.
- van der Jagt MA et al. Visualization of human inner ear anatomy with high-resolution MR imaging at 7T: initial clinical assessment. AJNR Am J Neuroradiol. 2015 Feb;36(2):378-83.

Take Home Points:
- 7T-imaging is technically challenging
- Inner ear imaging at 7T is feasible and provides detailed anatomical information

Keywords: Ultra high field MRI, 7T, Dielectric pads, Inner ear

SS 2.3.
How to evaluate a cholesteatoma?

B. de Foer[1], A. Bernaerts[1], J.-P. Vercruysse[1], J. Van Dinther[1], E. Offeciers[1], J.W. Casselman[2]; [1]Antwerp/BE, [2]Bruges/BE

Short Summary: While imaging of cholesteatoma relied in the past mainly on CT scan, MRI has gained growing importance during the past decade in the pre-operative and post-operative evaluation of the cholesteatoma patient. In this lecture, congenital as well as acquired cholesteatoma will be discussed. Imaging features of cholesteatoma on CT as well as on MRI will be illustrated and different types of surgery will be discussed. The evaluation of the post-operative cholesteatoma patient using MRI will be extensively illustrated as well as the imaging features of cholesteatoma on non-echo planar diffusion-weighted MRI. The imaging features of the main differential diagnostic entities will be highlighted, as well as tips and trics to avoid false positive and false negative examinations. MR imaging protocols will be discussed.

Take Home Points:
- MRI has become an indispensable tool in the evaluation of cholesteatoma patients.
- Post-operative evaluation of the cholesteatoma patients is done using MRI with non echo planar diffusion-weighted MR sequences. CT is no longer used as the primary imaging tool in the evaluation of the post-operative patient.
- Gadolinium administration is no longer required except in case of suspected complications.

Keywords: Cholesteatoma, MRI, Non-echo planar diffusion-weighted sequences

SS 3.1.
HPV connection

L. Ginsberg; Houston/US

Short Summary: In recent years, coincident to the decline in smoking-related head and neck malignancies, HPV-associated oropharyngeal cancer has emerged as a distinc clinico-pathologic entity. This presentation will focus on the epidemiologic background, behavioral associations, imaging findings, and other unique features of this evolving epidemic.

Take Home Points:

- HPV-associated oropharyngeal cancer is increasing in incidence, and there are unique imaging features and also certain challenges facing the radiologist.
- Spread of HPV is associated with well-known behavioral factors, and the resulting oropharyngeal malignancy is seen in certain characteristic demographic groups.

Keywords: Human Papilloma Virus, Oropharyngeal cancer, Imaging of oropharyngeal cancer

SS 3.2.
Current trends for non-surgical treatment

K. Skladowski; Gliwice/PL

Short Summary: Head and neck cancers (HNC) comprise a heterogeneous group of tumors which have an uncertain and unsatisfactory prognosis of cure despite intensive local treatment which produces quite high rate of temporary and permanent injuries. Therefore multimodal treatment approach is to improve locoregional control and improve survival as well as to achieve preservation of the organ, i.e. radiation and systemic therapy in appropriate combination. Neoadjuvant treatment strategies for tumor bulk reduction before radiation-based treatment have yet to gain acceptance in locoregionally advanced HNC in aspect of lower risk of distant metastases and tumor mass shrinkage. Concomitant chemoradiotherapy has been shown to improve survival and is considered a standard treatment for locally advanced HNC. Despite the improvement of therapeutic management, mortality rates of these patients remain high. Thus, molecular targeted therapies focused on epidermal growth factor receptor (EGFR) have been developed to help increase specificity and reduce toxicity. But the benefit of EGFR antibodies is still small and other EGFR inhibitors and novel biologicals pathways of HNC are currently being evaluated.

On the other hand the need of discovery and selection of a new prognostic and predictive biomarkers is evident. In this field numerous new molecular biomarkers, like tumor suppressor p53, growth factors, cytokines, DNA methylation or matrix metalloproteinases are investigated in translational and clinical sudies.

With the recent technological advantages in radiation oncology (IMRT, SBRT, IGRT), factors of maintaining the quality of live, improved imaging capabilities detailed knowledge of fundamental oncological pronciples along with thorough patient evaluation is mandatory.

Take Home Points:

- Current trends in non-surgical treatment of HNC patients concerns optimal combination of radiation, radiosensitization and systemic treatment in order to obtain high rate of locoregional control, survival, organ preservation and QoL.
- In these aims conformal dose delivery techniques like Intensity Modulated Radiation Therapy (IMRT), Stereotactic Body Radiation Therapy (SBRT) both supported by Image Guided (IG) tools are involved in combination with induction/concomitant Platinum-based chemotherapy and molecular targeted therapy.

Keywords: Induction chemotherapy, Molecular-targeted therapy, Prognostic and predictive biomarkers, Radiation therapy, Concurrent radio-chemotherapy

SS 4.1.

Congenital anomalies of the temporal bone

B. Ozgen Mocan, G. Atay; Ankara/TR

Short Summary: This presentation will review the important aspects of imaging in the evaluation of the patients with congenital anomalies of the temporal bone with an emphasis on the imaging before cochlear or brain stem implantation.

The characteristic imaging findings of different types of congenital ear malformations will be summarized and standard surgical implantation techniques will also be briefly described to familiarize the audience with these anomalies and treatment methods.

CT and MR imaging of the temporal bones before cochlear and brain stem implantation will be reviewed with an interactive discussion between radiologist and surgeon, followed by real time movies during implant surgery. Contraindications for the cochlear implantation including cochlear nerve aplasia and absence of the cochlea will be highlighted. Additionally potential sites of surgical complication such as aberrant facial nerve, cases with increased CSF gusher risk will be pointed out.

For the assessment of congenital anomalies of the temporal bone, the radiologists should be familiar with the surgical techniques and be able to identify clinically and surgically relevant findings that may contraindicate the cochlear implantation or alter the surgical methods.

Take Home Points:

- Classification of inner ear malformations
- Imaging evaluation before implantation

Keywords: Temporal bone, Congenital anomalies, Computed tomography

SS 4.2.

Skull base and brain lesions affecting temporal bone

J.W. Casselman[1], B. de Foer[2]; [1]Bruges/BE, [2]Antwerp/BE

Short Summary: The most frequent lesions that affect the cerebellopontine angle (CPA) and internal auditory canal (IAC) are VIIIth nerve schwannomas (60%), meningiomas (10%) and epidermoid tumors (5%). In this presentation the less frequent brain and skull base lesions that affect the CPA, IAC and temporal bone (TB) will be discussed. However, even the above mentioned frequent and normally easy to recognize lesions can have an atypical presentation and are sometimes more difficult to recognize. MR is the method of choice to characterize these lesions and to visualize their exact extension. Less frequent lesions originating in the brain are ependymomas, choroid plexus papillomas, brain stem astrocytomas or glioblastoma multiforme, PNET, metastases, lymphoma, craniopharyngeoma, MS etc. Less frequent occuring Vth & VIIth nerve schwannomas and ELST's can also affect the TB. Arteriovenous malformations, giant aneurysms, hemangiomas, dural fistulas can also be found in the CPA and IAC and can cause hearing/vestibular problems. An even higher number of rare skull base lesions can affect the temporal bone. Two of the most frequent lesions occuring in the jugular foramen region are paragangliomas and lower cranial nerve schannomas. However, squamous cell carcinomas originating in the nasopharynx or external ear, parotid gland tumours (benign and malignant), adenoid cystic carcinoma of the EAC or middle ear and various metastases can also invade the TB. Large chordomas and chondrosarcomas can also involve the CPA or TB as well as very rare tumors like osteosarcomas, eosinophilic granuloma, Ewing sarcomas, plasmocytoma and rhabdomyosarcomas. Finally infectious and inflammatory lesions like malignant otitis media, Wegener's granulomatosis and tuberculosis can also involve the CPA-IAC-TB. Many of the above mentioned lesions will be illustrated and their imaging characteristics will be discussed.

Take Home Points:

- Be aware that many lesions originating in the brain and skull base can affect the IAC, CPA and TB and that they are best depicted and characterized using MR.
- Know the most frequent brain lesions that affect the temporal bone
- Know the most frequent skull base tumors (with exclusion of VIIIth nerve schwannoms, meningiomas & epidermoid tumors) that affect the temporal bone
- Know the vascular and inflammatory/infectious lesions that can affect the temporal bone

Keywords: Temporal bone tumors, Temporal bone, Cerebellopontine angle, Skull base, Internal auditory canal

SS 4.3.
Petrous apex lesions: Diagnostic approach

D. Farina; Brescia/IT

Short Summary: The petrous apex (PA) is a bone structure centrally located in the skull base, which anatomical complexity is mainly related to the close relationships with cranial nerves (mainly V to VIII) and vascular structures (ICA, essentially). Such relationships account for signs and symptoms that may herald PA lesions (diplopia, facial weakness or pain, sensorineural hearing loss, tinnitus, vertigo), although not infrequently lesions are incidentally found on scans performed for different clinical reasons. As a general rule, the combination of high contrast resolution and high spatial resolution (achieved by 3d T2 or T1 sequences) makes MRI the technique of choice for the evaluation of this area. However, CT may be used as a problem solver whenever the diagnosis requires the assessment of subtle bone changes, either in the medial spongiotic portion (often pneumatized) or in the dense lateral portion, derived from the otic capsule.

The list of differential diagnoses for PA lesions is extremely varied, including developmental and inflammatory lesions, bone and vascular lesions, benign and malignant tumors. Such a taxonomic approach may be more helpful when a MRI scan is performed as a first imaging study in the strong clinical suspect of a PA lesion. However, for all PA lesions incidentally found on CT or MRI scan, an approach focused on bone changes produced by the lesion may prove to be more effective. The classification based on absence of changes, bone remodeling or bone destruction may help to identify lesions for which no further action is needed as well as provide information useful for characterization. Bone expansion (frequently poliostotic) may indicate fibrous dysplasia of Paget disease, although the heterogenous CT and MRI pattern (reflecting different stages of the disease) may raise concern in unexperienced readers. On the other hand the clinical history (even more than imaging findings) is essential in the diagnosis of inflammatory conditions, which manifest with fever (possibly combined with some of the abovementioned neurologic signs), often ensue as a complication of acute otitis media and may be favoured by diabetes.

Take Home Points:
- To understand about the anatomy.
- To provide practical clues for image interpretation.

Keywords: Petrous apex, CT, MRI

SS 4.4.

Menière and endolymphatic hydrops

F. Veillon, M. Eliezer, M. Abu Eid, A. Venkatasamy, D. Rohmer, A. Charpiot; Strasbourg/FR

Short Summary: To precise the size and shape of the saccule with 3T MRI (GEHDX3T) 2 populations: 62 patients with Meniere's disease and 64 healthy volunteers.

Take Home Points:

- A series of 64 healthy volunteers integrated in a research program approved by the ethic committee of our institution was studied with a 3 Tesla MRI (GE HDX 3T: 3D Fiesta high resolution T2 FOV 22 cm, thickness 0.3 mm, 78 sections, 1 excitation, Matrix 484, flip angle GE 60°, TR 6.7 TE 2.8, acquisition time 7.36 minutes) compared with another group of 62 patients presenting Meniere's disease according to the AAO HNS classification in the same conditions (same machine same sequence). The size of the saccule (height and width) was measured by 2 observers in the coronal plane (section through the ampullas of the lateral and anterior semicircular canals).
- Averages and standard deviation were calculated. Measurements were considered normal if they were 2 SDS within the average. The average of the right and left heights of saccules in the normal group were respectively 1.42 and 1.44±0.125. The average of the width of the normal right and left saccules were 1.2.± 0.125 without any statistical difference between the 2 observers in both cases. Heights of 1.7 mm, a width of 1.5 mm were considered as pathological. In Meniere's disease it was possible to diagnose an enlarged saccule in 82% (n=51 out of 62) of the cases. The maximal height was 2.2 mm; the maximal width was 1.7 mm. The normal shape of saccule appeared as a rugby balloon. In Meniere's disease it was usually lengthened rarely round (n= 2, football balloon). In 4 cases the saccule was not visible (probably by rupture). In 18 cases the saccule was enlarged in both sides.
- It is possible to diagnose Meniere's disease with a 3T MRI in more than 80% of the cases (82%) in less than 8 minutes without any Iintravenous gadolinium injection. The injected method should be proposed in the remained 18 % of the patients.

Keywords: Temporal bone, Ear, Meniere, MRI, Membranous labyrinth

SOPS 1.1.
Interpreting non-echoplanar diffusion weighted images in post-operative cholesteatoma: Navigating past the pitfalls

R. Lingam, R. Nash, A. Singh; London/UK

Short Summary: Non-echoplanar diffusion weighted imaging (DWI) performs well in diagnosing post-operative cholesteatoma and currently is the modality of choice. However, it also comes with pitfalls which can be problematic for the unsuspecting radiologist. Though it has a high sensitivity and specificity (typically 80 -100%), false negative and false positive cases have been described.

We aim to illustrate with a case series the various pitfalls when interpreting DWI images for detecting post-operative cholesteatoma so as to arm the radiologist with approaches and strategies to navigate past them.

Purpose/Objectives: To illustrate, through a case series, our institutional experience of non-echoplanar diffusion weighted imaging (DWI) in the management of post-operative cholesteatoma, highlighting various pitfalls and strategies for image interpretation and management.

Methods and Materials: A series of cases has been selected to illustrate our experience in the use of non-echoplanar (HASTE) DWI in the management of cholesteatoma, with particular emphasis on various interpretation pitfalls encountered.In particular, various false postive and false negative cases for the disease are selected.

Results: Our case series highlight various interpretation pitfalls which can be managed by various approaches and strategies for a more accurate and safer evaluation.

Conclusion: Though non-echoplanar DWI is currently the modality of choice in detecting post-operative cholesteatoma, its use can be further enhanced by appreciating its pitfalls and adopting a safer approach to manage them.

Keywords: Non-echoplanar diffusion weighted MRI, Post-operative cholesteatoma, Pitfalls

SOPS 1.2.
Describing cochlear size and morphology using an automatic tracing method to determine cochlear walls and the course of the scala tympani.

A.M. van der Jagt, R.K. Kalkman, J.J. Briaire, J.H. Frijns, B. Verbist; Leiden/NL

Short Summary: Describing cochlear size and morphology using an automatic tracing method.

Purpose/Objectives: The human cochlea shows considerable variability in size and morphology. Likely, this variation may influence the final position of the electrode array after performing cochlear implant surgery and may also have implications for the development of cochlear implant electrode arrays, as preservation of residual hearing during insertion and optimal position of the electrode array should be applicable in all individual cochleas, to maximize speech recognition. The aim of this study was to determine the cochlear walls of

the first and second turn in CT images, using an automatic tracing method. This provides the unique opportunity to study cochlear morphology in vivo in a large population.

Methods and Materials: Preoperative CT-scans of patients, consecutively implanted at our institution between 2011 and 2014 were analysed. Patients with cochlear malformations, obliteration of the cochlear lumen and with scans of inferior quality were excluded. This left 479 inner ears of 242 patients for analysis. The cochlear walls were determined automatically by interpolating voxel intensities along radial lines in multiplanar reconstructions (MPRs); the walls were assumed to correspond to the intensity value halfway between minimum and maximum along the resulting curves.

Results: The outer and inner wall could be automatically determined up to 720 degrees from the center of the round window in all 479 outer and 192 inner walls respectively. In 287 cochleas the inner wall measurements were achieved to a lesser extent; on average up to 577 degrees (SD 161). The averaged radius of the outer wall from the center of the modiolus follows a logarithmic spiral up to 520 degrees with an R2 of 0.94. More apical, the inner and outer walls do not further approximate the modiolus and the cochlear lumen does not decrease. The trajectories of the scala tympani show a non-monotonous slope of the spiral path with specific locations at risk for insertion trauma.

Conclusion: This study presents an automatic tracing method to describe cochlear size and morphology that allows to evaluate patient-specific cochlear features, enables to correlate these findings to surgical outcome and supports to make accurate estimations on insertion trauma risk.

Keywords: Cochlear implantation, Cochlear morphology, Automatic tracing method

SOPS 1.3.
CT visualisation of the Eustachian Tube using focal contrast administration: a feasibility study.

B. Falkenberg-Jensen, J.T. Silvola, H. Laurvik, A. Lervik, J.F. Kristiansen, G.E. Jablonski, E. Hopp; Oslo/NO

Short Summary: Using focal contrast medium application to the middle ear, the Eustachian tube in rabbits was visualised with CT.

Purpose/Objectives: Balloon catheter dilation of the cartilaginous part of the Eustachian tube (ET) has a beneficial effect on ET dysfunction and its complications. We aim to develop a novel imaging technique for visualisation of the ET by applying contrast medium to the middle ear followed by CT imaging.

Methods and Materials: Applying iodixanol to the middle ear in two human temporal bone specimens followed by CT examinations, we optimised parameters regarding contrast dilution, CT algorithm and head positioning for visualisation of the contrast passage through the ET.

Aided by otomicroscopy, myringotomy was performed in eight general anesthetised rabbits. Based on the results of the cadaver study, a 20% iodixanol solution was applied to the middle ear and CT scans of the temporal bone were performed with three-minute intervals to observe contrast medium in the epipharynx. For some animals the procedure was repeated on the contralateral ear. The animals were observed for 1-2 weeks to detect signs of inflammation. The procedure was then repeated for most of the subjects. A total of 20 examinations were included.

Contrast medium appearance in the ET and the epipharyngeal orifice was assessed qualitatively on CT scans. The tympanic membrane was inspected clinically one and two weeks after the first examination, and histopathological examination of six contrast exposed temporal bones was performed.

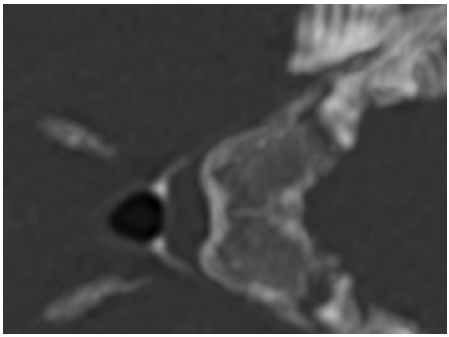

Results: The cadaver study gave valuable information on imaging technique and contrast dosage. In rabbits, the contrast medium passed through the ET in 19 of the 20 ears examined.

In most cases the contrast medium was visible in the epipharyngeal orifice after 3 or 6 minutes. Qualitatively, optimal visualisation was seen on the later series (9 and 12 minutes).

Clinical inspection one or two weeks after the first examination revealed normal middle ear status.

Gross histopathological samples showed no sign of inflammatory reaction in the tympanic membrane, middle ear or ET.

Conclusion: Contrast medium application to the middle ear is feasible, safe and demonstrates patency of the ET in rabbits.

Keywords: CT, Eustachian tube, Contrast medium

SOPS 1.4.
Fractures of the temporal bone : an easier way to read your CT

A. Venkatasamy[1], F. Veillon[1], S. Riehm[1], P. Meriot[2], P. Baur[1], A. Charpiot[1]; [1]Strasbourg/FR, [2]Brest/FR

Short Summary: A 712 patients study for an easy approach of temporal bone trauma. The best way to analyze temporal bone fractures is to consider separately the external, middle and inner ear.

Purpose/Objectives: Improve the way of reading temporal bone fractures on CT. Propose the simpliest classification ever presented.

Methods and Materials: We analyzed a series of 712 patients presenting fractures of the temporal bone. Clinical findings were otorrhagia, otorrhea, hearing loss, vertigo, tinnitus and peripheric facial nerve palsy. All patients underwent a non-contrast CT of the temporal bone (140kV, 300mAs). The study box was parallel to the orbital roof, with slice thickness from 0.3 to 0.5mm. The image reading was done by cavity: external (anterior, posterior and superior walls), middle (anterior, external and internal walls) and inner ear.

Results: 712 patients presented 774 fractures of the temporal bone. External ear fractures were found in 50% of the cases (n=320), mostly concerning the anterior wall (75%). 79% (n=611) fractures were middle ear fractures, 352 of which were reanalyzed and divided in 6 different types, based on the orientation of the fracture. 16% (n=56) were type A fractures, with an entry point anterior to the external auditory meatus (EAM). 27% (n=95) were type B fractures with an entry point through the roof of the EAM. Type C fractures were the most common (40%, n=143), with an entry point behind the EAM at the level of the lateral antrum wall. Type D fractures were less common (6%, n=20) with an entry point through the superior-posterior petrosquamous fissure. Type E fractures had an entry point at the posterior part of the temporal bone, close to the lateral sinus (6%, n=20). Type F fractures ran through the posterior-internal part of the temporal bone in 5% of the cases (n=18). Isolated inner ear fractures represented 8% (n=63) of all fractures. Combined inner and middle ear fractures represented 5% (n=39) of all fractures.

Conclusion: This new classification of temporal bone fractures, divided into external, middle and inner ear fractures makes the reading of posterior skull base trauma much easier.

Keywords: Classification, Ear, Fractures, Trauma, Temporal bone

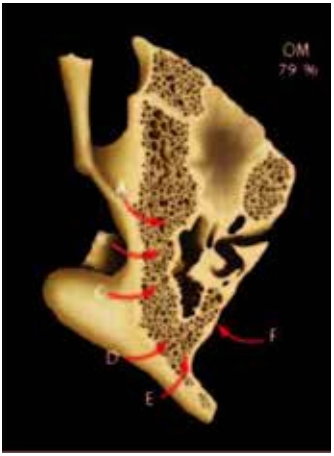

Figure 1: Middle ear fractures (A-F)

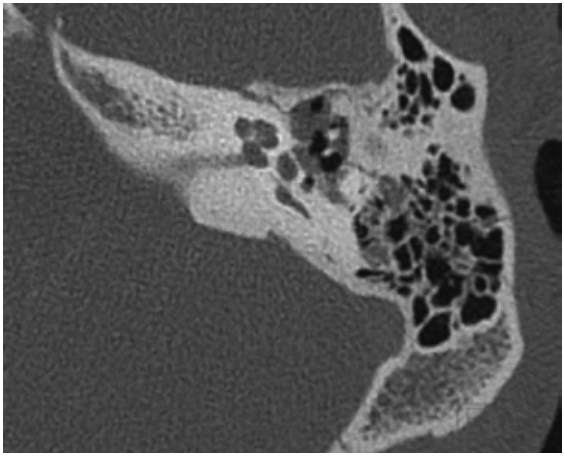

Figure 2: Type C fracture

SOPS 1.5.

Role of Mastoid Pneumatization in Temporal Bone Fractures: What really protect?

H.J. Kim, E.S. Kim, K. Lee; Anyang/KR

Short Summary: We investigated whether mastoid pneumatization reducing the incidence of fracture in trauma setting on daily practice. Mastoid pneumatization were classified into 5 types: Type I (hypo-pneumatization), type II (moderate), type III (good), IV (hyper-pneumatization), and V (sclerotic). We were analyzed whether there is a statistically difference for each type. Temporal bone fracture most frequently seen at type III, but there were no statistically significant differences. We did not find the evidence with a statistical significance that the role of the mastoid pneumatization protection of the inner ear and reducing the incidence of fracture in trauma cases on daily practice.

Purpose/Objectives: Previous cadaver study reported that mastoid pneumatization of temporal bone play a role in the protection of the temporal bone structures during trauma. We investigated whether mastoid pneumatization reducing the incidence of fracture in trauma setting on daily practice, too.

Methods and Materials: A retrospective review of all patients with a temporal bone computed tomography (CT) scan in the emergency department, between January 1, 2014, and December 31, 2014. Two radiologists visually evaluated the images for the presence of temporal bone fracture, ossicle and inner ear injury. Pneumatization of temporal bone were classified into 5 types: Type I (hypo-pneumatization), type II (moderate), type III (good), IV (hyper-pneumatization), and V (sclerotic). We were analyzed whether there is a statistically difference for each type.

Results: A total of 109 patients, fracture patient were 41 people (37.6%), ossicle or inner ear injury were 11 people (10.1%). Facial bone fracture, skull bone fracture, & intracranial hemorrhage were 28 patients (2.57%), 35 patients (32.1%), & 46 patients (42.2%), respectively. Mastoid pneumatization showed type I in 3 (2.8%), type II in 22 (20.2%), type III in 29(26.2%), type IV 37 (33.9%), sclerotic type 28 (16.5%). Temporal bone fracture most frequently seen at type III, but there were no statistically significant differences. There were no statistically significant differences between each type about inner ear, facial and intracranial injury.

Conclusion: We did not find the evidence with a statistical significance that the role of the mastoid pneumatization protection of the inner ear and reducing the incidence of fracture in trauma cases on daily practice.

Keywords: Temporal bone fracture, Mastoid pneumatisation, Temporal bone computed tomography(TBCT)

SOPS 1.6.
Does non-echo planar Diffusion Weighted MRI perform better in adults than in children in detecting post-operative cholesteatoma?

R. Lingam, R. Nash, A. Singh; London/UK

Short Summary: Middle ear cholesteatoma is well recognised inflammatory process in both adults and children and requires surgical treatment. Non-echoplanar diffusion weighted MRI (DWMRI) is currently the modality of choice in detecting post-operative cholesteatoma as established by many studies to date. Its performance has been assessed mainly in adults, with a few sole paediatric studies in the literature.

To our knowledge, the performance of DWMRI in detecting post-operative cholesteatoma however has not yet been directly compared in a study between paediatric and adult patients.

Purpose/Objectives: The aim of this study is to compare the diagnostic performance of non - echoplanar diffusion weighted imaging in detecting post-operative cholesteatoma in children and adults.

Methods and Materials: A prospectively collected database of cases who had non-echoplanar (HASTE) DWMRI for post-operative cholesteatoma and subsequently underwent re-look surgery was searched. Revision surgery was performed in 148 ears, of which 54 were paediatric cases. Surgery was considered the gold standard test for determining the presence or absence of cholesteatoma.

Retrospective analysis to include performance statistics was performed. Comparison of the performance of DWMRI between paediatric cases and adult cases was done using the Fisher's exact test.

Results: The overall accuracy of DWMRI in detecting post-operative cholesteatoma is 90.5%: The accuracy in paediatric cases is 96% and in adults 88% but the difference is not statistically significant (p=0.14).There is also no statistically significant difference between the two groups for sensitivity, specificity, positive predictive value or negative predictive value.

Conclusion: Non-echoplanar DWMRI performs equally well in detecting post-operative cholesteatoma in the paediatric and adult groups.

Keywords: Post-operative cholesteatoma, Non -echoplanar HASTE diffusion weighted MRI, Paediatrics

SOPS 2.1.

Diagnostic accuracy of non-contrast and contrast-enhanced MRI in assessing cartilaginous infiltration by laryngeal tumors

L. Preda, L. Bonello, G. Conte, F. Ruju, M. Ansarin, L. De Benedetto, F. Maffini, E. Tagliabue, M. Bellomi; Milan/IT

Short Summary: We observed a good diagnostic accuracy for both non contrast and contrast enhanced MRI in the assessment of cartilaginous infiltration in pre-operative staging of laryngeal squamous cell carcinomas, with values of 88% and 86% respectively.

Purpose/Objectives: To assess the diagnostic accuracy (DA) of MRI using dedicated surface coils in predicting invasion of the thyroid and cricoid cartilage in laryngeal tumors. In so doing we assessed if there is any difference in the DA of MRI performed with and without contrast.

Methods and Materials: Between June 2011-February 2015 we prospectively enrolled 101 patients with a histological bioptic confirmation of laryngeal cancer who performed staging MRI of the larynx. All exams were performed using a 1.5T machine using a dedicated surface coil and a standard neck coil. For image analysis we only considered patients who performed open surgery at our Institute in order to compare all MRI results with surgical histology. A radiologist with 20 years experience evaluated for cartilaginous infiltration (thyroid, cricoid cartilage) on two separate readings: R1, using pre-contrast T1 sequences, T2 weighted sequences and diffusion-weighted imaging (DWI), followed 1 month later by R2, using T1 pre and post contrast sequences, T2 weighted sequences and DWI. We evaluated MRI DA by comparing results of R1 and R2 with surgical histology.

Results: For image analysis we considered 37 patients with squamous cell carcinoma of the larynx who performed staging MRI as well as open surgery at our Institute. For R1 we observed a DA of 88% (sensitivity 81%, specificity 92%, PPV 84%, NPV 90%). With regards to R2, we observed a DA of 86% (sensitivity 88%, specificity 85%, PPV 77%, NPV 93%). We did not observe any significant difference in DA for R1 and R2 ($p = 0.8$).

Conclusion: MRI using dedicated surface coils has shown good DA in the assessment of neoplastic infiltration of the thyroid and cricoid cartilage. MRI performed without contrast agent showed a similar DA compared to MRI with contrast.

Keywords: MRI, Laryngeal cancer, Diagnostic accuracy, Thyroid cartilage, Cricoid cartilage, Cartilaginous infiltration

SOPS 2.2.
SPECT scanning and parathyroid surgery in the Southern Trust, Northern Ireland

D. Neeson[1], G. Gray[2], C. Leonard[2], M. Korda[2], M. Fawzy[2]; [1]Belfast/UK, [2]Craigavon/UK

Short Summary: A regional reivew of the accuracy of SPECT/CT in patients with primary hyperparathyroidism was carried out. Findings during surgical intervention were correlated with the diagnostic findings and compared. Anatomical accuracy was 94% which is greater than those in publications elsewhere.

Purpose/Objectives: Primary hyperparathyroidism is caused by a single parathyroid adenoma in up to 90% of clinical cases. Selective surgical excision of the hyperfunctioning parathyroid gland is the treatment of choice for this condition, and parathyroid scintigraphy is one of the primary and standard methods used for preoperative localisation. SPECT/CT is advantageous over planar imaging because SPECT/CT provides useful anatomic information, improving overall diagnostic confidence. This study aims to review our practice and ensure that these new tools are improving patient outcomes.

Methods and Materials: We reviewed every patient who had SPECT/CT for primary hyperparathyroidism over a 3 year period. We reviewed the examination findings and compared this to the pathological findings of those who required surgical intervention. We also reviewed parathormone and calcium levels.

Results: 64 patients were scanned with SPECT in the Southern Trust over past 3 years. Mean Age of these patients was 64.62 with range of 28-86. 59% (38/64) had positive findings on SPECT/CT. 40 patients underwent surgical intervention, 31 had positive findings on SPECT/CT. 29 of these patients had positive scan in correlation with surgical site giving an accuracy of 94%. These findings were consistent with the biochemical improvement in these patients with the mean pre-operative parathormone level 288 reducing to 55 post-operatively.

Conclusion: Unfortunately it would be too difficult to ascertain sensitivity & specificity in this study group due to inability to gather a value on false negatives, however, we can be confident with the accuracy of SPECT/CT in localization of parathyroid disease in the Southern Trust.

Keywords: SPECT, Parathyroid, Adenoma

SOPS 2.3.
HIV- associated facial lipoatrophy: evaluation of tissue morphology before and after injection of hyaluronic acid filler with MRI

A. Ailianou, L. Toutous-Trellu, N. Balagué, X. Montet, A. Calmy, D. Salomon, M. Becker; Geneva/CH

Short Summary: HIV-associated facial lipoatrophy (HIV-FA) is a cosmetically disfiguring and stigmatizing condition seen in HIV patients treated with antiretroviral drugs. This prospective observational study evaluated magnetic resonance imaging (MRI) findings of subdermal hyaluronic acid (HA) injections in the face of these patiets and revealed that product deposition and related water trapping were seen much deeper than initially assumed.

Purpose/Objectives: This prospective study aimed to evaluate the MRI aspect of the face before and after injection of HA used for cosmetic purposes.

Methods and Materials: After approval by the ethics committee, informed consent was obtained in 10 consecutive males (mean age=56±6 years) with HIV lipoatrophy. They underwent bilateral subdermal HA injection (mean=1.3± 0.6ml per injected side) and serial MRI examinations prior to, then at 1, 6 and 12 months after injection. Quantification of skin thickness, in vivo HA volume, tissue edema and vascularization was done by experienced radiologists blinded to clinical data. For comparison purposes, measurements of skin thickness and facial fat distribution were equally obtained in 10 matched subjects without HIV-FA.

Results: Skin thickness and fat quantity were significantly higher in controls than in HIV-FA patients ($p<0.05$). After HA administration, filler deposition, related edema and increased vascularization were seen in the deep facial compartments mainly in Bichat's fat and along the facial vessels. MRI revealed significant HA volume increase one month after injection (mean increase=331%, $p<0.0001$), as compared to the injected amount and no significant volume reduction at 6 - 12 months ($p=0.9961$). There were no significant changes in skin thickness and edema over time ($p>0.9991$), whereas tissue hypervascularization decreased ($p=0.01$).

Conclusion: Our data show that the cosmetic results of facial HA injections in HIV-FA are caused by HA waterbinding and transient increased vascularization in the deep facial compartments.

Keywords: HIV, Facial lipoatrophy, Hyaluronic acid injection

SOPS 2.4.
Impact of combined FDG-PET/CT and MRI on detection of recurrent thyroid cancer and nodal metastases.

J.-M. Hempel[1], R. Kloeckner[2], S. Scheunemann[2], S. Schadmand-Fischer[2], M. Schreckenberger[2], M. Miederer[2]; [1]Tübingen/DE, [2]Mainz/DE

Short Summary: Early diagnosis of recurrent thyroid cancer after thyroidectomy and curative radio iodine therapy poses a diagnostic challenge for both the radiologist and the nuclear medicine physician. Often, there are only unspecific findings in one of each examination. FDG-PET/CT and MRI are commonly applied imaging modalities in patients with rising thyroglobulin levels and normal radio iodine scan to detect recurrent thyroid cancer and nodal metastases. The purpose of our study was to investigate the impact of combined FDG-PET/CT and MRI on detection of local recurrent thyroid cancer and nodal metastases. Special focus was set to quantify the value of the multidisciplinary consensus reading.

Purpose/Objectives: To investigate the impact of combined FDG-PET/CT and MRI on detection of recurrent thyroid cancer and nodal metastases.

Methods and Materials: 46 consecutive patients with suspected recurrent thyroid cancer or nodal metastases after thyroidectomy and curative radio-iodine therapy were retrospectively

selected for analysis. Inclusion criteria comprised rising thyroglobulin blood levels, a negative iodine whole body scan, and combined FDG-PET/CT and MRI examinations.

FDG-PET/CT and MRI examinations were independently analyzed by 2 blinded observers for local recurrent thyroid cancer and nodal metastases. Consecutively, the scans were read in consensus. To explore a possible synergistic effect FDG-PET/CT and MRI results were combined. Histopathology or long-term follow-up served as gold-standard.

For method comparison, sensitivity, specificity, positive and negative predictive values, and diagnostic accuracy were calculated.

Results: FDG-PET/CT was substantially more sensitive and slightly more specific than MRI in detection of both local recurrence and nodal metastases. Inter-observer agreement was substantial both for local recurrence (κ=0.71) and lymph node metastasis (κ=0.63) detection in FDG-PET/CT, and substantial for local recurrence (κ=0.69) and moderate for lymph node metastasis (κ=0.55) detection in MRI. In contrast, FDG-PET/CT and MRI showed only slight agreement (κ=0.21). However, its combined use created a synergistic effect. The multidisciplinary consensus reading further increased sensitivity, specificity, positive and negative predictive values, and diagnostic accuracy.

Conclusion: FDG-PET/CT and MRI should be combined to improve detection of local recurrent thyroid cancer and nodal metastases. Therefore, FDG-PET/MRI hybrid imaging will be a promising method, since the multidisciplinary consensus reading is the key element in diagnostic approach.

Keywords: Recurrent thyroid cancer, Thyroid cancer, Lymph node metastases, PET/CT, MRI, PET/MRI

SOPS 2.5.
US Diagnosis of micro medullary thyroid carcinoma mMTC

P.Y. Marcy[1], A. Lacout[2], E. Ghanassia[3], C. Chevenet[2], J.L. Sadoul[4]; [1]Ollioules/FR, [2]Aurillac/FR, [3]Sete/FR, [4]Nice/FR

Short Summary: Retrospective study assessing US features of 25 medullary thyroid carcinomas (MTC), mostly pT1N0M0, serum calcitonin level, FNAC and wash out.

Among them, ten microMTC (< 10mm) (mMTC) US features were studied.

US features that were never encountered in solitary mMTC included cystic or partially cystic micronodules, and isthmic / lower third lobe location.

Typical features include TIRADS 4a/b solid micronodules containing bright echogenic foci, seldom with central vasculature, at the upper central thyroid lobe.

Multifocality and isthmus location were only found in patients presenting with RET mutation and /or familial disease.

Serum calcitonin mean level of patients with mMTC was 33.3pg/ml. Calcitonin FNAC Wash out sensitivity was 100%.

US allows early detection of MTC. FNAC and FNWash out are mandatory.

Purpose/Objectives:
- To show the US features of micromedullary thyroid carcinomas (mMTC).
- To report the sensitivity of bright echogenic foci in mMTC.
- To report the sensitivity of FNAC and FNWash out.

Methods and Materials: Among 25 histologically proven - MTC classified T<T4, M0, we retrospectively reviewed the Doppler US features, serum calcitonin (CT) level, sensitivity of real time US guided - FNAC / FN Wash out of the mMTC.

Results: Ten patients (2M/8F, mean age 52,4y) displayed mMTC (<10mm) that were always located into the central parenchyma of the upper two thirds of thyroid lobe.

Solitary micronodules were scored TIRADS 4a / 4b, N0, M0;

Their mean size was 7.5mm (range; 4- 10mm), Mean serum calcitonin level was 33.3pg/ml. Echostructure was never partially or totally cystic. mMTC US diagnosis sensitivity was 36% when taking into account the “bright echogenic foci” into the micronodule, 10% when central vasculature was detected.

mMTC diagnosis sensitivity was 77.7% for fine needle aspiration cytology FNAC, and 100% for fine needle FNWash out (in situ- calcitonin level).

Only 10% of mMTC had serum calcitonin level >50pg/ml.

Multifocal mMTC were reported only in familial / RET mutation cases.

Conclusion: mMTC typical location is at the upper two thirds of central parenchyma of thyroid gland, when solitary.

Typical feature includes a hypoechoic micronodule with bright echogenic foci.

FNWash out sensitiviity is 100% for diagnosis even in the serum calcitonin “grey zone (10-50pg/ml) level”.

Keywords: Medullary thyroid carcinoma, Thyroid microcarcinoma, Calcitonin, FNAC, Ultrasound diagnosis, Wash out

SOPS 2.6.
Perineural spread of head and neck tumors detected by MDCT and MRI

S. Petrovic; Nis/RS

Short Summary: MRI is the method of choice for diagnostics of perineural tumor spread and it can determine the widening of neural foramen, voluminosity of affected nerve, postcontrast increase of nerve signals and obliteration of surrounding fat. MSCT can also provide useful information about perineural spread. Recognition of radiological signs of perineural spread is necessary in order to establish the right diagnosis and determine adequate oncological treatment.

Purpose/Objectives: The purpose of this study is to review the imaging characteristics of perineural tumoral spread in patients with head and neck tumors.

Methods and Materials: In this retrospective study, the patient population was composed of 45 male and 28 female patients (mean age 46 years) with head and neck tumors. Nine patients had clinical symptoms such as pain and parasthesia, paresis and muscle paralysis, or denervation muscle atrophy. Patients were examined by MDCT and MRI.

Results: Imaging studies depicted the location and extent of tumor involvement, helped determination of the type of head and neck tumor and their staging. Fifteen patients had the signs of perineural tumor spread on MR or MDCT imaging. MRI is the method of choice for diagnostics of perineural spread and it can determine the widening of neural foramen, voluminosity of affected nerve, postcontrast increase of nerve signals, obliteration of surrounding fat and muscle denervation atrophy. MSCT can also provide useful information about perineural spread relating to widening of neural foramen on skull base and obliteration of fat spaces. Muscle denervation atrophy may also be the consequence of perineural tumor spread. Chronic changes may be detected both on CT and MRI as the replacement of muscle tissue by fat one, loss of muscle volume and atrophy of muscles with common inervation.

Multifocal mMTC were reported only in familial / RET mutation cases.

Conclusion: Signs of perineural spread deteriorate the prognosis and require aggressive oncological treatment. Since patients could be asymptomatic, imaging plays an important role in detection of perineural tumor spread and good understanding of anatomy of cranial nerves is required. Recognition of radiological signs of perineural spread of head and neck tumor, as well as muscle denervation changes is necessary in order to establish the right diagnosis and determine adequate oncological treatment.

Keywords: Perineural spread, Tumor, Neck, Head

SS 5.1.
Follow-up for surgically treated patients

R. Lingam; London/UK

Short Summary: The aim of surgery is to achieve cure by complete excision of cancer with appropriate safe excision margins.

Over half of all patients who die from head and neck cancer have active locoregional recurrent disease. Most head and neck recurrences occur within 2 years following treatment. Recurrence rates following surgery vary and depend on several factors including accurate diagnosis and staging. Risk stratification is therefore an essential element in the management of post-operative patients and surveillance for recurrent disease.

The aim of surveillance following surgery is to detect recurrence early. Surveillance is usually by clinical examination, supported by imaging studies. Imaging requires a multidisciplinary approach. Imaging modalities commonly used to detect locoregional disease include MRI, CT,

ultrasound (with guided fine needle aspiration cytology) and functional imaging. The choice of imaging depends on local availability and expertise, and site of primary tumour.

This lecture aims to illustrate the application of imaging in the post surgical follow up of the various head and neck cancer sites that are treated primarily by surgery.

Take Home Points:

- There are many factors which influence risk of tumour recurrence following surgery
- Risk assessment and stratification is essential in the management and surveillance of the post-surgical patient.
- Imaging of tumour recurrence requires a multidisciplinary approach and the choice of imaging is influenced by tumour site and local expertise/availability.
- The principal imaging modallites that are used in the detection of post-surgical recurrence include MRI, CT, ultrasound and guided aspiration cytology and functional imaging.

Keywords: Recurrent cancer, Risk of recurrence, Post-surgical follow up

SS 5.2.
Follow-up after chemo-radiotherapy: The power of imaging studies

F. Pameijer; Utrecht/NL

Short Summary: Tissue changes in the treated neck by after (chemo)-radiotherapy (RT) make the detection of residual or recurrent tumor more difficult. Clinical evaluation of the neck is also hampered by these changes. RT-induced fibrosis makes palpation of the neck very difficult. Endoscopy is hampered by mucosal edema which can persist for many months post-RT. Therefore, any (non-invasive) method helping in the detection of recurrence is welcome.

Patients at risk for local failure after RT can be successfully identified by a post-RT CT (or MR) study between 1 to 6 months after RT. The optimal time-point to perform such a 'base-line study' seems to be about 3 to 4 months post-RT. Patients with indeterminate findings are candidates for 'imaging surveillance'; i.e. follow-up imaging every 3 to 4 months up to a period of 2 years after RT. However, ongoing studies suggest that metabolic imaging (FDG-PET) may detect local recurrences with a higher accuracy than 'conventional' anatomically based imaging techniques, such as CT and MR.

CT and/or MR-findings in the treated neck are frequently inconclusive. At present, new techniques are available to detect recurrent cancer. PET-CT is widely applied in the post-treatment setting. Also, advanced MR-techniques such as Diffusion Weighted Imaging (DWI) and Dynamic Contrast-enhanced MR (DCE-MR) can be applied. The power of these techniques (as well as the limitations) will be shown during the presentation using imaging examples from daily practice.

Take Home Points:

- A baseline CT or MR study is best performed about 3 to 4 months post (chemo)RT.
- Such a baseline study can be used to identify patients at risk for local failure.

- A negative PET-CT post (chemo)RT is a strong indicator for complete response.
- There is an evolving role for DWI-MR in then detection of residual or recurrent disease.

Keywords: Imaging, Chemo-Radiotherapy, Post chemo

SS 6.1.
CN VII palsy

B. Verbist; Leiden/NL

Short Summary: The facial nerve is a complex, mixed nerve with motor fibers, parasympathetic fibers, sensory fibers to the external auditory canal and special sensory (taste) fibers to the tongue. Facial palsy has severe functional consequences which require immediate symptomatic treatment to prevent complications. The most common cause of facial palsy is Bell's palsy, an idiopathic paralysis, but paresis or paralysis of facial muscles may also be caused by other conditions such as developmental abnormalities, infectious or inflammatory disease or tumoral lesions. In this lecture the indications for imaging, choice of imaging modality and possible imaging findings in case of facial palsy will be discussed.

Take Home Points:
- When evaluating for peripheral facial palsy the brainstem and parotid should be included into the imaging protocol.
- Imaging for peripheral facial palsy should be considered in case of an abnormal clinical course or if there are associated symptoms or clinical findings pointing at an underlying disease

Keywords: Cranial nerve deficit, Facial nerve palsy, Bell's palsy

SS 6.2.
Temporal bone trauma and its complications

V. Chong; Singapore/SG

Short Summary: The temporal bone is the most complex bone in the body. It contains many structures with important functions such as hearing and the maintenance of equilibrium. Injury to the facial nerve is also a well-known complication.

Fractures of the temporal bone are traditionally divided into longitudinal and transverse fractures. This classification was initially proposed as a result of experiments involving direct blunt trauma to the front (or back) and the side of cadaveric heads. These fractures are classified according to the orientation of the fractures to the long axis of the temporal bone. However, in clinical practice fractures are often complex and do not align themselves neatly along the longitudinal or transverse axis. However, the traditional classification is still useful in understanding the mechanisms of injury and predicting the structures likely to be injured.

Ninety percent of all temporal bone fractures are longitudinally oriented. They typically involve the tympanic membrane and ossicles. These fractures may extend medially to involve the genu of the facial nerve. Facial nerve palsy under most conditions recovers after three to four months. As the dense bone surrounding the otic capsule is very resistant to damage,

longitudinal fractures do not usually involve inner ear structures. The tegmen tympani may also be injured and in rare cases result in CSF otorrhoea.

Transverse fractures are much less commonly encountered. They usually traverse the temporal bone medial to the middle ear cavity and hence have a higher likelihood of injuring the otic capsule and cranial nerves VII and VIII. Injuries may result in severe vertigo as a result of damage to the semi circular canals or leakage of perilymph. Transverse fracture associated injuries usually have poorer prognosis. This is related to both the greater physical force required to produce such fractures and the more vulnerable nature of the involved structures.

Take Home Points:

- Longitudinal fractures can involve the tympanic membrane, ossicles, facial nerve or result in CSF rhinorrhea
- Transverse fractures typical involve the otic capsue, CN VII and CN VIII
- Transverse fractures are much less common than longitudinal fractures but the injuries are more severe

Keywords: Temporal bone injuries, Facial nerve palsy, Hearing loss, Vertigo, Otorrhoea

SS 6.3.
Contemporary imaging issues in pulsatile and non-pulsatile tinnitus

H.F. Harnsberger; Utah/US

Short Summary: In this presentation the root causes of pulsatile and non-pulsatile tinnitus will be reviewed. Initially the multiple types of tinnitus will be defined and imaging recommendations presented based on the type of tinnitus present. Non-pulsatile tinnitus (PT) is a continuous ringing or buzzing sound perceived the patient when no external sound is present. PT is a pulse synchronous low (venous) or high (arterial) pitched sound that may be heard by patient & physician (objective PT) or by the patient alone (subjective PT).

Imaging in the clinical setting of non-PT is generally unrewarding except when sensorineural hearing loss is also present and vestibular schwannoma found. When a patient present with PT, especially when it is objective PT, imaging yields rise considerably. CTA-V or enhanced MR with MRA & MRV are both acceptable imaging approaches when patients have PT.

A differential diagnosis list for the symptom of PT is first reviewed. Miscellaneous causes of PT include idiopathic intracranial hypertension (IIH) and superior semicircular canal dehiscence. Arterial causes are internal carotid artery (ICA) dissection, pseudoaneurysm, aneurysm as well as aberrant ICA. Venous diseases that may cause PT are dural AV fistula, dehiscent jugular bulb, sigmoid sinus diverticulum and dural sinus stenosis. Finally, tumors that may cause PT include glomus jugulare and tympanicum paraganglioma as well as meningioma of the temporal bone and jugular foramen area. IIH has been associated with dehiscent jugular bulb, sigmoid sinus diverticulum and dural sinus stenosis.

Each of these diagnoses will be elaborated with a discussion of key facts and case examples in order to familiarize the audience with key radiologic findings that allow the radiologist

to diagnose both the common and rare lesions that appear in the differential diagnosis of patients presenting with pulsatile tinnitus.

Take Home Points:

- Learn the multiple definitions for the multiple types of tinnitus.
- Understand the differential diagnosis for pulsatile tinnitus.
- Recognize the imaging findings that allow the radiologist to diagnose the diseases that cause pulstatile tinnitus.

Keywords: Non-pulsatile tinnitus, Pulsatile tinnitus, Diopathic intracranial hypertension

Friday, September 25, 2015

RC 1
Imaging of nasopharynx

J.W. Casselman; Bruges/BE

Short Summary: Today MR is the technique of choice to study the nasopharynx. It's excellent contrast and spatial resolution allows better visualisation of the soft tissues, perineural spread and bone marrow invasion. The only advantage of CT is the detection of early cortical erosions. Variations in the lymphoid tissue in the nasopharynx and congenital malformations can easily be recognized on MR. Benign lesions and pseudotumors must be recognized and distinguished from malignant lesions. Some of these lesions like juvenile angiofibromas, Thornwaldt's cysts, lymphangiomas etc. have almost pathognomonic characteristics and are easy to recognize, other lesions require biopsy which can be taken under CT guidance when needed. Of course the major indication for imaging is staging in case of malignant tumors. The majority of these tumors are squamous cell carcinomas, adenocarcinomas and lymphomas. Imaging should focus on perineural and perivascular tumor extension and on potential invasion of the brain, orbit, parapharyngeal space and masticator space which will result in more accurate radiotherapy planning. Today biomarkers like diffussion (ADC or D-IVIM), perfusion and permeability should be included in the imaging protocol for malignant nasopharynx tumors. The perfusion histogram and diffussion values can already help in the diagnosis and low ADC values (< 0.6 10^{-3} mm^2/sec) are typically seen in lymphomas. Moreover, permeability (e.g. Ktrans, AUC90 etc) can predict the respons to radiotherapy and/or chemotherapy and also are predictors of final outcome. Changes in the ADC/D value and changes in the type of perfusion histogram can be used to monitor the response during therapy. Finally these biomarkers can also be used to distinguish tumor recurrence from post therapy alterations and are challenging todays golden standard "PET-CT" for this indication. All the above will be discussed and illustrated in this presentation.

Take Home Points:
- Know the best imaging techniques used to study the nasopharynx
- Know the most frequent congenital, benign and malignant lesions of the nasopharynx
- Recognize the most important extensions of nasopharynx tumors
- Learn which biomarkers are used: to predict tumor response and outcome, for tumor monitoring, and for differentiation between tumor recurrence and post-therapy changes

Keywords: Nasopharynx, Magnetic Resonance Imaging, Tumors, Biomarkers

RC 2
Imaging of the anterior and central skull base

A. Borges; Lisbon/PT

Short Summary: As clinical assessment of the skull base is limited, diagnosis and further management of patients with skull base lesions heavily rely on imaging studies. Being a frontier between the intracranial compartment and the extra-cranial head & neck the anatomy of this area is particularly challenging, pierced by numerous foramina and canals through which neurovascular structures cross from one compartment to the other. Pathologic processes affecting the skull base span a wide gamut ranging from lesions intrinsic to the skull base proper, to those originating from the neighbouring intra and extracranial structures. CT and MRI have a complementary role in the evaluation of patients with skull base lesions the former providing a roadmap of bone anatomy and the latter detailed characterization of the soft tissue component and its relationship with adjacent structures. This review will focus on the advances on imaging technique; contribution to patient's management and on the imaging features of the most common lesions affecting the anterior and central skull base. The most relevant information that should be conveyed to surgeons and radiation oncologists will be highlighted. Although the main role of imaging is to provide a roadmap of lesion extent, not uncommonly a good prediction of the final diagnosis can be reached by looking to the apparent site of origin, pattern of growth and tissue characteristics of a given lesion. Imaging is also particularly valuable in depicting "do not biopsy lesions" such as aneurysms and cephaloceles.

Take Home Points:

- Imaging of the skull base requires detailed knowledge of skull base anatomy
- CT and MRI have a complementary role in the evaluation of the full extent of a lesion
- Lesions affecting the skull base may be intrinsic or originate from the intra or extracranial head and neck
- Differential diagnosis is based on the apparent site of origin, pattern of growth and tissue characteristics

Keywords: Anterior skull base, Central skull base, Imaging the skull base, Skull base pathology, Skull base tumors

SS 7.1.
Congenital lesions of the neck
H. Imhof; Vienna/AT

Short Summary: The most common cystic masses in the paediatric neck are congenital lesions. Thyroglossal duct cysts (TGDC) account for 70–90% of all congenital neck cysts in children. 75% are in midline, 25% suprahyoidal, 50% in the region of the hyoid bone, 20% infrahyoidal. In 1% a papillary Ca may develop within the TGDC. 2nd Branchial cleft cysts represent 95% of all branchial cleft cysts. All of them may be cystic, may change size and wall thickness during infection or show a Fistula. They are situated around the sternocleido m. and carotid space. US, CT and MRI are the standard imaging procedure. Fistulas are best seen with CT-fistulography. US is the imaging choice in TGDC. It proves also the presence of normal thyroid gland. In unclear cases Tc99m scintigraphy is the method of choice. In large/deep cystic lesions MRI (or CT) with contrast are used as initial imaging modality. In vascular malformations MRI is the preferred imaging modality. But in the majority of vascular malformations no imaging is needed, because the vast majority of those lesions will resolve on its own. Vascular malformation are divided in slow flow (venous, capillary, lymphatic) and high flow lesions (arterial). Venous malformations are most common. They may show phleboliths. Lymphatic malformations are typically post. cervical and multiseptated, with fluid-blood levels. Infantile hemangiomas (= most common tumor in infants) are neoplastic proliferations. 90% are resolved by 9 years. A thymopharyngeal duct cyst is a 3rd pouch remnant of the branchial apparatus. It shows a typical location and may reach into the mediastinum. It is very often combined with left sided thyroiditis.

Take Home Points: The most common congenital malformation is TGDC. The 2. Branchial cleft cyst is next. Branchial cleft cysts or fistulas are located at the sternocleidomastoid m. and carotid space, except the 4. Branchial cleft anomaly which is typically combined with a left sided thyroiditis. The most common vascular malformation which may need imaging is a venous malformity. Imaging is best done with US, MRI and CT-fistulography

Keywords: Congenital lesion, Thyroglossal duct cyst, Branchial cleft cyst, Thymopharyngeal duct cyst, Vascular malformation, Infantile hemangioma

SS 7.2.
Neck swelling
B.F. Schuknecht; Zurich/CH

Short Summary: The assessment of any head and neck lesion leading to swelling of the neck should follow a tissue based and space related approach. The choice of diagnostic technique is based on the age and condition of the patient, should integrate the clinical history (time course, duration, and location of swelling), and knowledge of any concomitant or prior disease.

Lesions are anatomically categorized into suprahyoid and infrahyoid neck locations. Based on imaging and clinical information attribution to an inflammatory, neoplastic, developmental

or vascular etiology will be feasible. A potential neoplastic etiology or postreatment f-up will require an additional perfusion MR and lymph node staging, while a vascular etiology is categorized into high and low flow lesions based on 4D MRA.

H&N pseudotumors are increasingly recognized as tumefactive or diffuse lesions. The previously descriptive nomenclature has been dichotomized into two entities: IgG4-related disease (IgG4-RD) and inflammatory myofibroblastic tumour (IMFT). IgG4-RD and IMFT originally attributed to the pancreas and lungs respectively affect the H&N as the second most common site.

Lesion location and extension, attribution to the space and tissue of origin are assessed by MR. Supplemented by DWI, by CT at the skull base or based on previous ultrasound assessment in infrahyoild lesion this approach yields the most sensitive soft tissue information.

PET-CT or –MR is commonly added to the diagnostic armementarium for staging in neoplasm of unknown primary (CUP), T3 malignancies or f-up in N2 neoplasms with a tendency for systemic spread such as adeno- or adenooidcystic carcinoma. Diagnostic procedures such as CT guided biopsy are occasionally required to assure histology noninvasively particularly at the skull base.

Take Home Points:

- Clinical information are a prereqisite in adequate imaging assessment of H&N lesiosn leading to swelling
- MR provides superior space related and tissue based information enabling categorizing lesions into inflammatory, neoplastic, vascular, congenital or - increasingly pseudotumoral
- Supplementary imaging by US CT, PET-CT is recommendable.
- MR Sequences such as diffusion, perfusion, 4D MRA are a must in particularclinical circumstances or imaging findings
- CT guided biopsy may support noninvasive acquisition of histology

Keywords: Swelling in the head and neck, Spatial and tissue based imaging information, Etiology and therapeutic relevant information

SS 7.2.
MSK system lesions in the neck

I. Noebauer-Huhmann; Vienna/AT

Short Summary: Primary osseous and soft tissue tumours, and tumour-like lesions of the neck are rare. This leads to frequent diagnostic delay or misdiagnosis, which is of importance, especially in the few patients with unsuspected malignancy. By the use of ultrasound, some entities which are clearly benign and do not require further imaging, can be identified. In the other lesions, MR is the imaging modality of choice; additionally, radiography or CT should be performed. Lesions that are indeterminate or likely malignant require histologic diagnosis. Systematic imaging analysis allows to better determine aggressive lesions (e.g. Ewing sarcoma), and helps to identify typical imaging features, e.g. in chondrosarcoma, chordoma,

ABC, lipomatous lesions, or synovial sarcoma. Staging of MSK system lesions in the neck will be discussed with examples. Osseous metastases occur frequently in the spine, and pathologic vertebral fractures have to be differentiated from insufficiency fractures, which become more likely after irradiation.

Take Home Points:

- To understand the basic principles and algorithms in the diagnosis of tumours and tumour-like lesions of the neck region.
- To become familiar with the most important entities and their typical imaging presentations, with regard to bone and soft tissue lesions.
- To learn about important pitfalls and differential diagnoses of tumours in the neck region

Keywords: MSK, Lesions, Neck

SS 8.1.
Double vision and vision loss

M. Lemmerling; Beervelde/BE

Short Summary: Vision loss can be caused by a wide variety of diseases. Only occasionally imaging will be used to come to a diagnosis. MRI is the prefered technique to visualize the optic pathways (optic nerves, chiasm and tracts, geniculate nuclei, and visual areas in the occipital lobes). Coronal images - especially fat-suppressed T2- and postgadolinium T1-weighted images - are very useful to image the optic nerve. Common indications for optic nerve imaging are suspicion of optic neuritis (mostly related to MS), or optic nerve tumor (most frequently glioma, and sometimes meningioma). Low grade optic nerve gliomas are most frequent in children (often with NF I). Optic nerve sheath meningiomas are rare and most frequently occur in middle aged females.

The oculomotor, trochlear and abducens nerves (N. III, IV, and VI) are responsible for eyeball motion. The trochlear and abducens nerve respectively innervate the superior oblique muscle and the lateral rectus muscle. All other eyeball muscles, as well as the levator palpebrae superioris muscle, are supplied by the oculomotor nerve. These 3 nerves have a common course through the cavernous sinus and the superior orbital fissure towards the orbit. Imaging of these nerves is often done in non-diabetic patients with diplopia. Frequently seen anomalies are brain stem ischemia, infectious or malignant meningeal disease along the cisternal course of the nerves, or infectious or tumoral lesions in the cavernous sinus, superior orbital fissure, or orbit. Interpretation of the MRI scans using a segmental approach helps to narrow down the differential diagnosis.

Take Home Points:

- MRI is an excellent technique to visualize the optic, oculomotor, trochlear and abducens nerves.
- During interpretation of these MRI scans using a segmental approach helps to narrow down the differential diagnosis.

Keywords: Vision loss, Diplopia, MRI

SS 8.2.
Exophtalmus and enophtalmus

S. Langner; Greifswald/DE

Short Summary: Exophthalmus and Enophthalmus can be related to orbital disease and to lesions of the globe. Normal anatomy and typical imaging findings in ex- and enophthalmus are described. Typical underlying conditions are discussed and an imaging strategy is presented.

Take Home Points:
- Exopthalmus and enophthalmus are a clinical sign for orbital disease.
- Beside infectious and inflammatory condiftions, tumors and vascular processes should be considered in the differential diagnosis.
- MR imaging is the modality of choice for the assessment of patients with ex- and enophthalmus.

Keywords: Exophthalmos, Enophthalmus, Orbital disease, MR imaging

SS 8.3.
Naso-lacrimal pathways: Diagnostic evaluation

A. Maliborski; Warsaw/PL

Short Summary: The excessive watering is a common condition in ophthalmological practice. It may be the result of excessive production of tear fluid, obstruction and insufficiency of efferent tear pathways.

Good knowledge of radiographic anatomy of the lacrimal system, diagnostic methods, signs, as well as physiology of tear outflow is an essential factor in proper interpretation of test results.

Take Home Points:
- The lacrimal fluid produced by the lacrimal glands is spread across the surface of the cornea and conjunctiva and penetrates through lacrimal puncta into lacrimal drainage system formed by lacrimal canaliculi, lacrimal sac and nasolacrimal ducts. Lacrimal system shapes and valves are presented on fig.1. Lacrimal puncta and canaliculi form the upper lacrimal pathways. Lacrimal sac and nasolacrimal ducts build lower floor of the lacrimal drainage system. The mucous membrane folds form a type of valves in the lacrimal pathways and their main function is to block the backward tears outflow and limit the spread of the pathological processes. The majority of obstructions originate at the level of those valves.
- Key causes of pathological eye watering (epiphora) are: abnormal tear drainage caused by the primarily acquired nasolacrimal duct obstruction, lacrimal pathways stenosis, improperly positioned or narrowed lacrimal puncta and insufficiency of the lacrimal pathways. The obstruction may be due to congenital stenosis, inflammatory disease, calculi, trauma, foreign bodies or tumors. In the diagnostic process it is necessary to perform clinical tests, and often additional diagnostic imaging. Especially the differentiation of obstruction and insufficiency of the lacrimal pathways is still clinical difficult. In the diagnosis of the lacrimal

pathways obstruction the most commonly used clinical tests are: irrigation test, fluorescein dye disappearance test, primary and secondary Jones tests. Due to difficulties in diagnosing lacrimal drainage obstruction and the correct classification of the nasolacrimal pathway obstruction/malfunction (failure), the primary objective evaluation needs to be broadened to include additional diagnostic imaging procedures. Dacryocystography (fig.2) allows the radiologist to visualize both morphological and functional disorders of the lacrimal apparatus and provide information for further management, especially surgical treatment. Increasingly other techniques are used in diagnostic imaging of lacrimal tract such as ultrasound,computed tomography,magnetic resonance and isotopic methods.

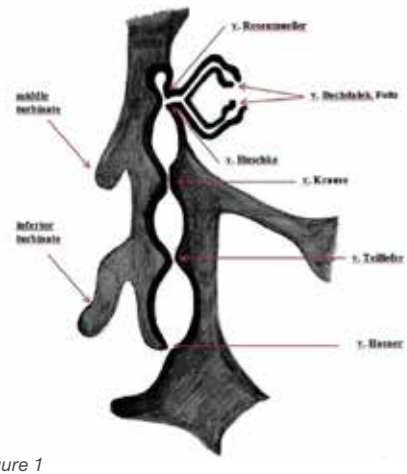

Figure 1

Figure 2

Keywords: Lacrimal drainage system, Dacryocystography, Epiphora, Nasolacrimal duct obstruction

SS 9.1.
Vascular pathologies and related diseases
S. Rohde; Dortmund/DE

Short Summary: The first part of this lecture will repeat the anatomy of the supraaortal vessels and the cranial nerves.

The first part will focus on the anatomy of the cervical branches of the external and internal carotid artery, the vertebral artery, and the thyreo-cervical trunc, anatomical variants and most important intra- and extracranial collaterals.

The second part will repeat the anatomy of the cranial nerves with emphasis on the anatomy of the scull base.

Take Home Points: Vascular anatomy of the neck, important intra-extracranial collaterals, cranial nerve anatomy, skull base.

Keywords: Anatomy, External carotid artery, Internal carotid artery, Cranial nerves, Skull base

SS 9.3.
Unexpected findings: With tumours concerning carotid space
K. Pyra; Lublin/PL

Short Summary: The lecture will cover the unexpected findings concerning carotid space: tumors, vascular malformations, aneurysms and other unusual findings, their differential diagnosis and treatment.

Take Home Points: Benign and malignant tumors can arise from any of the structures contained within the space between skull base to the aortic arch. Such tumors are rare but it should be kept in mind. The history and physical examination can provide clues to the site of origin and nature of a carotid space tumor, imaging studies are more useful for defining the site of origin and extent of the mass, as well as its vascularity and relationship to the great vessels of the neck and other neurovascular structures.

Keywords: Carotid space, Unexpected findings, Aneurysm, Vascular malformations

SS 10.1.
Unilateral opacification of a sinus: Diagnostic approach
H.B. Eggesbø; Oslo/NO

Short Summary: Unilateral opacification of a sinus should always question a differential diagnosis other than rhinosinusitis. Both benign and malignant conditions may cause unilateral disease, and correct interpretation starts with an optimal imaging protocol.

Computed tomography (CT) is the gold standard and working horse in paranasal sinus imaging. CT in combination with endoscopic examination with or without biopsy will in most cases lead to a diagnosis. Complementary magnetic resonance imaging (MRI) in pretreatment planning of malignant tumours and in case of inflammatory complications is often valuable.

At CT, dental fillings may cause artifacts to the sinuses, therefore the volume uptake must be performed in the axial plane. Though artifacts will occur, the scan must include the whole premolar and molar teeth in the upper jaw in order to look for a dental cause to sinus opacification.

Reconstruction with bone algorithm and thin slices (preferably 0.625 mm) in axial and coronal planes is mandatory. Sagittal and oblique planes can be performed depending on localization of pathology.

At bone algorithm the radiologist should look for: a dental cause; sclerotic bone, indicating chronic inflammatory disease (fig 1); sinus expansion with bone remodelling or demineralization, characteristic for muco- and pyoceles; bone erosion or destruction, which can be seen in malignant conditions and in vasculitidis.

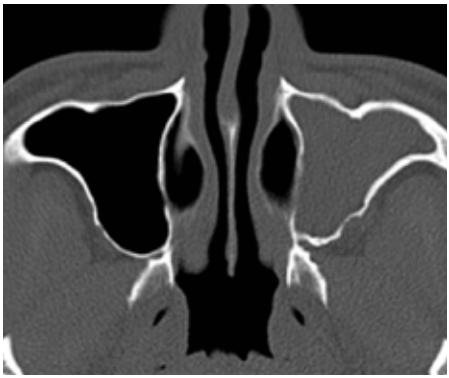

Figure 1

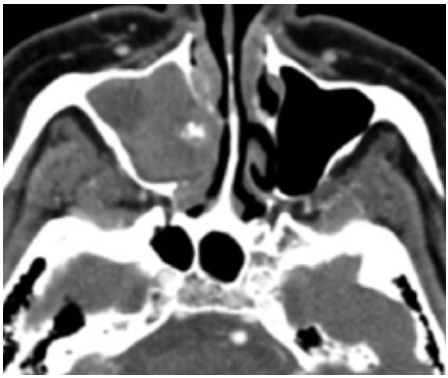

Figure 2

Additional reconstruction with soft-tissue algorithm and slice thickness 2.5 mm may offer better characterization of the opacifications. High attenuation may be seen in a pyocele, while a mucocele has low attenuation; in allergic fungal sinusitis (usually more than one sinus affected, while a pyocele usually affect only one sinus); and in bleeding.

Scattered calcifications must always include fungus ball (mycetoma) (fig 2) in the differential diagnoses, and if combined with obliteration of the fat plane outside the sinus wall, even with intact bone, invasive fungal sinusitis must be suspected.

Bone algorithm alone is often sufficient when the opacification is limited to moderate mucosal thickening, retention cysts or fluid.

Take Home Points: To learn how optimal paranasal sinus CT technique can be used in the interpretation of unilateral opacification in order to narrow the differential diagnoses.

Keywords: Paranasal sinuses, Unilateral, Opacification

SS 10.2.
Chronic rhino-sinusitis: Understanding problem
L. Grzycka-Kowalczyk; Lublin/PL

Short Summary: Sinusits is responsible for 11.6 million office visits and $2.4 billion in direct medical costs annually in the United States. Scores on the quality-of-life index are similar to those of patients with chronic heart disease, angina, and chronic obstructive pulmonary disease.

Chronic Rhinosinusitis in adults is in most guidelines defined as an inflammation of the nose and the paranasal sinuses characterised by at least 8-12 weeks of at least 2 symptoms, like nasal blockage/obstruction/congestion, nasal discharge (anterior/posterior nasal drip), facial pain/pressure and/or reduction or loss of smell and either endoscopic signs of disease or relevant CT scan changes.

This presentation focuses on CT and MR appearance of rhino-sinusitis, as well as factors contributing to its pathogenesis including anatomic factors, disturbances in mucociliary clearance, pathogens, and inflammatory factors.

Take Home Points: Chronic sinusitis is one of the more prevalent chronic illnesses affecting persons of all age groups. Scores on the quality-of-life index are similar to those of patients with chronic heart disease, angina, and chronic obstructive pulmonary disease.

Keywords: Chronic, Sinusitis, CT appearance

SS 10.3.
CRadiological evaluation for FESS
T. Beale; London/UK

Short Summary: I will highlight the anatomical variants that are of concern to the surgeon pre FESS.

I hope to demonstrate how to describe the various patterns of sinonasal inflammatory disease and how they affect the surgical planning.

The CT/MRI appearances post different FESS procedures will be demonstrated including post FESS complications

Take Home Points:
- Know the relevant sinonasal anatomical variants and when to mention in the report
- Recognise the post FESS CT/MR appearances and possible complications
- Understand the different patterns of sinonasal disease and how they affect the treatment/ surgical planning.

Keywords: Anatomical variant, Drainage pathways, FESS, Sinonasal

SOPS 3.1.
Validating a threshold of ocular gaze deviation for the prediction of acute ischaemic stroke.

E. Woo[1], D. McKean[2], M. Kudari[2], M. Landells[2], D. Grant[2], S. Johnson[2], L. Lopez de Heredia[1], S. Yanny[1]; [1]Aylesbury/UK, [2]Oxford/UK

Short Summary: We present a study which determine a threshold at which the degree of ocular gaze deviation (OGD) on axial imaging is highly specific for the prediction of acute ischaemic stroke.

Rather like the dense artery sign and insula ribbon signs, this could help in the interpretation of CT head in suspected acute ischaemic stroke.

Purpose/Objectives: To determine a threshold at which the degree of ocular gaze deviation (OGD) on axial imaging is highly specific for the prediction of acute ischaemic stroke.

Methods and Materials: A retrospective analysis of 517 patients who had received MRI with diffusion-weighted imaging (DWI) for suspected acute stroke was performed. The degree of OGD was measured in all patients and the presence and location of infarction determined. The difference in OGD between groups was compared using the independent t-test for normally distributed data and the Mann Whitney test for non-normal data. The sensitivity and specificity for degrees of OGD in the prediction of acute infarction was calculated using a receiver operating curve (ROC) analysis.

Results: The imaging of 448 patients meeting the inclusion criteria was reviewed. Acute infarct was demonstrated in 34.8% (n1⁄4156). There was a significant difference in the degree of OGD between patients with an acute infarct and those without evidence of acute ischaemia ($p<0.001$). ROC curve analysis for OGD demonstrated area under the curve (AUC) 1⁄4 0.619 with increasing degrees of OGD more specific for acute infarct. OGD >11.95 had a sensitivity of 17% and specificity of 95.9% in predicting acute infarction.

Conclusion: Significant OGD>11.95 has a high specificity for acute infarct. This threshold may provide a helpful additional sign in the detection of subtle acute infarct, particularly on axial CT brain imaging.

Keywords: Ocular, Stroke, MRI

SOPS 3.2.
Is Migraine Related With Medial Meningeal Artery and Spinous Foramen Caliber

H. Nalbant, E. Nalbant, L. Pasaoglu, U. Toprak; Ankara/TR

Short Summary: Migraine which is as ancient as human history is an important condition. It's typically chronic, incapacitating neurovascular disorder characterized by attacks of severe, throbbing, unilateral headache, autonomic nervous system dysfunction, and in some patients an aura involving neurologic symptoms. Migraine is one of the most run to a doctor reason in headache disorders and still it doesn't have a specific diagnostic laboratory or radiologic test.

Although migraine pathophysiology has not known yet, dura mater and it's vasculature; medial meningeal artery and the venous system has been the center of the hypoteses submitted to explain migraine pathophysiology. Vasodilatation of the intracranial vasculature is widely believed to cause the migraine headache. On the other hand currently some hypotheses decrease the role of the vasodilatation.

One of the most cranial CT indications is headache. If we can show medial meningeal artery caliber difference in migraine patients that could help to diagnose migraine with CT. On the other hand if there is a chronic vasodilatation in medial meningeal artery that also could cause increased caliber of foramen spinosum.

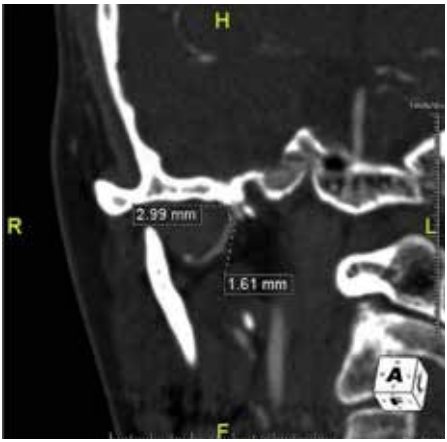

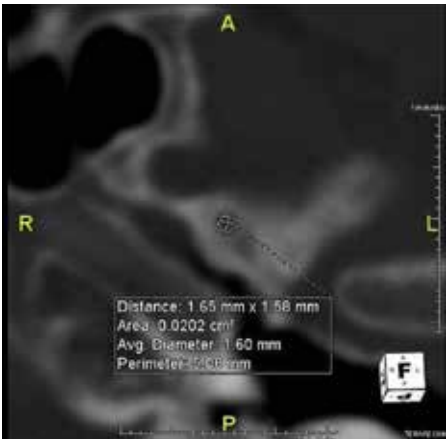

Purpose/Objectives: In our study we have purposed to research whether there is a significant difference between the migraine and tension type headache as control group patients' medial meningeal artery, maxillary artery and spinous canal calibers.

Methods and Materials: Thirty-six migraine patients and 26 tension type headache patients, which are control group were involved in the study. Patients were scanned with brain CT anjiography. Both migraine and tension type headache patients' medial meningeal artery, maxillary artery and spinous canal calibers were measured. The datas were analysed with SPSS 15.0 programe.

Results: There was no statistically significant difference between migraine and tension type headache patients' measurements.

Conclusion: In our study we couldn't found any evidence to show vasodilatation of the duramater's vasculature as a factor of the migraine pathophysiology. This result is important to indicate the need to investigate the different hypotheses for migraine pathopysiology.

Keywords: Migraine pathophysiology, Multislice CT angiography, Medial meningeal artery, Foramen spinosum

SOPS 3.3.
Ambigous and surprising cases in jaw pathologies

B. Ruhin[1], P. Goudot[1], F. Gruffaz[2], J. Chiras[2], D. Dormont[2], N. Martin-Duverneuil[2];
[1]Paris Cedex/FR, [2]Paris/FR

Short Summary:

(1) Stomatology and Maxillofacial Surgery Department (Pr Goudot), Pitié-Salpêtrière University Hospital, Pierre and Marie Curie University-Paris6, Paris, F-75013 France

(2) INSERM UMRS 872, Orofacial Biology and Pathology Department, Equipe 5 (Pr Berdal), Les Cordeliers, Paris, F-75006 France; Pierre and Marie Curie University-Paris6, UMR S 872, Paris F-75006 France; René Descartes University-Paris5, UMR S 872, Paris F-75006 France

(3) Anatomopathology and Histology Department (Pr Capron), Pitié-Salpêtrière University Hospital, Pierre and Marie Curie University-Paris6, Paris, F-75013 France

(4) Neuroradiology Department (Pr Dormont), Pitié-Salpêtrière University Hospital, Pierre and Marie Curie University-Paris6, Paris, F-75013 France

Purpose/Objectives: Because of their own experience in jaw pathologies, the authors expose here a series of interesting cases which are ambiguous and surprising.

Methods and Materials: This is the author experience with special emphasis on retrospective review of 47762 orofacial histological samples, clinicopathological notes, radiographs and therapeutic outcome of patients with jaw tumors seen in the Oral and Maxillofacial Surgery Department of an University Hospital, between 1992 and 2015 (23-year-period). Furthermore, in the last five years, about 2500 Cone Beam Computed Tomography have been realized on these different pathologies.

Results: Series of interesting cases which are ambiguous and surprising

Conclusion: Owing to cohabitation between oral septic cavity, teeth and bone, jaw bone lesions are numerous and complicated: odontogenic or not, infectious or not, tumoral or pseudotumoral, benign or malignant lesions. Therefore, although they need to take advantage of clinical and radiological signs, their precise identification can be difficult for practitioners

Keywords: Jaws, Bone, CBCT, Tumors, Benign, Malignant

SOPS 3.4.
Pre- and postoperative multi-slice and cone-beam computed tomography in midface trauma

O. Pavlova, N. Serova; Moscow/RU

Short Summary: Pre- and postoperative MSCT and CBCT were compared to establish the diagnostic strategy in patients with midface trauma.

Purpose/Objectives: Pre- and postoperative MSCT and CBCT were compared to establish the best diagnostic strategy in patients with midface trauma.

Methods and Materials: Fifty-two patients with midface trauma were admitted to the hospital on the 1-2 day after the injury. Preoperative MSCT and CBCT scans were performed during the first 3 days of admission. Postoperative MSCT and CBCT images were obtained within 7-10 days after the surgery.

Results: Preoperative MSCT revealed herniation of orbital contents (n=12, 23%), globe trauma (n=3, 6%), injured optic nerve (n=11, 21%), deformation of eye muscles (n=20, 38%) and orbital emphysema (n=10, 19%). As well, fractures of the orbital floor (n=52, 100%), lateral (n=52, 100%), medial (n=8, 15%) and superior (n=3, 6%) orbital walls. MSCT assessed multiply fractures of zygomatic bone and arch (n=36, 69%), anterior and lateral maxillary sinus walls (n=37, 71%).

Preoperative CBCT also managed to reveal fractures of the orbital floor (n=52, 100%), lateral (n=52, 100%), medial (n=8, 15%) and superior (n=3, 6%) orbital walls, multiply fractures of zygomatic bone and arch (n=36, 69%), anterior and lateral maxillary sinus walls (n=37, 71%). However, CBCT couldn't provide detailed diagnostic information about soft tissue trauma, so the extent of orbital content's herniation was estimated indirectly.

Postoperative MSCT managed to assess the remaining herniation in the posterior part of orbital cavity (n=4, 8%), globe trauma (n=3, 6%), deformations of optic nerve (n=6, 12%) and eye muscles (n=3, 6%).

Postoperative CBCT assessed the bone defects in the posterior part of orbital cavity in 4 cases (8%) without diagnostic information about orbital content's herniation. Absence of significant metal artifacts in CBCT facilitated evaluation of implants, osteosynthesis elements and condition of surrounding bone tissue as compared to MSCT, where in 12 (23%) cases the visualization was more difficult.

Conclusion: MSCT is the modality of choice in preoperative and early postoperative periods since CBCT doesn't provide enough information about soft tissue structures. CBCT could be performed in late postoperative period for the evaluation of implants' position and surrounding bone tissue due to the absence of significant metal artifacts.

Keywords: MSCT, CBCT, Midface trauma, Preoperative period, Early postoperative period, Late postoperative period

SOPS 3.5.

Evaluation of flow pattern of arteries in Oral Submucous Fibrosis by color Doppler Ultrasonography

A. Chaurasia; Lucknow/IN

Short Summary: The Oral submucous fibrosis is a premalignant condition characterized by stiffening and fibrosis of oral mucosa.

This study confirms the positive co-relation of alteration in normal Doppler Spectrum or Flow Pattern between oral submucous fibrosis patients and healthy controls. As the severity of fibrosis increases in Oral Submucous Fibrosis there is decrease in Resistivity Index and increase in End Diastolic velocity.

Purpose/Objectives: To evaluate the flow pattern of arteries in Oral Submucous Fiborsis by using Color Doppler Ultrasongraphy

Methods and Materials: Total 80 subjects were selected and were categorized as Group A, Group B and Group C. Group A included 40 clinically diagnosed OSMF patients. Group B included 20 subjects which were having habit of betel nut chewing without OSMF. Group C were included 20 healthy volunteers served as controls. After clinical and histopathological confirmation of oral submucous fibrosis, Color Doppler of main trunk of Facial artery, Buccinator, Superior Labial and Inferior Labial branchs were done on both sides.

Results: After spectrum analysis of color doppler, the normal triphasic, laminar doppler flow pattern found in controls which changes to non laminar flow patterns including Turbulent flow, Thud flow, Reverse flow, Tardus flow, Spectral broadening and Antegrade flow patterns in oral submucous fibrosis patients (Group A) and also in some patients with Group B.

Conclusion: The study confirms the positive co-relation of alteration in normal Doppler Spectrum or Flow Pattern between oral submucous fibrosis patients and healthy controls. As the severity of fibrosis increases in Oral Submucous Fibrosis there is decrease in Resistivity Index and increase in End Diastolic velocity.

Keywords: Oral submucous fibrosis, Color Doppler, Ultrasound, Betel nut

SOPS 3.6.

Sex determination on the basis of Cephalometric forehead angulations

R. Patil; Lucknow/IN

Short Summary: Sex identification is one of the important aspects of forensic sciences. Forensic odontology handles, examines, evaluates and presents dental evidence for forensic investigations. DNA finger typing, cheiloscopy, dental traits and osteometric methods have been adopted by many investigators for morphological assessment of differences in size and shapes of human remains. Although various radiographic methods have been used by forensic odontologists, metric analysis of skull forehead for sex identification using cephalogram have been studied by very few. The study evaluates and compares the angulations of the forehead at various points among human male and female subjects.

Purpose/Objectives: To determine sex on the basis of Cephalometric forehead angulations

Methods and Materials: The study was conducted on 100 subjects. Lateral cephalogram obtained from 50 males and 50 females with age range of 18-26 years were transcribed on acetate sheet. Angulations on forehead and one linear measurement were calculated.

Results: Mean values of angle A, B and C were lower and AD segment was higher in male group when compared to female group. Comparison of mean values of angle B and AD segment between males and females showed statistically significant difference (p value < 0.05). Coefficient of variation of AD segment was least among all variables

Conclusion: This study is an innovative approach to make use of forehead angle measurements as an important landmark in sex identification. It was concluded that angle of curvature was higher in females as compared to males supporting the round forehead in female. Further, the trichion in males was found to be slightly higher than in females.

Keywords: Sex determination, Cephalogram, Forensic odontology

SOPS 4.1.
Importance of Head and Neck radiology training in clinical evaluation of new cancer cases in South-Eastern Sweden Region

B. Kovacsovics; Linköping/SE

Short Summary: The reinterpretations of images of head and neck cancer patients by especially trained and dedicated Head and Neck radiologists changes the TNM stages in approximately in 77% of cases.

Purpose/Objectives: The aim of this study was to examine to which extent the re-evaluation of radiological examinations of head and neck cancer patients by dedicated head and neck radiologists changed the tumour staging, measured as TNM status.

Methods and Materials: In the South-Eastern Health Care Region of Sweden's (population approx 1 million) multidisciplinary Head and Neck cancer conference 134 newly discovered tumour cases were discussed in 2014. Out of the patients were 84 male (63%) and 50 female (37%), mean age 67.1 +/- 12.2 years.

47 (35%) patients underwent radiological examination in the University Hospital in Linköping, staffed by a group of radiologists especially trained in Head and Neck radiology. 85 patients (65%) were examined and interpreted in eight adjunct hospitals by general radiologists and are subsequently reevaluated by the Linköping Head and Neck radiologists for the multidisciplinary conference.

Results: In 67 cases (77%) (37% - 90% depending on hospital studied) the re-evaluation changed the original TNM staging, with a downgrading in four patients and upgrading in 63 cases. The changes according to locations were the following: 3 out of 4 (75%) hypopharynx, 11/17 (65%) larynx, 1 out of 3 (33%) nasopharynx, 16/25 (64%) oropharynx, 15/22 (68%) oropharynx, 3 out of 5 (60%) salivary gland, 3 out of 5 (60%) sinus, and 2 out of 3 (66%) for

unknown primary cancers. In two cases the primary tumour was originally placed in the oral cavity instead of the oropharynx, thus having severe therapeutic implications.

The N staging was changed in 12 of 59 cases, where 4 was an upgrading, and 8 a downgrading including 4 cases where no metastases were found.

Conclusion: The reinterpretations of images by especially trained and dedicated Head and Neck radiologists changes the TNM stages in a significant number of cases.

Keywords: Subspecialization, Clinical reinterpretation, Cancer

SOPS 4.2.

How accurate is conventional MRI in staging oral cavity carcinomas?

L. Ismail, R. Lingam, H. De Silva; London/UK

Short Summary: MRI is used to stage oral cavity carcinomas. Accurate tumour staging is important as it influences treatment strategy and prognosis.

Purpose/Objectives: The study aims to investigate the performance of conventional MRI in staging oral cavity carcinomas (AJCC T-stage), with interobserver agreement assessment.

Methods and Materials: This retrospective study includes 37 cases of histologically confirmed oral cavity squamous carcinoma who underwent pre-operative conventional MRI staging (using AJCC T staging). MRI staging was performed independently by 2 radiologists. The final staging (gold standard) was done on histological analysis after surgical excision and was compared with the MRI staging.

Interobserver agreement and performance statistics of MRI staging was calculated.

Results: There were 24 oral tongue carcinomas, 11 buccal mucosa carcinomas and 2 gingival carcinomas. 27/37 (73%) carcinomas were correctly staged. A variety of factors contributed to incorrect MRI staging and included inaccurate size estimation for tumours near size staging cut-off at 2cm or 4cm, post-biopsy changes and undetected bone invasion. A more detailed analysis will be presented and illustrated with cases.

Conclusion: MRI accurately staged 73% of oral cavity carcinomas in our case series.

Keywords: Oral cavity carcinoma, MRI, Staging

SOPS 4.3.

Absence/atrophy of the anterior belly of the digastric muscle.

C. Bowles, D. Gibson, P. Brennan; Portsmouth/UK

Short Summary: Muscle duplications in the head and neck region have been previously reported. However, congenital absence or atrophy of the anterior belly of the digastric muscle is an uncommon finding with surgical implications. This muscle is an important landmark during neck dissections. We established the incidence of anterior digastric absence or atrophy; discuss the pertinent embryology and the potential causative factors.

Purpose/Objectives: The digastric muscle has distinct anterior and posterior bellies with different embryological origins. These are anatomically contiguous via an intermediate, junctional tendon attached to the lesser horn of the hyoid bone. As a common surgical landmark, we sought to determine the incidence of congenital absence or atrophy of the anterior belly of the digastric muscle, to discuss the embryological relevance and to propose potential causes for atrophy or absence.

Methods and Materials: A retrospective review was performed of 1484 routine neck ultrasound examinations over a six year period by a single experienced Head and Neck radiologist.

Results: 1484 routine neck ultrasounds over a six year period demonstrated unilateral anterior belly digastric absence or marked muscle atrophy in only three patients with an incidence of approximately 0.2%. All affected individuals were asymptomatic females with unilateral variations.

The anterior belly of the digastric muscle and the adjacent mylohyoid muscle develop during the fourth week of gestation from the first branchial arch. These muscles share neural innervation from the mylohyoid nerve, a branch of the inferior alveolar nerve, which in turn originates as a division of the mandibular nerve (trigeminal nerve), The posterior belly derives from the second pharyngeal arch and is supplied by the digastric branch of the facial nerve.

Conclusion: Unilateral absence or atrophy of the anterior belly of the digastric muscle has an incidence of approximately 0.2%. The separate embryological derivation and innervation of the two bellies of the digastric muscle dictates that different pathology affects them separately.

Keywords: Digastric, Congenital, Embryology, Atrophy, Anatomy

SOPS 4.4.
Evaluating trabecular bone architecture quantitatively with roughness parameters.

F. Yasar; Konya/TR

Short Summary: Trabecular bone properties of the anterior and posterior mandible of 35 patients are evaluated with cross-sectional CBCT images quantitatively with an image analyzing program and the results are correlated with Hounsfield Units.

Purpose/Objectives: Dental implants are widely used nowadays. The quality and quantity of the available bone influences the success of implant therapy. There are subjective classifications depending on the observer's decision such as Lekholm and Zarb and Misch classifications. The objectives of this study were to evaluate the mandibular anterior and posterior region trabecular architecture roughness properties quantitatively with image analysis program on Cone Beam Computed Tomographic (CBCT) cross sectional images and their correlation with Hounsfield units (HU).

Methods and Materials: CBCT images of 35 patients which were previously exposed for diagnostic needs were included to the study. The cross-sectional images belonging to the anterior and posterior region of the mandible were evaluated with Image J program. Region of interests were created on these images avoiding including anatomical structures such as roots of the teeth, lingual foramen, mandibular canal and periodontal ligament space. The density of these regions were measured as Hounsfield Units and roughness parameters such as Ra (average roughness), highest peak, lowest valley and total height of the same area was obtained with a plug-in named roughness calculation.

Results: Paired sample t-test was used to evaluate whether there were differences between the evaluated parameters of the anterior and posterior mandibular region. All of the parameters evaluated in the study such as Hounsfield Units (p: 0,000), and roughness parameters such as Ra (p: 0,000), highest peak (p: 0,000), lowest valley (p: 0,003) and total height (p: 0,000) showed statistically significant difference between the anterior and posterior region of the mandible. All of the roughness parameters showed positive correlations with Hounsfield units (r: 0,400 to 0, 956).

Conclusion: Roughness parameters are shown to be different in the anterior and posterior region of the mandible and they have a strong correlation with bone density. As these parameters are objective quantitative measurements, they can be used to assess the quality of alveolar bone in implant applications to assess the quality of trabecular bone.

Keywords: Image analysis, Cone beam computed tomography, Trabecular bone, Hounsfield Units

SOPS 4.5.
Knowledge, attitude and practices regarding biomedical and hazardous waste disposal among radiation workers

A. Tripathi[1], B. Tiwari[2], R. Patil[1], V. Khanna[1], V. Singh[1]; [1]Lucknow/IN, [2]New Delhi/IN

Short Summary: This study is a knowledge, attitude and practice study done among radiation workers in the form of survey.

Purpose/Objectives: To evaluate the existing level of knowledge, attitude and practices regarding biomedical and hazardous waste disposal among radiation workers.

Methods and Materials: This knowledge, attitude and practice (KAP) study was done in King George Medical University, Lucknow, India. A self-administered questionnaire was designed and distributed among 97 radiation workers, who included radiology technicians and students undergoing training in diploma in radiology. The survey form composed of 18 questions framed based on knowledge, attitude, and those regarding the practice they followed in

relation to health-care and hazardous waste management. The percentage response for each question from all the participants was obtained and the data was calculated.

Results: The survey was done on 97 individuals with and was attended by 86 of radiology diploma trainee and 11 radiology technicians 56 of respondents underwent training for biomedical waste management out of which 53 could match the color coded bins. 25 of respondents were not aware about the ill effects of harmful chemicals used in the radiology. 3 respondents did not used gloves and worked bare handed on the patients. Only 6 technicians used lead apron for taking radiographs. For oil leakage from the x-ray machine 78 respondents believed in informing the authorities, 4 were indifferent to it, while 15 wanted to clean the oil leakage from the x-ray machine. 12 subjects were not aware of presence of silver in used fixer solution. 83 respondents believed in diluting and throwing used developer in the drain, while 14 wanted to throw it without dilution. All the respondents believed that environmental pollution could be caused by throwing processing chemicals down the drains.

Conclusion: It can be concluded from this survey study that, though many radiation workers have knowledge about the management of waste but are not applying it diligently. It is imperative that waste should be segregated and disposed off in a safe manner to protect the environment as well as human health.

Keywords: Knowledge, Attitude, Radiation worker

Saturday, September 26, 2015

RC 3
Imaging of the jaws and TMJ

C. Czerny; Vienna/AT

Short Summary: Imaging of the temporomandibular joint (TMJ) is mostly performed for imaging functional abnormalities of the joint. In many cases, it is necessary to image in movement to get an impression of the movement of the different parts of the joint and especially of the movement of the disc and the condyle. Imaging is than performed with parasagittal proton-density-weight and T2-weighted sequences and coronal T2-weighted sequences and proton-density-weighted sequences in a movie-mode, but the sequences are dependant on the MRI-unit used.

Other pathologies of the TMJ and jaws can be imaged with CT and MRI. These pathologies include e.g. in most cases inflammation or tumors. PET-CT or PET-MR may also be used.

CT may be used without or with the i.v. application of jodinated contrast material dependant on the pathology. The images can be documented in soft-tissue- and/or bone-window-level-setting. Imaging planes are usually axial, coronal and sagittal depending on the pathology.

MRI has the advantage of higher soft tissue contrast and the possibility to use different sequences. Depending on the pathology, e.g. fatsuppressed T2-weighted, diffusion-weighted, T1weighted sequences before and after the i.v. use of gadolinium and T1-weighted contrast enhanced sequences with fatsuppression are used. The imaging planes maybe axial, coronal, and sagittal.

In this refreshercourse, the pathologies of the TMJ and jaws will be shown, and the imaging characteristics will be explained.

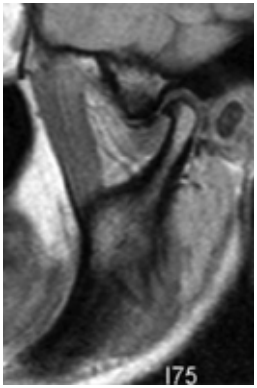

Figure 1: Anterior disc displacement

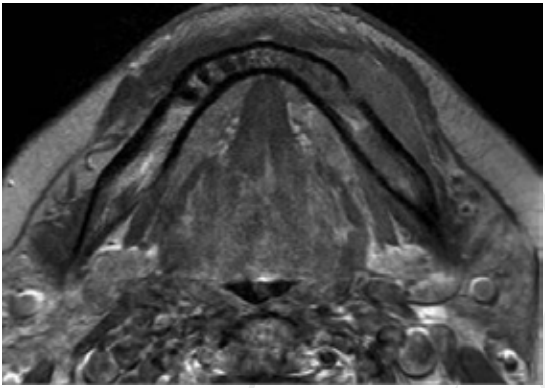

Figure 2: Lymphoma of the mandible

Take Home Points:

TMJ

- MRI -/+ movie excellently shows disc and joint pathology

Jaws

- MRI delineates pathology
- MRI not characteristic
- CT delineates osseous (periostal) structures
- CT and MRI (or PET-CT-MRI) additionally

Keywords: TMJ and Jaws, Internal derangement, Disc displacement, Osteonecrosis, Tumour of jaws

RC 4.1.
Imaging of the masticator space

C.Z. Karaman; Aydin/TR

Short Summary: The masticator space is one of spaces of the face, starting from the angle of the mandible and extends up to the temporalis fossa and calvarium. On each side, the space is outlined by the superficial layer of the deep servical fascia. At the lower border of the mandible this fascia divides into two layers to define the space. The inner layer joins the skull base just medial to foramen ovale, and the outer layer attaches to the zygomatic arc and moves up to encase the temporalis muscle. These two layers of fascia fuse to pack the ramus of mandible anteriorly and posteriorly.

The masticator space contains the manbile, muscles of mastication, and the third branch of the trigeminal nerve.

Vascular lesions, tumors and inflammatory conditions are the concerns of the masticator space. Vascular lesions are not infrequent. Hemangiomas and other vascular malformations may represent with some suggestive imaging findings i.e. phlebolitis on CT.

Primary tumors, malignant or benign arising from muscle, mandible or nerve can be seen as intrinsic lesions. Imaging may be inconclusive in distinguishing malignant from benign, as most of malignant lesions tend to be confined to the space and habitually lack malignant characteristics i.e. bony destruction. Secondary extension may occur directly from surrounding spaces and tissues or by perineural spread.

Inflammatory involvement of the masticator space is frequently odontogenic in origin. Infections may originate from the salivary glands peritonsillar abscess. Owing to the anatomical relationship, infections may reach the temporal fossa and skull base.

Clinical evaluation alone may be generally inconclusive for the lesions of the masticator space. Therefore imaging studies are essential on the diagnostic work up. Magnetic resonance imaging and CT are the preferred imaging modalities. Although MR may be superior to CT owing to its higher soft tissue contrast resolution, these techniques can be used interchangeably or complimentarily.

Take Home Points:
- The masticator space in encased by the superficial layer of the deep servical fascia reaching temporal fossa superficially, and deep to the skull base medially.
- Malignant tumors may sometimes be indistinguishable from benigns.
- MR and CT are preferred imaging modalities which can be used interchangeably.

Keywords: Masticator space, Computed tomography, Magnetic resonance imaging

SL 1.1.
My most unforgettable mistakes

L. Ginsberg; Houston/US

Short Summary: I only wish I could forget them, because my most unforgettable misses are with me most of the time, and all the time when I'm reading out. These mistakes take various forms, but the underlying reasons are similar and typical. I fail to notice the finding, I'm frustrated by the technique, I'm dismissive of the indication or ordering physician, I see something but fail to appreciate the significance, or perhaps fail to learn something about the patient or their history that I should have learned by a more thorough reading of the medical record. This presentation will explore the underpinnings of my "greatest mistakes" as a cautionary tale to others.

Take Home Points:
- Learn your weaknesses and make them stronger.
- The more experience you have, the better your chances of avoiding errors.
- Experience only comes from making errors.

Keywords: Head and neck cancer imaging, Pitfalls and errors, Mistakes

SL 1.2.
What I missed and why

M.G. Mack; Munich/DE

Short Summary: This lecture will give you an overview of diagnosis which can be missed easily. The reason for missed diagnosis can be variable and include the following:
- The radiologists know only common disease
- Radiologists are only able to diagnose lesions, which they have seen before.
- Radiologist didn´t get the full clinical information
- Lack of time
- Radiologists can have the "hammer-and-nail" bias
- Radiologists want to save money by not doing an additional examination (e.g. with another modality)
- Radiologists have different skill levels

Take Home Points: To learn strategies to avoid mistakes

Keywords: Head and Neck, CT and MR imaging, Mistakes

SL 1.3.
What I misinterpreted and why

R. Kohler; Sion/CH

Short Summary: Cognitive errors (to be distinguished from perceptual errors) represent findings that are seen by the radiologist but their meaning and significance is incorrectly interpreted, thus leading to wrong conclusions as well as false positive diagnoses.

In the first part of this lecture we will discuss some typical situations leading to cognitive errors that are divided in three categories: 1) related to the radiologist (degree of specialization, lack of knowledge, faulty synthesis, faulty data gathering, poor clinical information, poor conditions of interpretation), 2) related to an improper technique including artifacts and 3) related to the patient or the pathology (anatomical variant, systemic disease, unusual presentation, post therapeutic modifications).

Therefore, the only way to obtain the most accurate radiological diagnoses as possible is that the radiologist is aware of all factors that may influence negatively is way of thinking. The second part of the lecture will discuss the cognitive dispositions that may lead to diagnostic errors as well as propose some cognitive strategies and tips to reduce the diagnostic errors.

Take Home Points:

- Cognitive errors lead to wrong conclusions and false positive radiological interpretations.
- The causes of misinterpretations are multifactorial and either internal or external to the radiologist.
- Only awareness of the mechanisms of misinterpretations may contribute to better radiological diagnoses.

Keywords: Radiology practice, Misinterpretation, Cognitive errors

SL 1.4.
How to deal with mistakes

S. Golding; Oxford/UK

Short Summary: The radiologist's best defence against errors of practice is to be well informed and to practice conscientiously. Prevention is better than cure and good practice is underpinned by insisting on accurate referral information and by interviewing the patient if possible. However in spite of these moves it is a fact of radiological practice that even the best radiologist will at times make errors of diagnosis or interpretation. This presentation addresses the issues that arise when errors occur, as follows:

1. How significant is an individual error? How can we allow for justifiable differences of opinion?
2. How best can departments conduct clinical quality assurance to demonstrate their service standards?
3. How best can the individual radiologist monitor their performance and demonstrate their competence?
4. Is there a case for dual reporting of examinations?

5. What action should be taken if a colleague is found to have made an error?
6. How should consistently poor performance be managed?
7. How should detected errors be documented and acted upon? Is there always a responsibility of disclosure? Where does responsibility for this reside?
8. What responsibility has the radiologist to sure that the clinician acts appropriately on their report?
9. When patients take legal action for alleged negligence, how can the responsibilities of the radiologist best be met?

Take Home Points:
- All radiologists make mistakes.
- Not all mistakes are clinical relevant.
- Departments that conduct clinical audit protect their standard of care.
- Individual radiologists need to monitor their work.
- When errors are detected clinical action may be needed.
- Definite mistakes are best managed openly and honestly.

Keywords: Errors, Competence, Clinical audit, Negligence

RC 5
Imaging of the parapharyngeal space

B.S. Purohit; Singapore/SG

Short Summary: The parapharyngeal space (PPS) is a central fat-filled space in the deep face, extending from the skull base to the level of the hyoid. Since it largely contains fat, it is always well visualised on CT and MR imaging of the head and neck. The PPS is bordered by the pharyngeal mucosal space medially, masticator space laterally, parotid space posterolaterally, and the retropharyngeal space posteromedially. The clinician's PPS is further subdivided into the prestyloid and retrostyloid compartments.

While primary tumours of the PPS are rare, secondary displacement or infiltration of this space, by pathology arising in neighbouring spaces, is more common. The displacement pattern of PPS fat allows the radiologist to use a logical algorithm to identify the true space of origin of tumours in this region. Tumours arising from the deep parotid lobe are the most common lesions seen in the prestyloid PPS. Neurogenic tumours and paragangliomas are the commonest primary lesions of the retrostyloid PPS. Primary prestyloid PPS lesions are rare, however, lipomas, atypical second branchial cleft cysts and ectopic salivary gland tumours may be seen.

This talk aims to highlight:
- The imaging anatomy of the PPS
- The displacement patterns of PPS fat on CT and MRI that guide imaging diagnosis
- Radiological features of PPS lesions and the complimentary role of various imaging modalities
- Imaging checklist for reporting a PPS lesion and its impact on treatment

Take Home Points:

- A clear understanding of the spatial anatomy of the PPS is crucial for an accurate diagnostic approach towards PPS pathology.
- Masses arising from adjacent spaces displace PPS fat in a particular way; in combination with their imaging characteristics, this information narrows down the list of differential diagnoses.
- Prestyloid PPS lesions include deep parotid lobe tumours, ectopic salivary gland tumours, lipomas and atypical second branchial cleft cysts. Neurogenic tumours and paragangliomas are common retrostyloid PPS lesions.
- CT/MRI can diagnose common PPS lesions with typical features. Histopathology is required for suspected malignancy.
- Radiological report for a PPS mass should mention size, compartmental location, skull base involvement, any features suggestive of malignancy and relation to the carotid arteries in cases of paragangliomas.

Keywords: PPS anatomy, Deep parotid tumours, Neurogenic tumours, Paragangliomas, PPS fat displacement, Multimodality imaging

RC 6
Pitfalls in head and neck imaging

J. Olliff; Birmingham/UK

Short Summary:

This talk will cover:

Technique related problems which lead to a scan being difficult or misinterpreted.

The ideal scan will be tailored to answer the clinical question. CT scans should be performed with IV contrast. The patient should not swallow during the scan and should breathe gently during the acquisition of images. The choice of MR sequence and imaging plane is important. Intravenous gadolinium is necessary particularly if there is potential peri-neural spread of disease. Artefacts from flow and metal clips etc need to be recognised and minimised.

How benign disease can mimic malignancy.

Some benign diseases can mimic malignancy and correlation with good clinical information and histology is important.

Post treatment changes which can make a scan “difficult” to interpret.

Post treatment changes (biopsy, radiotherapy and surgery) often increase the complexity

Take Home Points:

- The correct interpretation of imaging of the head and neck depends on: Obtaining the optimum scan
- Good communication between the clinician and the radiologist
- In depth knowledge of anatomy, disease processes and their imaging appearance and detailed knowledge of post treatment changes

Keywords: Scan technique, Post treatment changes, Mimics of malignant disease

RC 7
Imaging of the oropharynx

A. Trojanowska; Lublin/PL

Short Summary: The imaging findings in squamous cell carcinoma (SCC) of the oral cavity and oropharynx vary widely, depending on the site of origin of the primary tumor and the extent of its involvement of other regions. Knowledge of the complex anatomy of the oral cavity and oropharynx, as well as the most common routes by which SCC spreads from various anatomic sites, allows the radiologist to accurately determine the extent of disease and help clinicians plan appropriate treatment. SCCs that originate in the oral cavity tend to behave differently than those that originate in the oropharynx, with the latter group exhibiting more aggressive growth. Furthermore, primary tumors in certain anatomic subsites within the oral cavity or oropharynx have a greater propensity to spread by direct extension along muscle, bone, or neurovascular bundles or to be disseminated along lymphatic drainage pathways to regional or distant nodes. Imaging findings of deep muscular, neurovascular, osseous, or nodal involvement are indicative of an advanced stage of disease for which management options are limited.

Take Home Points:
- imaging of the oropharynx requires, in majority of cases, the use of both imaging methods - MR and CT
- profound knowledge of anantomy is crucial
- special emphasis should be put on the evaluation of metastatic lymph nodes, infiltration of carotid space and possible perineural spread
- follow-up, especially after free flap reconstructions, is challenging; the same imaging method and detailed knowledge of previous studies are essential

Keywords: Radiotherapy, Oropharyngeal cancer, Computed tomography

SL 2.1.
The basics: Tumour cellularity, perfusion, hypoxia, necrosis, stromal burden, etc.. How signal changes on DCE, DWI, IVIM correlate with pathology?

S. Bisdas; London/UK

Short Summary: Anatomical imaging modalities excel at providing details on lesion location, size, morphology, and structural changes to adjacent tissues; however, these modalities provide little insight into tumor physiology. Physiologic or functional MRI techniques like dynamic contrast-enahnced (DCE) imaging, diffusion-weighted imaging (DWI) and intravoxel incoherent motion (IVIM) provide a range of functional information for the tumor and may be used for baseline and follow-up in head and neck cancer (HNC).

Angiogenesis in HNC is induced by secretion of vascular growth factors in reaction to the presence of local hypoxia or lack of nutrients. Resultant vascular changes can be studied well with DCE-MRI, where the dynamic uptake and rapid washout of the contrast agent shows the pharmacokinetics of cancerous tissue and the signal changes are strongly associated with the

perfusion, the tumor cellularity (in terms of extravascular extracellular space) and any necrosis in the tissue of interest.

In DWI, proton diffusion properties in water are used to produce image contrast. By applying motion-encoding gradients, which cause phase shifts in moving protons, depending on the vector of their movement, resulting in the attenuation of the MR signal. Using appropriate equations, the movement of the water molecules within the interpulse time can be quantified (DWI). Because DWI quantifies the flow as well as the distance a water molecule has moved, it represents both capillary perfusion and diffusion characteristics (IVIM). Thus, the signal in DWI /IVIM is strongly dependent on capillary perfusion, tumour cellularity, and stromal burden.

The functional MR imaging techniques have their strengths and shortcomings, they are usually combined in a multiparametric MR imaging to increase accuracy. A multiparametric MRI HNC examination may also indirectly give information about the tumour hypoxia and thus it can be utilized for treatment planning and prognosis. State-of-the-art imaging protocols include DCE, DWI and IVIM enabling a comprehensive approach to tumor pathophysiology.

Take Home Points:

- DCE, DWI and IVIM MRI techniques provide significant insights into the tumour pathophysiology.
- DCE, DWI and IVIM MRI are inherently correlated with various histopathological tumour characteristics.
- Translation of the DCE, DWI and IVIM MRI results into clinical practice is beneficial for head and neck tumour imaging studies.

Keywords: Dynamic contrast-enhanced MRI, Diffusion-weighted MRI, Intravoxel incoherent motion, Head and neck tumours, Biomarkers, Tumour pathophysiology

SL 2.2.
The basics: Peritumoral edema, early & late post-treatment healing and fibrosis. Which validation for DCE, DWI, IVIM.

M. Ravanelli; Brescia/IT

Short Summary: Diffusion-weighted imaging (DWI) and dynamic contrast-enhanced imaging (DCE) are nowadays included in many MRI protocols for studying head and neck tumors and they are used as additional tools to the morphological imaging in order to improve tissue discrimination in staging before treatment and surveillance of treated cancer. In pre-treatment scenarios, DWI and DCE can improve tumor delineation by enhancing the contrast between tumor and peritumor inflammation. Furthermore, DWI plus T2 sequences allow scar and recurrence after treatment to be differentiated. However, even if daily practice shows the potential utility of these techniques, just few studies in literature aimed to validate an empirical approach are now available. This is mainly due to the lack of gold standards: in fact, histopathological correlation is impossible in non surgically treated patients and is anyway difficult to obtain and potentially affected by several biases even in surgical specimens. More have been written about the potential role in prediction and treatment monitoring, using outcome indicators based on survival. In this field, could play a role also intravoxel incoherent

motion (IVIM), a method for DWI signal analysis that is able to extract information about tissue diffusion and perfusion. This speech will focus on the current status of basic and clinical validation of DWI, DCE and IVIM and will try to highlight how these evidences should guide the interpretation of signal and parameters provided by DWI, DCE and IVIM. Finally, a rapid overview of the possible new scenarios in the field of radiomics will be made.

Take Home Points:

- DWI and DCE MRI can improve tissue discrimination of peritumoral edema, leading to a better tumor delineation and giving potentially important information on tumor biology.
- DWI and DCE MRI help the discrimination of post treatment changes from recurrences, relying on different water and cell content of scar, granulation tissue and tumor.
- Attention must be paid to the quantitative analysis of DWI and DCE MRI, because this may be affected by several variables.

Keywords: Diffusion-weighted imaging, Intravoxel incoherent motion, Dynamic contrast-enhanced MRI, peritumoral inflammation, Post treatment changes

SL 2.3.
The basics: Can PET solve all these issues?

S. Bisdas; London/UK

Short Summary: PET with FDG is frequently used for staging and re-staging of carcinomas of the head and neck region (HNC) as HNCs generally demonstrate intense tracer uptake. Nevertheless, several limitations of FDG-PET have also been identified. For selected tumors, the use of non-FDG tracers, such as 18F-choline for occult parathyroid adenoma or 68Ga-labeled somatostatin receptor peptides for neuroendocrine tumours, meningiomas, and granulomatous tumours. Other tracers targeting amino acid transport, thymidine metabolism, hypoxia (potentially improving the efficacy of radiotherapy), tumour angiogenesis (including monitoring of anti-angiogenic therapies), and antigen expression have been developed and tested in preclinical, as well as in initial clinical studies, without being likely to replace FDG-PET for staging and re-staging of HNCs, since their sensitivity for tumour detection appears limited. Furthermore, noninvasive imaging of apoptosis that may potentially allow early monitoring of response to therapy may be also facilitated by PET using novel small-molecule probes designed to allow visualization of the unique complex of apoptosis-related cellular alterations. Finally, the discovery of critical tumour targets has boosted the design of targeted therapeutic agents with monoclonal antibodies and tyrosine kinase inhibitors (TKIs). Immuno-PET and TKI-PET, are also exciting novel options for better understanding of the in vivo behaviour and efficacy of these targeted drugs in individual patients and for more efficient drug development. All these promising new applications of PET do, however, require more systematic clinical studies before they can be used for patient management. Moreover, the inherent disadvantage of the low resolution of PET may not capture the lesion heterogeneity and thus unveil the pathophysiology in its full extend.

Take Home Points:

- FDG-PET is well recognized for detecting tumor and nodal involvement, for exclusion of distant metastases, synchronous primary tumours, as well as tumour surveillance.
- Biology-based objective functions, including hypoxia, angiogenesis, antigen expression and apoptosis, can be elucidated by using various PET-tracers.
- Integration of molecular imaging PET techniques into therapy selection strategies and radiation treatment planning is still under investigation.
- Limited spatial resolution, partial volume effects, and limited availability of tracers other than FDG are general shortcomings of PET imaging in head and neck cancer.

Keywords: PET, Tumour pathophysiology, Hypoxia, Angiogenesis, Molecular imaging, Tumour proliferation

SL 2.4.
Which Functional Imaging parameters should we focus on for response prediction? – What we know from current studies on DCE/DWI & IVIM

A. King; Hong Kong/HK

Short Summary:

What we know from current studies on DCE/DWI & IVIM

The head and neck remains a technically challenging region in which to acquire functional MRI data and maps. Standardisation of imaging protocols and functional map analysis across centers is problematic and there are an ever increasing number of functional parameters reported in the literature. Furthermore a wide range of different outcome measures are used to correlate this functional data with treatment response, and post-treatment follow-up time periods are often limited. However, functional MRI is still a promising tool for head and neck cancer evaluation.

Pre-treatment prediction of response. Tumour hypoxia, reduced perfusion and a high stromal content decrease the delivery of oxygen and/or cytotoxic drugs so rendering the tumour more resistant to chemoradiotherapy. Patients with squamous cell carcinoma have poorer outcomes when the pre-treatment tumours have high ADC values on DWI (believed to reflect hypoxia and high stromal content). ADC means or D values (IVIM) calculated from higher b values (~300 -1000 s/mm2) to avoid the influence of perfusion, may improve the predictive ability of DWI. Using DCE a lower Ktrans and extravascular extracellular space (Ve) also has been linked with a poorer outcome.

Intra-treatment response monitoring. In the first few days tumours may show a transient decrease in ADC (cell swelling), but thereafter tumours are expected to show a progressive increase in ADC over the course of treatment as cells die. About two weeks after the start of treatment differences can already be found between non-responders and responders using DWI, non-responders showing a significantly lower rise in ADC. A fall in ADC at this time point or later in treatment after an initial rise, believed to represent a repopulation of tumour cells, has also been linked with an unfavourable response.

Take Home Points:
- Functional MRI remains a challenging technique in the head and neck.
- Patients with tumours that have a pre-treatment high ADC and early intra-treatment low percentage rise in ADC are more likely to fail treatment.
- Patients with tumours that have pre-treatment low Ktrans may be more likely to fail treatment.

Keywords: DWI, DCE, Cancer, Treatment response, Prediction

SL 2.5.
Which Functional Imaging parameters should we focus on for response prediction? – Multiparametric analysis: an useful insight into tumour properties?

J.W. Casselman; Bruges/BE

Short Summary: Before the advent of the imaging biomarkers the potential response to therapy depended on the staging and especially the biospy findings - histologic characteristics of the tumor. Today imaging biomarkers like perfusion (CT/MR) and diffussion (IVIM - D diffussion) and permeablity (Ktrans, AUC 90, Ve, etc.) on MR provide more information about the tumor. PET-CT and diffussion are the biomarkers which were first used to monitor response and to detect recurrent disease. However, predicition of tumor response was not possible. With the advent of perfusion/permeability MR and commercially available software to calculate the permeablity it became possible to predict the response of the tumor to chemoradiotherapy. The best know permeability parameter is “Ktrans” or capillary permeability or flux rate constant between the vascular space and extravascular extracelluar space. This is probably not the most stable parameter to measure the permeability but today most of the available studies used this parameter. A steeper permeability curve corresponds with very vascularized tumors which are less hypoxic and necrotic and therefore the therapy can better reach all parts of the tumor and will result in a better response. For head and neck squamous cell carcinomas a Ktrans of < 0.45 min-1 corresponds with a bad response to chemoradiotherapy while a Ktrans of > 0.45 min-1 corresponds with a good response (Shu-Hang Ng et al. 2013, Kim et al. 2010). The authors concluded that Ktrans was a significant predictor of local failure with chemoradiation implying that tumor vascularity and permeability are more predictive of local control than tumor cellularity, metabolism, volume and T-stage. More studies and larger studies are needed to confirm and fine tune these findings. Moreover, the values have to be confirmed/set for different tumor types and for radiotherapy and chemotherapy alone. The above will be discussed and illustrated in this presentation.

Take Home Points:
- Learn which parameters were previously used to perdict tumor response
- Know the imaging techniques which today can be used to acquire the biomarkers which can predict therapy response
- Know the most frequently used permeability biomarkers and understand why they can predict therapy response
- Understand today's limitations and pitfalls of this technique

Keywords: Head and neck, Tumors, Tumor biomarkers, Magnetic Resonance Imaging, Permeability

SS 11.1.
Diagnostic approach of large salivary gland nodules

C. Czerny; Vienna/AT

Short Summary: The salivary glands are separated into large salivary glands and small salivary glands. The large salivary glands are paired and consist of the parotid glands, the submandibular glands, and the sublingual glands.
The imaging of pathologies is performed by ultrasound, CT, MRI, PET-CT, and PET-MRI.
Nodular pathologies are very common beside other pathologies such as e.g. inflammations or stones affecting the salivary glands.
Nodules can be benign or malignant, and as larger the gland as more common are the benign nodules.
In this lecture, the imaging characteristics of nodules of the large salivary glands will be described according to the different imaging modalities.

Localisation	Incidence	Benign	Malignant
Parotis	75%	80%	20%
Submandibularis	15%	50%	50%
Small salivary glands	9%	40%	60%

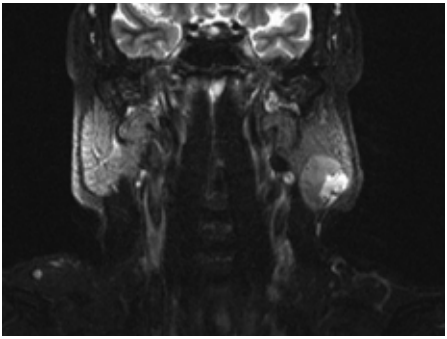

Figure 1: STIR image of pleomorphic adenoma

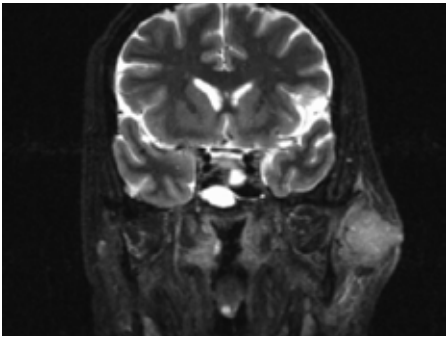

Figure 2: STIR image of carcinoma

Take Home Points:
- Anatomic structures involved
- Imaging modalities
- Imaging characteristics of tumors

Keywords: Salivary glands, Tumors, Imaging

SS 11.2.
Ultrasound of the face and neck

S. Robinson; Vienna/AT

Short Summary: Well-known advantages of ultrasound are that it is easily available and accessible, cost effective, non-invasive and does not expose the patient to radiation. The radiologist can palpate lesions and get the patient's clinical history unfiltered. Unlike for other imaging modalities, once the patient has left the department, one cannot discuss the study with other colleagues as easily. Therefore, making the most of the ultrasound examination is mandatory. Not only knowledge of the patient's symptoms and the referring doctor's suspicion, but also awareness of potentially coexisting other conditions or illnesses and previous surgical interventions or relevant medications is required. Precise familiarity with head and neck anatomy and normal variants helps excluding or localizing pathology. Technical considerations and common pitfalls have to be taken into account. In case of a mass, echogenicity, homogeneity, vascularization, borders, change of size with compression, mobility with swallowing, centre of origin and relationship to adjacent structures, especially vessels and bone should be assessed. Involvement of several compartments or lymph nodes will be investigated. Potential crossing of the midline has to be excluded. If previous investigations are available, a comparison will be part of the report. Taking the referring doctor's responsibility and experience into account, further or follow-up tests will be recommended. Typical examples of ultrasound anatomy and pathology will be discussed.

Take Home Points:
- Precise knowledge of anatomy, embryological development and typical pathology is required

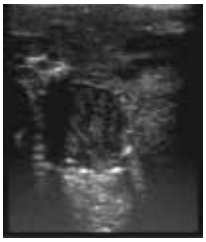

Figure 1: 18-year-old male patient with age-related hypertrophy of lymphatic tissue at the base of the tongue; finding is symmetric and morphology shows typical crypts

Figure 2: 68-year-old male patient with exulcerated squamous cell carcinoma at the base of the tongue with heterogenous structure and infiltration of the posterior third of the floor of the mouth

- Familiarity with ultrasound technique, pitfalls and the machine helps to optimize the examination quality.
- Pulling together information from patient, referring doctor, previous investigations and ultrasound examination enables to establish a working hypothesis and recommend further steps.

Keywords: Ultrasound, Neck anatomy, Neck embryology, Pathology

SS 11.3.
Small and accessory salivary glands pathologies

A. Borges; Lisbon/PT

Short Summary: Salivary gland tissue includes, besides 3 paired major salivary glands, uncountable minor salivary glands spread throughout the submucosa of the upper aero-digestive tract, accessory salivary glands and heterotopic salivary gland tissue. It is important to be aware of these different types of salivary tissue that is prone to the same pathologic processes affecting major salivary glands. Minor salivary glands are small aggregates of non-capsulated mucous or serous glands embedded in the submucosa, containing excretory ducts which open directly in the overlying mucosa. Accessory salivary glands are small aggregates of salivary tissue with their own ductal system, seen in a reasonable percentage of normal population, in expected locations, usually along the course of the main draining duct of the parent gland. Finally, salivary heterotopias consist of small inclusions of salivary tissue in non-expected locations, lacking a ductal system. This “misplaced” tissue, related to embryonic developmental abnormalities, is most often associated with intra and peri-parotid lymph nodes but has also been described in remote locations along the tract of the cervical sinus of His. Pathologic processes in this remote salivary tissue can be a diagnostic challenge in the head and neck. A pictorial review of benign and malignant pathology associated to accessory and minor salivary gland tissue will be presented with emphasis given to the role of imaging in the differential diagnosis and further patient’s management.

Take Home Points:
- Salivary tissue in the head and neck includes major and minor salivary glands, accessory salivary glands and heterotopic salivary tissue
- Remote salivary tissue shares the same pathologic processes with major salivary glands although with different relative frequencies and different clinical presentations
- Tumors of minor salivary tissue are most often malignant, present as submucosal masses and have high propensity for perineural spread
- The lacrimal gland is similar to the salivary glands, can be affected by the same pathologic processes and should not be forgotten when evaluating systemic exocrinopathies

Keywords: Minor salivary glands, Accessory salivary glands, Salivary tissue heterotopia, Salivary gland imaging, Salivary gland pathology, Minor salivary gland tumors

POSTERS

Educational Posters

EP-01 Deciphering the neck: A practical guide to diagnosing pathology based on anatomical location
A. Lukaszewicz, S.-K. Shields, G. Pappas; Pontiac/US

EP-02 Malignant melanoma secondary to Werner's Syndrome; an unusual case presenting as a nasal mass
J. Ferrier, E. Loney; Bradford/UK

EP-03 Imaging features in acute deep neck space sepsis
S.-J. Choi, S. Selvam, S. Vaidyanathan, S. Karthik; Leeds/UK

EP-04 Incidental detection of nasopharyngeal carcinoma
E. Ng, J.N. Shenoy, C. Zhao, A. Chawla; Singapore/SG

EP-05 The Many Faces of Ameloblastoma
A.W. Yong, T. Sudarshan, R. Oparka; Dundee/UK

EP-06 A pictorial review of head and neck schwannomas
B. Sharif[1], L. Ismail, R[1]. Vaidhyanath[2], R. Lingam[1]; [1]London/UK, [2]Leicester/UK

EP-07 A case review of a rare orbital lesion - cholesterol granuloma
S.S. Cheng, K.M. Chu, W.L. Poon, K.W. Tang; Hong Kong/HK

EP-08 Odontogenic and dental iatrogenic lesions in maxillary sinuses – a pictorial review
I. Rozylo-Kalinowska, T.K. Rozylo; Lublin/PL

EP-09 Framing a structured report. High-resolution computed tomography and cone beam computed tomography in pre-surgical imaging of paranasal sinuses and nasal cavity.
K. Markiet, K. Gwozdziewicz, B. Mikaszewski, E. Szurowska; Gdansk/PL

EP-10 Orbital implants and devices: an iconographic essay
D. Sumi, F.J. Muniz Neto, R.L.E. Gomes, M.R.T. Garcia, C.R. Soares, M.M. Daniel, M.B.G. Funari; Sao Paulo/BR

EP-11 It Isn't Always Salt-and-Pepper: A Review of Typical and Atypical Paragangliomas
M.C. Lim[1], J.P.N. Goh[1], S.C. Loke[1], A.A. Karandikar[1], W.R.K. Smoker[2], L.R. Gentry[3], D.L. Reede[4], T.Y. Tan[1]; [1]Singapore/SG, [2]Iowa City/US, [3]Madison/US, [4]New York/US

EP-12 When tumors go astray: perineural spread
J. Lieb, A. Hagenkord; Basel/CH

EP-13 Review of unilateral vocal cord paralysis: Anatomical considerations, pathologies and post-treatment imaging findings.
A. Hagenkord, J. Lieb; Basel/CH

EP-14 MRI funtional imaging of the upper thoracic outlet. A new approach to an old challenge.
J.P. Martínez Barbero, T. Martín Noguerol; Jaen/ES

EP-15 Anatomy and major pathological conditions of salivary glands based on CT and MR imaging
M. Nózka-Kozik, M. Członkowski, A. Trojanowska, A. Drop; Lublin/PL

EP-16 Functional imaging techniques in the characterization and monitoring of neoplastic lesions of the head and neck
J.P. Martínez Barbero[1], T. Martín Noguerol[1], M.D.M. Navarro-Pelayo Laínez[2]; [1]Jaen/ES, [2]Granada/ES

EP-17 Cranial nerves parasympathetic fibers and their anastomoses
M.L. Fernandes Pita, M. Lourenço, L. Caixeiro, A.G. Ferreira; Lisbon/PT

EP-18 Trans-sphenoidal encephalocele as an epipharyngeal mass: A case report
M. Gulbay, D. Ciliz, B. Sakman; Ankara/TR

EP-19 A Snapshot of Vocal Cord Paralysis: Where to Look For? Test Yourself.
M.L. Fernandes Pita, J. Fonseca, C. Relvas, A.G. Ferreira; Lisbon/PT

EP-20 Evaluation of temporal bone CT scans in patients with conductive hearing loss and intact tympanic membrane.
M. Członkowski, M. Nózka-Kozik, A. Trojanowska, A. Drop; Lublin/PL

EP-21 A case of isolated larynx involvement in IgG4-related systemic disease.
E. Stepanova, M. Vishniakova, D. Mustafaev; Moscow/RU

EP-22 Malformations of the Jugular Bulbus at Multislice High Resolution Computed Tomography
A. Semiz Oysu, I. Deveci, Y. Bukte, Z. Sakci, F. Kulali; Istanbul/TR

EP-23 Imaging of the head and neck implants
A. Semiz Oysu, A. Macin, I. Deveci; Istanbul/TR

EP-24 Artifacts in cone beam computed tomography
E. Bozdemir, D. Yildirim, A. Aydogmus Erik; Isparta/TR

EP-25 Mandibular accessory foramina and canals: cone-beam computed tomography findings
U. Aydin[1], D. Yildirim[2], A.S. Horasan[3]; [1]Ankara/TR, [2]Isparta/TR, [3]Istanbul/TR

EP-26 Juvenile Nasopharyngeal Angiofibroma: Relevant CT and MRI anatomy with pathways of spread of the tumour.
R. Hegde, A. Joshi, A. Sankhe, D. Sharma, K. Kale; Mumbai/IN

EP-27 CT Angiographic Demonstration of Bilateral Asymmetrical Duplication of the Vertebral Artery
G. Ozer, L. Pasaoglu, U. Toprak; Ankara/TR

EP-28 Cavernous sinus – A Radiologist's cavern
A. Kulkarni, C. Trivedi, B. Purohit, W.-Y. Yu; Singapore/SG

EP-29 Radiation-induced Osteosarcoma of the Maxilla and Oropharyngeal Squamous Cell Cancer
L. Pasaoglu, D. Mamedova, U. Toprak, H.G. Hatipoglu, G. Ozer; Ankara/TR

EP-30 Postoperative CT and MR imaging of pharyngolaryngeal cancer
A. Baba[1], H. Ojiri[2], N. Ogino[2], H. Yamauchi[2], T. Mogami[1], Y. Kobashi[1], S. Yamazoe[1], Y. Nozawa[1], Y. Aoyagi[1]; [1]Chiba/JP, [2]Tokyo/JP

EP-31 Pictorial review of trauma of the petrous temporal bones
A. Naseer, O. Francies, R. Akhtar, A. Adams, A. Roy; London/UK

Scientific Posters

SP-01 Benign mesenchymal sinonasal masses: Our experience and review of the literature
F. Wagner, L. Bitterli, M. Buchwalder, M.D. Caversaccio; Bern/CH

SP-02 Partial Volume Correction of Image-Derived Arterial Input Function: Application on Dynamic FDG PET of Nasopharyngeal Carcinoma
C.H. Thng[1], P.S. Lee[1], T.S. Koh[1], B. Huang[2], T.P. Hennedige[1], Y.F. Fan[1], B.K.J. Khoo[1], P.-L. Khong[3]; [1]Singapore/SG, [2]Shenzhen/CN, [3]Hong Kong/HK

SP-03 CT imaging criteria in the prediction of extracapsular spread of lymph node metastases in squamous cell carcinoma of the oral cavity
A. Burguete Moriones, A. Azagra de Miguel; Pamplona/ES

SP-04 Quantitative analysis of artifacts produced by standard prosthetic inlays in CBCT depending on software version
I. Rozylo-Kalinowska; Lublin/PL

SP-05 Degree of pneumatization of the mastoid air cell system in the perinatal period
D. Sumi, A.G.S. Anton, R.L.E. Gomes, M.R.T. Garcia, C.R. Soares, M.M. Daniel, M.B.G. Funari; Sao Paulo/BR

SP-06 Anatomical variations in paranasal sinuses and nasal cavity in CBCT in Polish population
K. Orhan[1], K. Gruszka[2], I. Rozylo-Kalinowska[2], P. Kalinowski[2], S. Aksoy[3]; [1]Ankara/TR, [2]Lublin/PL, [3]Mersin/TR

SP-07 HPV and oropharyngeal cancer, imaging characteristics
A. Azagra de Miguel, A. Burguete Moriones, Y. Ruiz de Azua Ciria; Pamplona/ES

SP-08 Neoplasias in the head and neck region mimicking Temporomandibular Joint symptoms
K. Orhan; Ankara/TR

SP-09 Clinical Usefulness of Metal Artifact Reduction Technology in CT Scanning of the Head and Neck
S. Yoshioka, E. Inuzuka, N. Fujii, K. Naito; Toyoake Aichi/JP

SP-10 Using non-echoplanar DWI in monitoring treatment response in active Graves Orbitopathy: Correlation between ADC values and STIR signal intensity ratios
R. Lingam, P. Mundada, V. lee; London/UK

SP-11 Cuantitative study of the lymphatic structures of Waldeyer's ring and cervical lymphadenopathies in children with Diffusion and ADC
J.P. Martínez Barbero; Jaen/ES

SP-12 Feasibility study of texture analysis using ultrasound shear wave elastography to predict malignancy in thyroid nodules
K. Bhatia, A. Ahuja, A.C.L. Lam; Shatin/HK

SP-13 Incidental findings on panoramic radiographs:one case report
T. Çimen, F. Yasar, H. Demir; Konya/TR

SP-14 Case report: Radicular cyst
B. Cetin, F. Akgunlu, E. Demir; Konya/TR

SP-15 Aggressive olfactory neuroblastoma invading the oral cavity: A Rare Case Report
U. Seki, K. Orhan, G. Kösten; Ankara/TR

SP-16 Idiopathic Orbital Inflammatory Syndrome Mimicking Orbital Cellulitis
I. Deveci, A. Semiz Oysu, M. Surmeli, E. Kardes, G. Kiray, A. Sahin Yilmaz; Istanbul/TR

SP-17 Appearance of middle ear cholesteatoma on different MR sequences - value of non-EPI DWI.
A. Zimny, A. Piekarek, T. Zatonski, A. Wabik, B. Hendrich, M. Sasiadek; Wroclaw/PL

SP-18 Primitive neuroectodermal tumor of the maxilla: a case report and literature review
E. Bozdemir, E. Bilgir, Y. Fındık, M.A. Aydın; Isparta/TR

SP-19 Potential of dose optimization of different kernels in imaging of paranasal sinuses
C. Güldner, K. Hofmann, I. Diogo, J. Werner; Marburg/DE

SP-20 3D FLAIR MR Imaging Applied for Diseases of the Temporal Bone and Peripheral Nerves of the Extracranial Head and Neck
G.M. Park, H.-J. Kim, Y.K. Kim, J. Cha, S.T. Kim; Seoul/KR

SP-21 Application of Cone Beam Computed Tomography for Assessment of the Coronoid Process Hyperplasia
O. Gormez, U. Alkis, Y. Findik, T. Baykul, M. Basaran; Isparta/TR

SP-22 Fractures of the temporal bone : an easier way to read your CT
A. Venkatasamy[1], F. Veillon[1], S. Riehm[1], P. Meriot[2], P. Baur[1], A. Charpiot[1]; [1]Strasbourg/FR, [2]Brest/FR

SP-23 Bilateral Anterior Stafne Bone Cavity (SBC): A Rarely Occuring Case Report
N. Yetimoglu Ozdil, H. Kurt, C.S. Paksoy, K. Orhan; Ankara/TR

SP-24 Are contouring time and multimodality imaging prognostic factors for radiation therapy of advanced head and neck cancer?
Y. Eller[1], N.D. Klass[1], M. Schmückin[1,2], O. Eliçin[1], R. Bigler[1], J. Tille[1], S. Fankhauser[1], N. Mertineit[1], B. Klaeser[1], A. Geretschläger[1,3]; [1]Bern/CH, [2]Hamburg/DE, [3]Basel/CH

Poster titles appear as submitted to the electronic poster submission system and have not been checked for correctness and completeness.

NOTES

POTENTIAL CONFLICT OF INTEREST DISCLOSURES

It is the policy of the European Society of Head and Neck Radiology to ensure balance, independence, objectivity, and scientific rigour in the congress programme. Knowledge of possible relationships with sponsors of any kind is mandatory in order to reinforce the educational and scientific message and to relieve any suspicion of bias.

Any potential conflict of interest involving ESHNR speakers should be made known so that the audience may form their own judgements about the presentation with a full disclosure of the facts.

It is for the audience to determine whether the presenter's external interest may reflect a possible bias in either the work carried out or the conclusions presented.

The individual listed below disclosed the following relationships:

J.W. Casselman:	Receipt of honoraria/consultation fees: Philips Healthcare Participation in a company sponsored speakers bureau: Oleasphere

Subject to changes, printing and typesetting errors.

eshnr

european society of
head and neck radiology

ESHNR 2016

29th Annual Meeting and Refresher Course

September 22–24, 2016
Leiden/NL

www.eshnr.eu

eshnr

european society of
head and neck radiology

European Society of Head and Neck Radiology
Neutorgasse 9/2 | 1010 Vienna | Austria
phone +43 1 5322191
fax +43 1 5322191 445 | ZVR 421925549
office@eshnr.eu | www.eshnr.eu