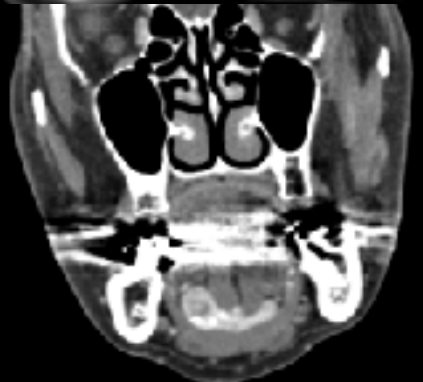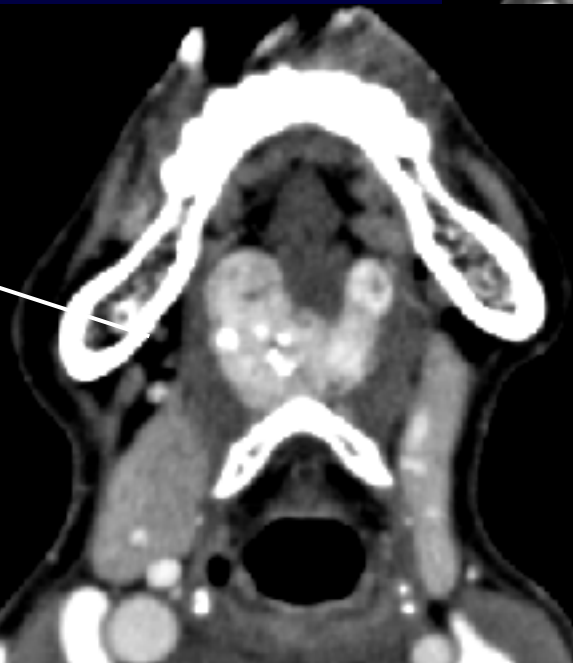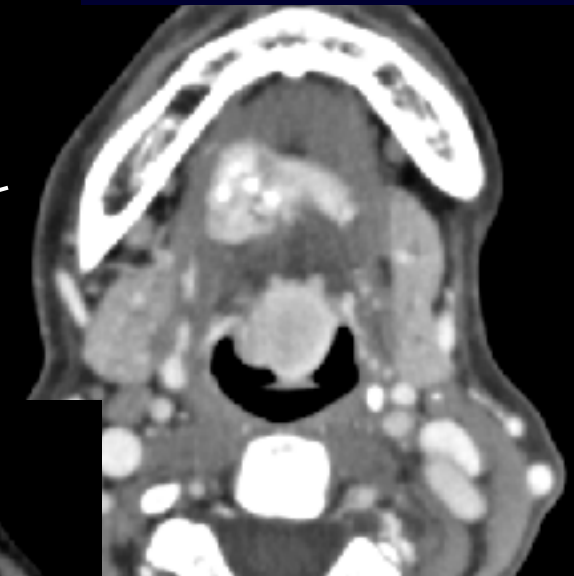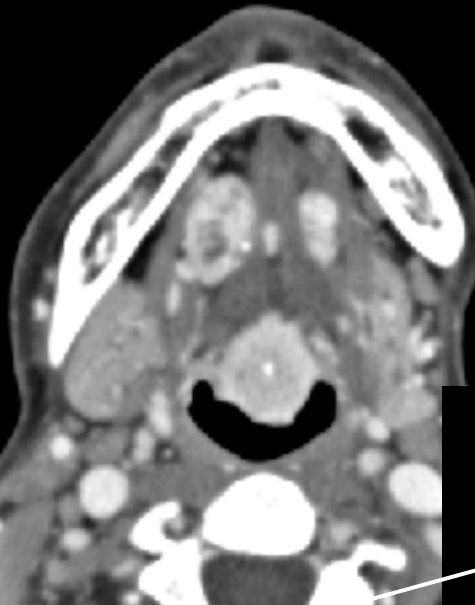
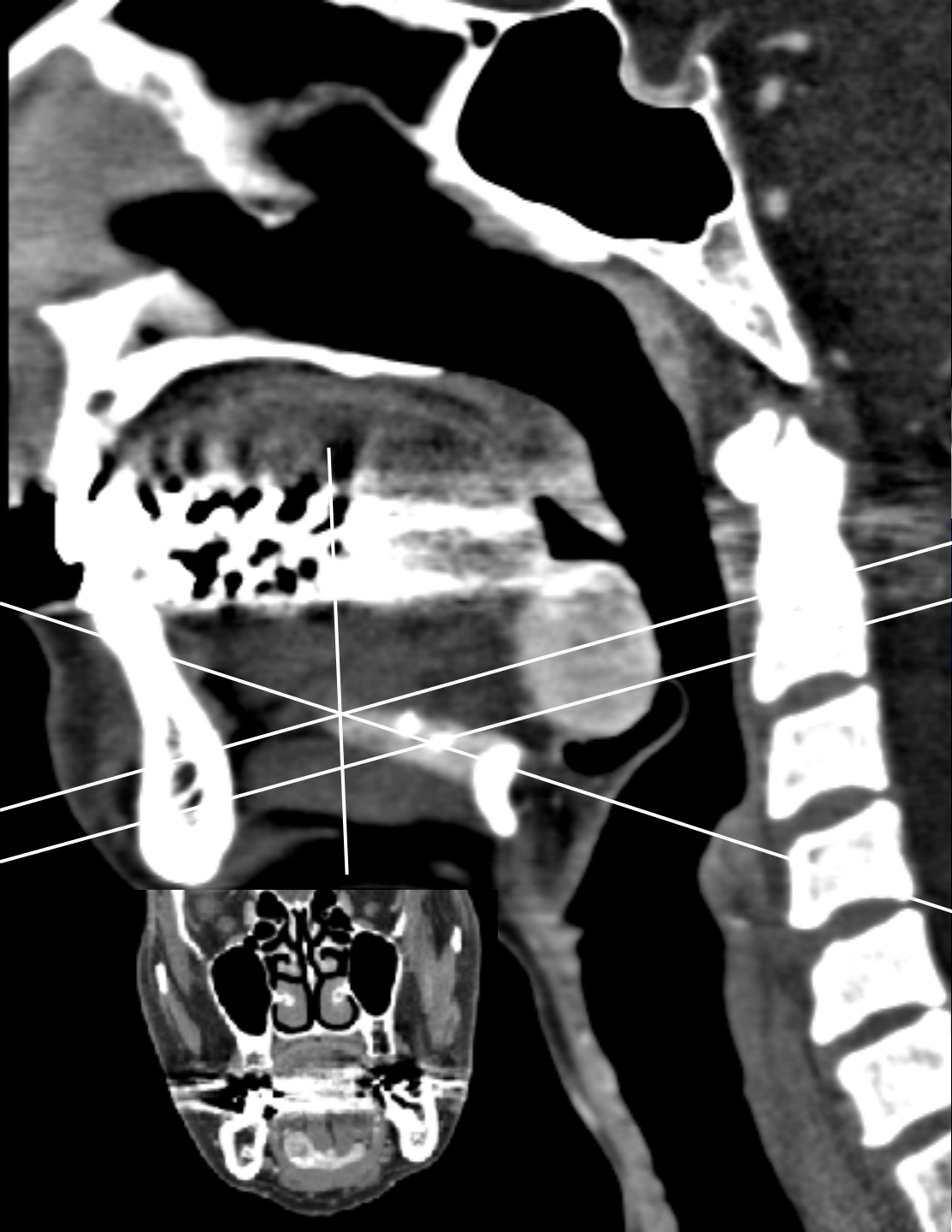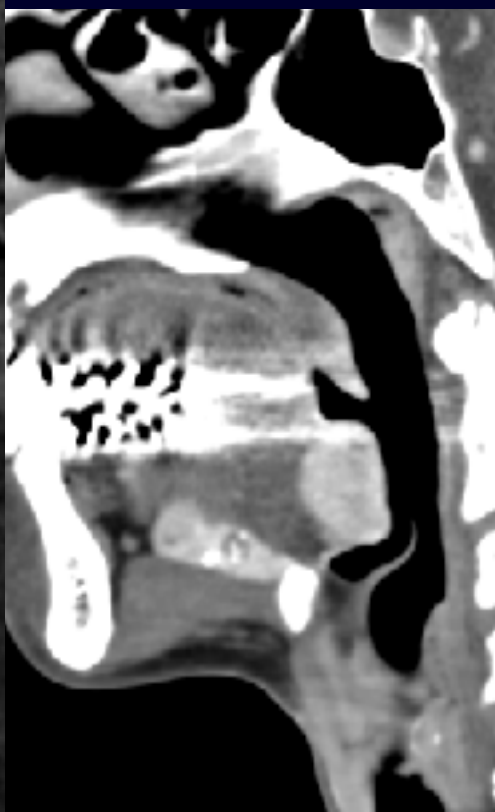
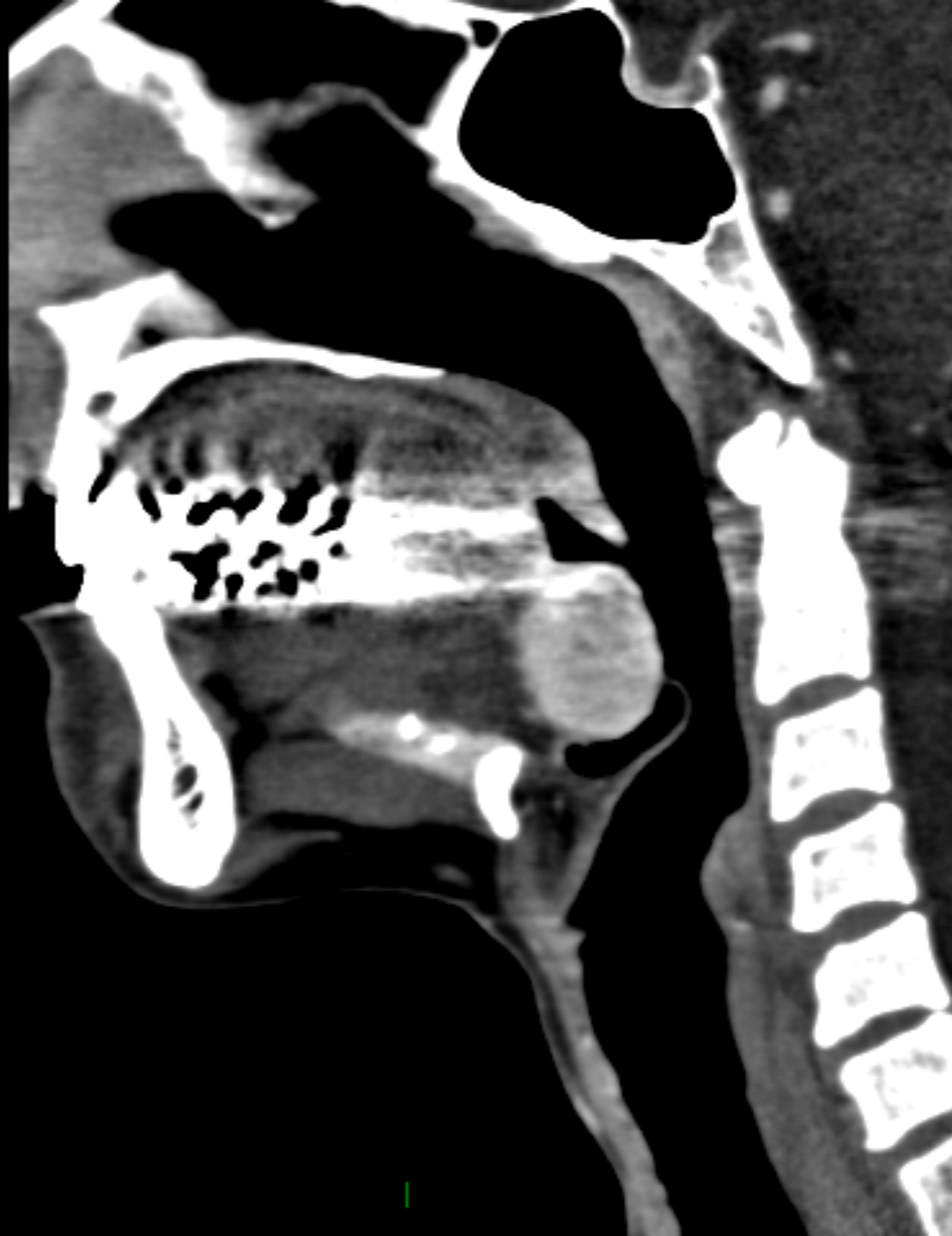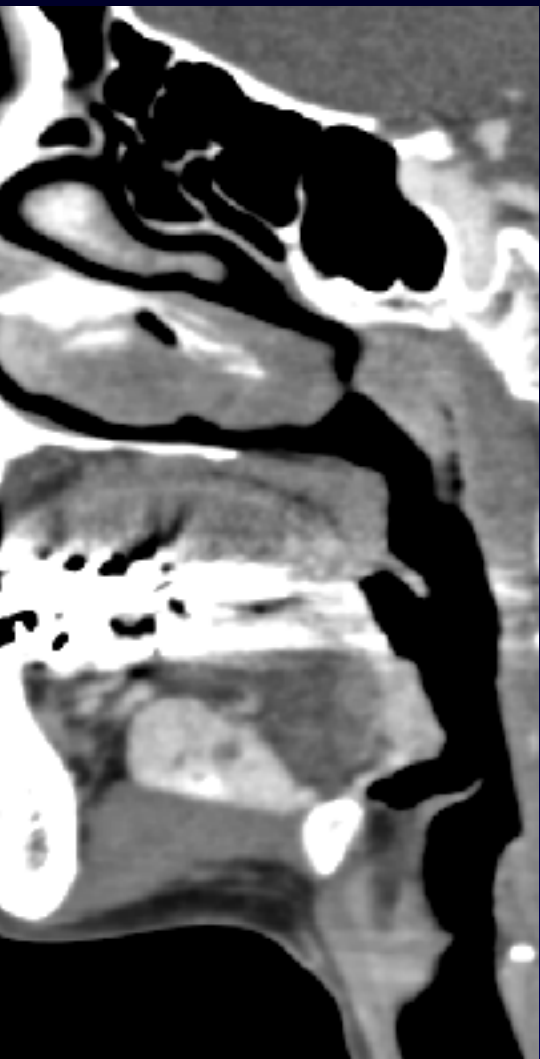
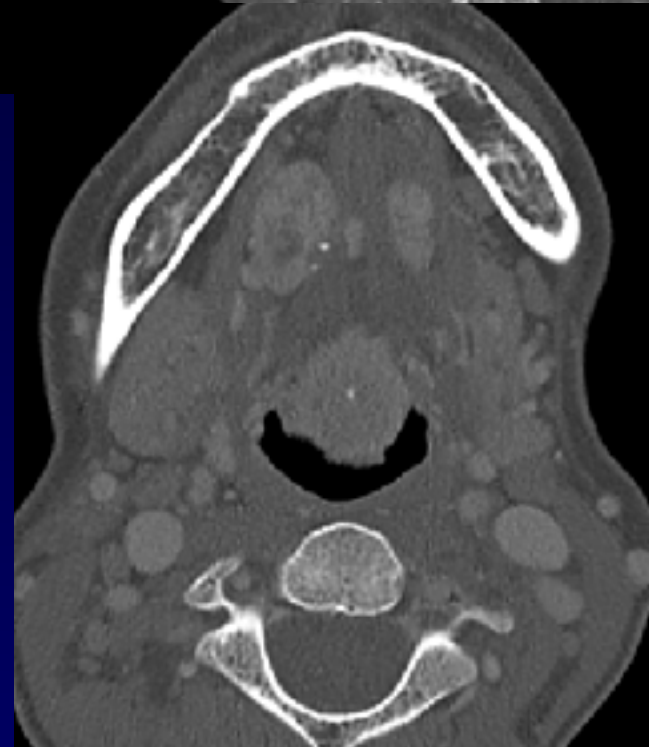
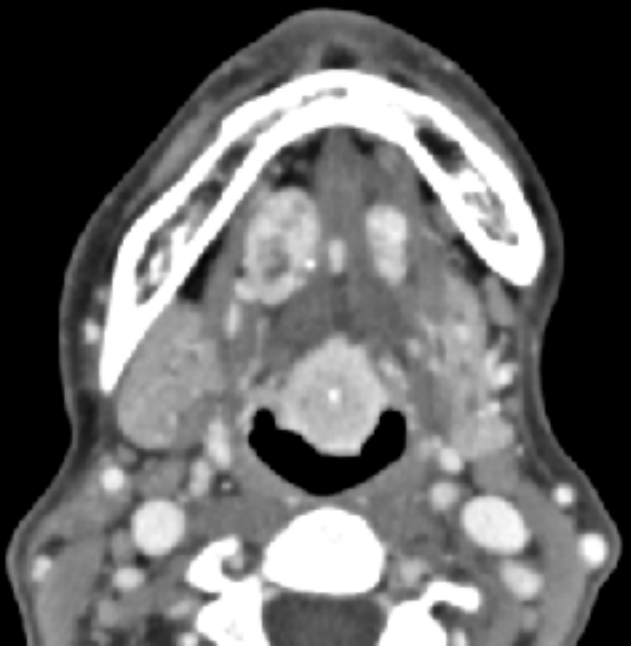
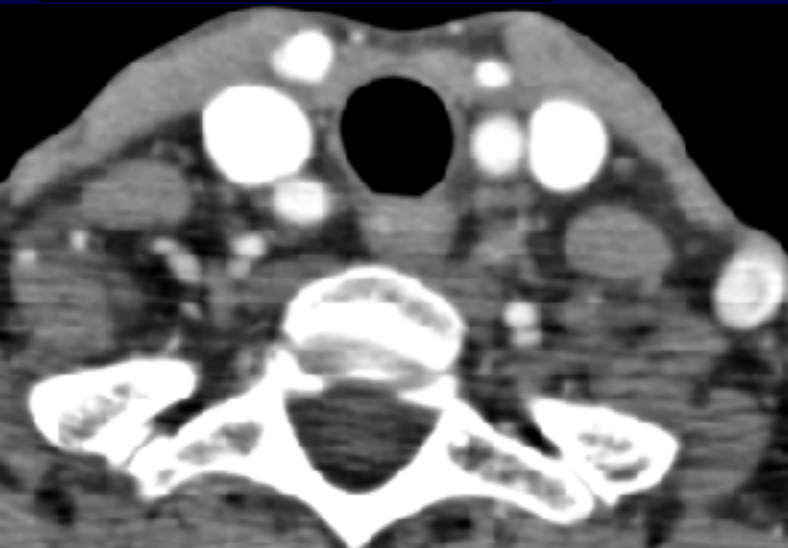
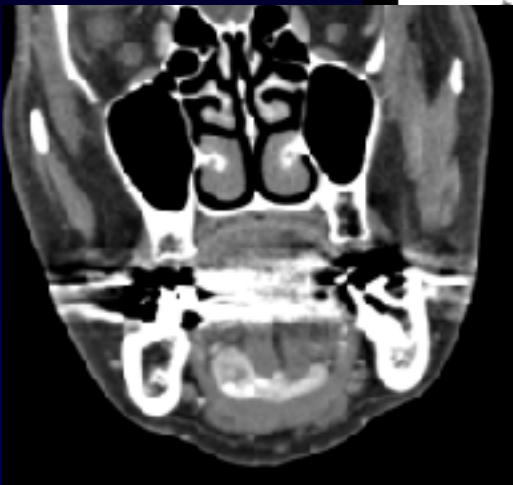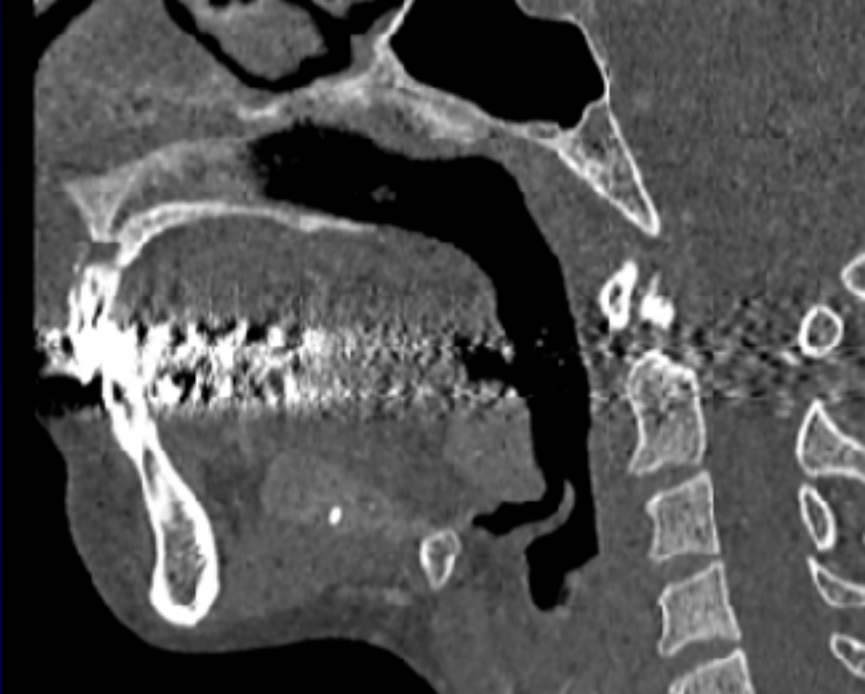
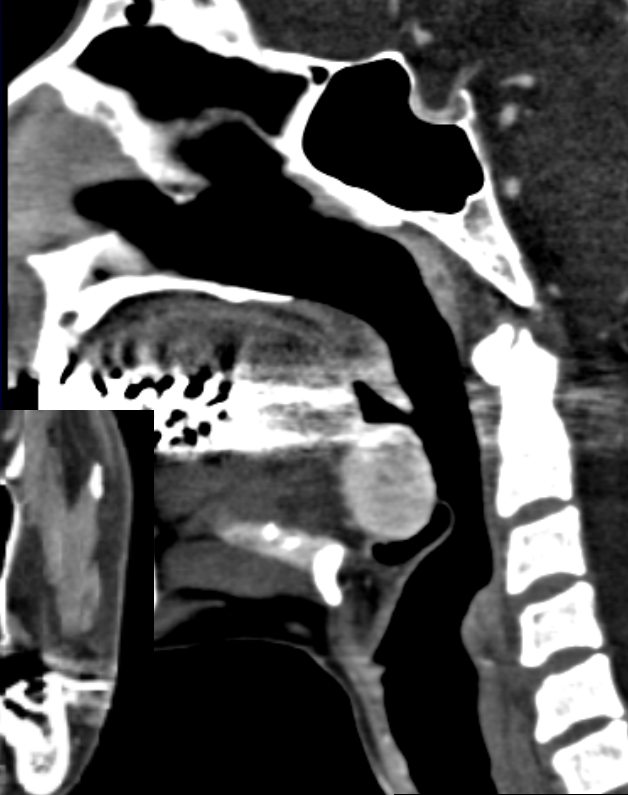


Gêne pharyngée à la déglutition:

Masse basilinguale







HYPOTHESE(s)

Que proposez vous ?